



RESEARCH ARTICLE  
DOI: 10.47750/jptcp.2022.912

## Diagnostic role of dynamic contrast-enhanced magnetic resonance imaging in differentiating breast lesions

Hussein Abed Dakhil<sup>1,2\*</sup>, Ahmed Mohamedbaqer Easa<sup>1,2</sup>, Ammar Yaser Hussein<sup>3</sup>, Raad Ajeel Bustan<sup>1,2</sup>, Hayder Suhail Najm<sup>1,2</sup>

<sup>1</sup>Department of Technology of Radiology and Radiotherapy, Tehran University of Medical Sciences, International Campus, Tehran, Iran

<sup>2</sup>Department of Radiological, Collage of Health & Medical Technology, Al-Ayen University, Thi-Qar, Iraq

<sup>3</sup>Medical Imaging Department, Al-Haboubi Teaching Hospital, Dhi Qar Health Department, Ministry of Health

\*Corresponding author: Hussein Abed Dakhil, Department of Technology of Radiology and Radiotherapy, Tehran University of Medical Sciences, International Campus, Tehran, Iran. Email: [hussaien.abed@gmail.com](mailto:hussaien.abed@gmail.com)

Submitted: 25 February 2022; Accepted: 3 April 2022; Published: 25 June 2022

---

### ABSTRACT

**Objective:** This study aimed to assess the diagnostic role of perfusion weighted image (DCE-PWI) to differentiate benign from malignant breast lesions.

**Patients and Methods:** The study comprised 32 women who had mammography and/or breast ultrasonography findings that were clinically questionable. All patients were fasting during the magnetic resonance imaging (MRI) test to avoid nausea or dynamic contrast-enhanced vomiting from the contrast medium.

**Result:** In this study, we observed the form of the dynamic curve (time and signal intensity curve) type I (persistent curve) was noted in 12 lesions (37.5%): 10 lesions were benign and two lesions were malignant; type II (plateau curve) was noted in eight lesions (25%): three lesions were benign and five lesions were malignant, and type III (washout curve) noted in 12 lesions (37.5%): one lesion was benign and 11 lesions were malignant.

**Conclusions:** The dynamic contrast-enhanced (DCE) magnetic resonance imaging (MRI) perfusion technique plays an important role in differentiating benign and malignant tumors in breast cancer.

**Keywords:** *benign and malignant; breast cancer; DCE; differentiation; MRI*

## INTRODUCTION

Breast cancer is becoming a second major source of illness and death around the world. Furthermore, for researchers, the rising rate of breast cancer remains a key source of concern. Increased public awareness leads to more recurrent medical exams and diagnostic imaging, resulting in earlier diagnoses and therefore improved prognosis.<sup>1-4</sup> Magnetic resonance imaging (MRI), in addition to mammography and ultrasound, is extremely useful in the detection of breast cancer due to its greater sensitivity and specificity.<sup>5-7</sup> The use of MRI in various areas of breast cancer diagnosis and therapy has been made possible by significant advancements in MRI techniques, that helped in precise cancer diagnosis and anatomic identification.<sup>8-10</sup>

The sensitivity of dynamic contrast-enhanced MRI (DCE-MRI) in detecting breast cancer is rather high, with a range of 88%–100% for invasive breast cancers (Figure 1)<sup>7,11,12</sup> The observed specificity of DCE-MRI, on the other hand, has been widely disparate from 37% to 97%. The specificity

of DCE-MRI varies depending on the lesion criteria utilized to differentiate between benign and malignant breast lesions.<sup>5</sup> Lesions morphology and enhancement kinetics are two widely utilized lesion criteria in identifying breast lesions by DCE-MRI.<sup>13,14</sup>

The morphological assessment of breast lesions is done by assessing their form, margins, enhancement features, enhancement distribution, and internal enhancement pattern, according to the breast imaging reporting & data system (BI-RAD) MRI lexicon. The initial and post-initial enhancement of the breast lesion is detected during kinetic assessment.<sup>15-17</sup>

The goal of this study was to see how well DCE-MRI may separate benign and malignant breast tumors.

## PATIENTS AND METHODS

This prospective study was conducted in a private medical imaging center between October 2020 and June 2021. The study included 32 women (ages

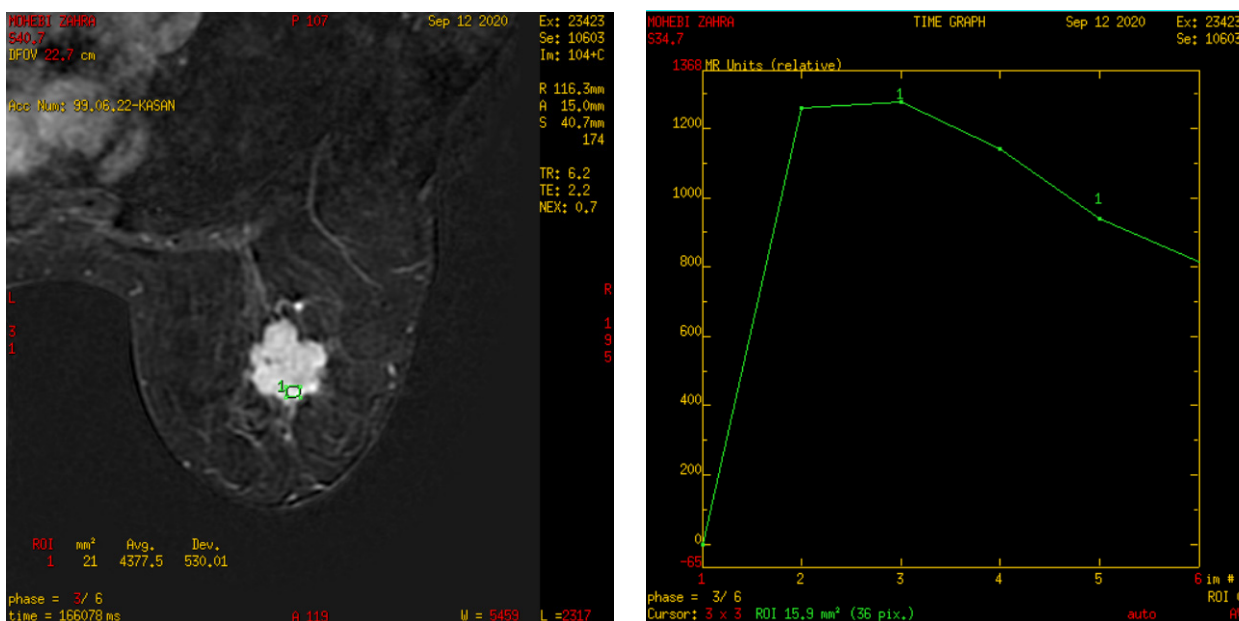


FIGURE 1. DCE-MRI and time-signal intensity curve: left breast lesion.

25 to 75; mean age 46.6 years) who had 32 suspicious breast lesions identified via physical examination, mammography, and ultrasonography.

All of the patients had a detailed history taken with a general and local examination. All patients had conventional MRI and DCE-MRI examinations. The findings of breast MRI were compared to the histopathology results, which were utilized as a gold standard. Patients who agreed to participate in the study gave their informed consent, and the ethics committee approved the study.

A 3-T magnetic resonance (GE) equipment was used to evaluate all of the patients. A specialized breast coil was used to examine all patients in the prone position. The examination included image acquisition followed by image post-processing.

The protocol suggested for breast exam was:

- T2-weighted fast spin-echo sequence
- T1-weighted non-fat-suppressed sequence
- DW sequence
- 3-dimensional T1-weighted fat-suppressed DCE sequence

Imaging parameters of DCE-MRI were as follows:

- repetition time = 4.1
- echo time = 2.1
- field of view = 28 cm
- nex = 0.71
- matrix = 300 × 300
- slice thickness = 2 mm
- gap = 0

The images obtained with 6 post-contrast acquisitions were centered at 40, 120, 200, 280, 360, and 440s.

### RESULT

For their suspicious breast lesions, all 32 patients in this research have taken DCE-MRI.

Their index lesion was also subjected to a histopathologic reference standard test. In 14 patients (43.75%), histopathologic examination revealed benign lesions, while in 18 individuals, malignant lesions were discovered (56.25%). Types of histopathology of 14 benign lesions are listed in Table 1 as follows: 5 lesions (35.71%) were fibroadenomas, 3 lesions (21.42%) were fibrocystic changes (FCC), 2 lesions (14.28%) were mastitis, 2 lesions (14.28%) were fat necrosis, 1 lesion (7.14%) was a postoperative scar, and 1 lesion (7.14%) was postoperative seroma.

The histopathologic types of 18 malignant tumors are listed in Table 2: 6 lesions (33.33%) had invasive duct carcinoma (IDC), 4 lesions (22.22%) had invasive lobular carcinoma (ILC), 3 lesions (16.66%) had mucinous carcinoma, 3 lesions (16.66%) had medullary carcinoma, and 2 lesions (11.11%) had ductal carcinoma in situ (DCI).

**TABLE 1.** 14 benign breast lesions with histopathological diagnoses.

Histopathological type	No.	%
Fibroadenoma	5	35.71
Fibrocystic change	3	21.42
Mastitis	2	14.28
Fat necrosis	2	14.28
Postoperative scar	1	7.14
Postoperative seroma	1	7.14
Total	14	

**TABLE 2.** 18 malignant breast lesions with histopathological diagnoses.

Histopathological type	No.	%
Invasive duct carcinoma (IDC)	6	33.33
Invasive lobular carcinoma (ILC)	4	22.22
Mucinous carcinoma	3	16.66
Medullary carcinoma	3	16.66
Ductal carcinoma in situ (DCI)	2	11.11
Total	18	

The average dimension of benign lesions was 2.7 cm, with a range of 1–7.5 cm, whereas malignant lesions were 2.9 cm, with a range of 2–6.8 cm (Table 3).

There were four rounded lesions, all of which were benign, depending on the form of lesions. There were seven ovoid lesions in all, which were benign. There were 10 lobulated lesions, four of which were benign and six were malignant; and 11 irregular lesions, four of which were benign, and seven were malignant. There were eight smooth margin lesions, all of which were benign; 14 irregular margin lesions, four of which were benign and 10 were malignant; and 10 hypothesized margin

lesions, three of which were benign and seven were malignant (Table 4).

Based on the contrast enhancement pattern of the tumors, homogenous enhancement was noted in nine tumors: six tumors were benign and three were malignant; heterogeneous enhancement was noted in 13 tumors: four tumors were benign and nine were malignant; rim enhancement was noted in seven tumors: three tumors were benign and four were malignant; and non-mass enhancement was noted in three tumors: one tumor was benign and two tumors were malignant. The wash-in rate was slow (50%) in five tumors, all of which were benign; moderate wash-in rate (50–80%) in 12 tumors, all of which were benign. Eight tumors were benign, whereas four were malignant; and 15 tumors had a high wash-in rate >80%, including one benign lesion and 14 malignant lesions. A persistent curve was seen in 12 tumors based on the form of the dynamic curve (time and signal intensity curve). There were 10 benign tumors and two malignant tumors; type II (plateau curve) was found in eight of

**TABLE 3.** A comparison of histopathological data in terms of lesion size.

Size (cm)	Benign	Malignant	<i>p</i>
Average	2.7	2.9	0.46
Range	1–7.5	2–6.8	

*p*: probability; Mann–Whitney U-test used.

**TABLE 4.** The morphologic features of breast lesions (in terms of form and margin) in connection to histological results.

			Benign	Malignant	<i>p</i>
Shape	Rounded	No	4	0	<0.0001
		%	12.5%	0.0%	
	Ovoid	No	7	0	
		%	21.87%	0.0%	
	Lobulated	No	4	6	
		%	12.5%	18.75%	
	Irregular	No	5	6	
		%	15.62%	18.75%	
Margin	Smooth	No	8	0	<0.0001
		%	25%	0.0%	
	Irregular	No	4	10	
		%	12.5%	31.25%	
	Speculated	No	3	7	
		%	9.37%	21.87%	

*p*: probability; The Mann–Whitney U-test was employed.

**TABLE 5.** The enhancement pattern and enhancement kinetics (with regard to wash-in rate and shape of time/signal intensity curve) of breast lesions with histopathological results.

		Groups				<i>p</i>
		Benign		Malignant		
		No.	%	No.	%	
Enhancement pattern	Homogenous enhancement	6	42.85	3	16.66	<0.0001
	Heterogeneous enhancement	4	28.57	9	50	
	Rim enhancement	3	21.42	4	22.22	
	Non-mass enhancement	1	7.14	2	11.11	
Wash in rate	Slow enhancement (<50%)	5	35.71	0	0.0	<0.0001
	Intermediate enhancement (50–80%)	8	57.14	4	22.22	
	Strong enhancement (>80%)	1	7.14	14	77.77	
Shape of time/SI curve	Persistent type I	11	78.57	1	5.55	<0.0001
	Plateau type II	2	14.28	6	33.33	
	Washout type III	1	7.14	11	61.11	

*p*: probability; Mann–Whitney *U*-test employed.

the tumors: three tumors were benign, five tumors were malignant, and 12 tumors had type III (wash-out curve): one tumor was benign, but the other 11 were cancerous (Table 5).

## DISCUSSION

Breast lesions may be detected with excellent accuracy using DCE-MRI. DCE-MRI has additional precision than mammography or ultrasonography for determining the extent of illness in patients with a recent cancer diagnosis but limited capacity to distinguish between benign and malignant lesions in individuals with a recent cancer diagnosis.

The study included 32 women (ages 25 to 75; mean age 46.6 years) who had 32 suspicious breast tumors identified using physical check-ups, mammography, and ultrasonography.

These 32 tumors in the study were divided into 14 benign tumors (43.75%) and 18 malignant (56.25%) tumors, according to the histopathological analysis.

In this study, all mass lesions were done which revealed 32 enhanced lesions. The homogenous enhancement lesions were nine: six lesions were

benign and three lesions were malignant. The heterogeneous enhancement lesions were 13: four lesions were benign and nine were malignant. In rim enhancement, there were seven lesions: three lesions were benign and four were malignant. The non-mass lesions in the present study were three, one of them was benign and the other was malignant. The heterogeneous enhancement was shown to be suggestive of malignant lesions, whereas homogeneous enhancement is more likely to occur in benign lesions. While there are no particular criteria for the enhanced pattern in non-mass lesions, this supports the findings of Tozaki et al.<sup>18,19</sup>

We observed eight tumors with smooth margins (well defined) and all were benign while the other tumors with irregular and speculated margins were mostly malignant. This is similar to Macura et al.'s<sup>20,21</sup> study. According to them, the margin description of a focal mass is the most predictive characteristic of breast MRI interpretation, and hypothesized margins are more worrisome for cancer. The time-signal intensity curve of DCE-MRI revealed 12 lesions that showed a progressive raising curve (type I curve), 11 lesions were benign and one lesion was malignant

by histopathology diagnoses. Eight lesions showed a plateau curve (type II curve), in which two lesions were benign and six were malignant. Twelve lesions showed rapid washout (type III curve), 11 of them were proved by histopathology as malignant. This is congruent with numerous studies like Schnall et al.,<sup>22,23</sup> which demonstrated the relevance of the curve form in distinguishing between malignant and benign tumors. The application of time-signal intensity curves resulted in substantially better discrimination between benign and malignant tumors. Persistent curves are linked with benign lesions, but type III curves are more suggestive of malignant. Plateau curves can indicate whether a lesion is cancerous or benign.<sup>24–30</sup>

### STUDY LIMITATION

The main limitation of our study was the pandemic of coronavirus which caused a decrease in number of participants.

### REFERENCES

1. Sung H, Ferlay J, Siegel RL, Laversanne M, Soerjomataram I, Jemal A, et al. Global Cancer Statistics 2020: GLOBOCAN estimates of incidence and mortality worldwide for 36 cancers in 185 countries. *CA Cancer J Clin.* 2021;71(3):209–49. <https://doi.org/10.3322/caac.21660>
2. Berg WA, Zhang Z, Lehrer D, Jong RA, Pisano ED, Barr RG, et al. Detection of breast cancer with addition of annual screening ultrasound or a single screening MRI to mammography in women with elevated breast cancer risk. *JAMA – J Am Med Assoc.* 2012;307(13):1394–404. <https://doi.org/10.1001/jama.2012.388>
3. Akram M, Iqbal M, Daniyal M, Khan AU. Awareness and current knowledge of breast cancer. *Biol Res.* 2017;50(1):1–23. <https://doi.org/10.1186/s40659-017-0140-9>
4. Labrèche F, Goldberg MS, Hashim D, Weiderpass E. Breast cancer. *Occup Cancers.* 2020;10:417–38. [https://doi.org/10.1007/978-3-030-30766-0\\_24](https://doi.org/10.1007/978-3-030-30766-0_24)
5. Peters N, IH BR, NP Z, WP M, KF M, Peeters P. Meta-analysis of MR imaging in the diagnosis of breast lesions. *Radiology.* 2008;246(1):116–24. <https://doi.org/10.1148/radiol.2461061298>
6. Menezes GLG, Knuttel FM, Stehouwer BL, Pijnappel RM, Van Den Bosch MAAJ. Magnetic resonance imaging in breast cancer: A literature review and future perspectives. *World J Clin Oncol.* 2014;5(2):61–70. <https://doi.org/10.5306/wjco.v5.i2.61>
7. Salem DS, Kamal RM, Mansour SM, Salah LA, Wessam R. Breast imaging in the young: The role of magnetic resonance imaging in breast cancer screening, diagnosis and follow-up. *J Thorac Dis.* 2013;5(SUPPL.1):S9–S18.
8. Lee JS, Lee HY, Sung NS, Cheon KW, Moon JI, Lee SE, et al. Accuracy of physical examination, ultrasonography, and magnetic resonance imaging in predicting response to neo-adjuvant chemotherapy for breast cancer. *Tomography.* 2016;125(11):55–9. <https://doi.org/10.18383/j.tom.2016.00247>
9. Selvi Radhakrishna, Agarwal S, Purvish M. Parikh, Kaur K, Shikha Panwar, Shelly Sharma, et al. Role of magnetic resonance imaging in breast cancer management. *South Asian J Cancer.* 2018;7(2):171–4. [https://doi.org/10.4103/sajc.sajc\\_104\\_18](https://doi.org/10.4103/sajc.sajc_104_18)
10. Morrow M. Magnetic resonance imaging in the preoperative evaluation of breast cancer: Primum non nocere. *J Am Coll Surg.* 2004;198(2):240–1. <https://doi.org/10.1016/j.jamcollsurg.2003.10.013>
11. Huang W, Fisher PR, Dulaimy K, Tudorica LA, O’Hea B, Button TM. Detection of breast malignancy: Diagnostic MR protocol for improved specificity. *Radiology.* 2004;232(2):585–91. <https://doi.org/10.1148/radiol.2322030547>
12. Warren RML, Pointon L, Thompson D, Hoff R, Gilbert FJ, Padhani A, et al. Reading protocol for dynamic contrast-enhanced MR images of the breast: Sensitivity and specificity analysis. *Radiology.* 2005;236(3):779–88. <https://doi.org/10.1148/radiol.2363040735>
13. Nunes LW, Schnall M, Siegelman ES, Langlotz CP, Gorel S, Sullivan D, et al. Diagnostic performance characteristics of architectural features revealed by high spatial-resolution MR imaging of the breast. *Am J Roentgenol.* 1997;169(2):409–15. <https://doi.org/10.2214/ajr.169.2.9242744>

14. Kuhl CK, Mielcareck P, Klaschik S, Leutner C, Wardelmann E, Gieseke J, et al. Dynamic breast MR imaging: Are signal intensity time course data useful for differential diagnosis of enhancing lesions? *Radiology*. 1999;211(1):101–10. <https://doi.org/10.1148/radiology.211.1.r99ap38101>
15. Kul S, Cansu A, Alhan E, Dinc H, Gunes G, Reis A. Contribution of diffusion-weighted imaging to dynamic contrast-enhanced MRI in the characterization of breast tumors. *Am J Roentgenol*. 2011;196(1):210–17. <https://doi.org/10.2214/AJR.10.4258>
16. Sohns C, Scherrer M, Staab W, Obenauer S. Value of the BI-RADS classification in MR-mammography for diagnosis of benign and malignant breast tumors. *Eur Radiol*. 2011;21(12):2475–83. <https://doi.org/10.1007/s00330-011-2210-7>
17. Bi-rads ACR, Mri B. ACR Bi-Rads® Atlas — Breast MRI. *Am Coll Radiol* [Internet]. 2013;125–43. Available from: <https://www.acr.org/-/media/ACR/Files/RADS/BI-RADS/MRI-Reporting.pdf>
18. Tozaki M, Fukuda K. High-spatial-resolution MRI of non-masslike breast lesions: Interpretation model based on BI-RADS MRI descriptors. *Am J Roentgenol*. 2006;187(2):330–7. <https://doi.org/10.2214/AJR.05.0998>
19. Newell D, Nie K, Chen JH, Hsu CC, Yu HJ, Nalcioğlu O, et al. Selection of diagnostic features on breast MRI to differentiate between malignant and benign lesions using computer-aided diagnosis: Differences in lesions presenting as mass and non-mass-like enhancement. *Eur Radiol*. 2010;20(4):771–81. <https://doi.org/10.1007/s00330-009-1616-y>
20. Macura KJ, Ouwerkerk R, Jacobs MA, Bluemke DA. Patterns of enhancement on breast MR images: Interpretation and imaging pitfalls. *Radiographics*. 2006;26(6):1719–34. <https://doi.org/10.1148/rg.266065025>
21. Kim YR, Kim HS, Kim HW. Are irregular hypoechoic breast masses on ultrasound always malignancies?: A pictorial essay. *Korean J Radiol*. 2015;16(6):1266–75. <https://doi.org/10.3348/kjr.2015.16.6.1266>
22. Article O. The role of dynamic contrast enhanced magnetic resonance imaging in differentiation of soft tissue masses. *Eur J Gen Med*. 2016;13(1):37–44. <https://doi.org/10.15197/ejgm.01412>
23. Schnall MD, Rosten S, Englander S, Orel SG, Nunes LW. A combined architectural and kinetic interpretation model for breast MR images. *Acad Radiol*. 2001;8(7):591–7. [https://doi.org/10.1016/S1076-6332\(03\)80683-9](https://doi.org/10.1016/S1076-6332(03)80683-9)
24. Li T, Yu T, Li L, Lu L, Zhuo Y, Lian J, et al. Use of diffusion kurtosis imaging and quantitative dynamic contrast-enhanced MRI for the differentiation of breast tumors. 2018;48(5):1358–66. <https://doi.org/10.1002/jmri.26059>
25. Hetta W. Role of diffusion weighted images combined with breast MRI in improving the detection and differentiation of breast lesions. *Egypt J Radiol Nucl Med* [Internet]. 2015;46(1):259–70. <https://doi.org/10.1016/j.ejrnm.2014.10.009>
26. Cuenod CA, Balvay D. Perfusion and vascular permeability : Basic concepts and measurement in DCE-CT and DCE-MRI. *Diagn Interv Imaging* [Internet]. 2013;94(12):1187–204. <https://doi.org/10.1016/j.diii.2013.10.010>
27. Dmitry Olegovich Bokov, Abduladheem Turki Jalil, Forat H. Alsultany, Mustafa Z. Mahmoud, Wanich Suksatan, Supat Chupradit, et al. Ir-decorated gallium nitride nanotubes as a chemical sensor for recognition of mesalamine drug: A DFT study. *Molecular Simulat*. 2022;48(5). <https://doi.org/10.1080/08927022.2021.2025234>
28. Ansari MJ, Jasim SA, Taban TZ, Bokov DO, Shalaby MN, Al-gazally ME, et al. Anticancer drug-loading capacity of green synthesized porous magnetic iron nanocarrier and cytotoxic effects against human cancer cell line. *J Clust Sci*. 2022. <https://doi.org/10.1007/s10876-022-02235-4>
29. Huldani Huldani, Saade Abdalkareem Jasim, Dmitry Olegovich Bokov, Walid Kamal Abdelbasset, Mohammed Nader Shalaby, Lakshmi Thangavelu, et al. Application of extracellular vesicles derived from mesenchymal stem cells as potential therapeutic tools in autoimmune and rheumatic diseases. *Int Immunopharmacol*. 2022;106:108634. ISSN 1567-5769. <https://doi.org/10.1016/j.intimp.2022.108634>