



ORIGINAL RESEARCH  
DOI: 10.47750/jptcp.2022.861

## Surgical interventions for inferior turbinate hypertrophy

Ali Abd-Almer Jwad<sup>1,\*</sup>, Wasam A. Albualih<sup>2</sup> and Abbas Kalaf Mahdi<sup>2</sup>

<sup>1</sup>Department of Otolaryngology, University of AL-Qadisiyah, College of Medicine, Iraq

<sup>2</sup>Department of Otolaryngology and Head and Neck Surgery, Al-Diwaniyah General Teaching Hospital, Diwaniyah City, Iraq

\*Corresponding author: Ali Abd-Almer Jwad, Department of Otolaryngology, University of AL-Qadisiyah, College of Medicine, Iraq. Email: [ali.jwad@qu.edu.iq](mailto:ali.jwad@qu.edu.iq)

Submitted: 19 October 2021; Accepted: 23 December 2021; Published: 21 January 2022

---

### ABSTRACT

**Background and Aim:** Nasal obstruction can be induced by various causes; however, inferior turbinate hypertrophy is considered the most frequent cause of this anatomical malfunctioning condition. The current surgical interventional study was focused on comparing the final outcomes of partial inferior turbinectomy (PIT) and powered endoscopic turbinoplasty (PET).

**Subjects and Methods:** The criterion followed for deciding the successfulness of each surgical method was the rate of occurrence of postoperative complications such as bleeding, crustation, and atrophic rhinitis. Fifty patients who suffered from nasal obstruction were randomly divided into two groups: PIT group, with 25 patients, of which 15 (52%) were males and 10 were (48%) females, at an average age of  $27.40 \pm 7.7$  years, and PET group, with 25 patients, out of which 14 (48%) were males and 11 (62%) were females, at an average age of  $26.68 \pm 6.82$  years. The surgical operations were performed at the Department of Otolaryngology, Al-Diwaniyah General Teaching Hospital, Diwaniyah City, Iraq, during the period between March 2015 and March 2020.

**Results:** The PET group showed significantly lower incidence ( $P < 0.05$ ) of bleeding and crustation than those from the PIT group; however, no significant differences ( $P > 0.05$ ) were observed between PIT and PET in the occurrence of atrophic rhinitis.

**Conclusion:** PET showed promisingly less postoperative complications when compared to PIT.

**Keywords:** *nasal obstruction; partial inferior turbinectomy; powered endoscopic turbinoplasty. inferior turbinate hypertrophy, powered endoscopic turbinoplasty*

## INTRODUCTION

One of the most frequently occurred human health problems is nasal obstruction caused mainly by inferior turbinate hypertrophy (ITH), resulting in an anatomical malfunctioning bodily compartment.<sup>1</sup>

It has been confirmed that the anterior end of the inferior nasal turbinate is the specific location in which high rates of nasal resistance cases are clinically presented. The ITH can be initiated as a result of different nasal health issues such as infectious rhinitis, allergies, eosinophilic syndrome, medications, vasomotor malfunction, and iatrogenic rhinopathy. The ITH can be mucosal or bony, which allows for better decisions by the surgeon to use surgical interventions for the cases that show no response to medical measures.<sup>2</sup> There are several surgical procedures that can be employed to improve the ITH. Even though there are several surgical techniques, the interventional procedure chosen should be successful in providing long-term ITH size reduction accompanied by existence of a properly working turbinate that shows little or no complications.<sup>3</sup>

Turbinoplasty or submucosal resection was suggested to provide promising evidence of an ideal ITH size reduction technique, especially after introducing microdebrider as a beneficial tool in nasal surgeries, allowing for comfortable and trustful performing of ITH size reduction with the employment of the powered system.<sup>4-6</sup>

For the better understanding of the advantages and disadvantages of the powered endoscopic turbinoplasty (PET), this surgical interventional study was focused on comparing the final outcomes of partial inferior turbinectomy (PIT) and PET using the rate of occurrence of postoperative complications, such as bleeding, crustation, and atrophic rhinitis, as an evaluating system for the success of these methods.

## MATERIALS AND METHODS

### Subjects

The international and national ethical principles were carefully followed. Fifty patients who suffered

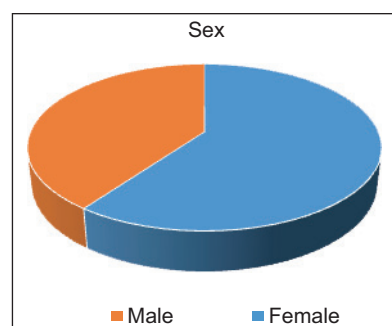
from nasal obstruction were randomly divided into two groups: PIT group, with 25 patients, of which 15 (52%) were males and 10 (48%) were females, at an average age of  $27.40 \pm 7.7$  years, and PET group, with 25 patients, out of which 14 (48%) were males and 11 (62%) were females, at an average age of  $26.68 \pm 6.82$  years as shown in Figure 1.

### Techniques

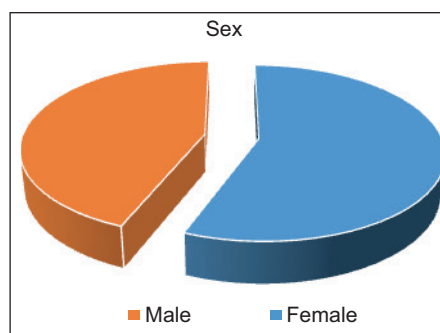
The techniques were performed under general anesthesia.

### Partial inferior turbinectomy

The PIT technique was ensured by initiating inferior turbinate lateralization using freer elevator, followed by hypertrophied tissue (mucosa,



**FIGURE 1.** Male-to-female ratio in powered endoscopic turbinoplasty.



**FIGURE 2.** Male-to-female ratio in partial inferior turbinectomy.

submucosa, and bony structures) removal with the use of a turbinectomy scissor and a head light (conventional instruments).

### **Powered endoscopic turbinoplasty**

Using a zero-angled endoscope, the PET was performed to dissect the soft tissues of the inferior turbinate at its vertical portion using a microdebrider with an oscillate-mode-based straight blade. A major amount of the soft tissues plus the turbinate bone were then removed using the forward-mode-directed microdebrider taking extra precautions to preserve the medial part of the soft tissues of bony lamella. Any remaining bony fragments were removed using a malleable probe and a pediatric backbiter. Later, lateral mucosa and bone were dissected.

### **Postoperative examination for the presence of complications**

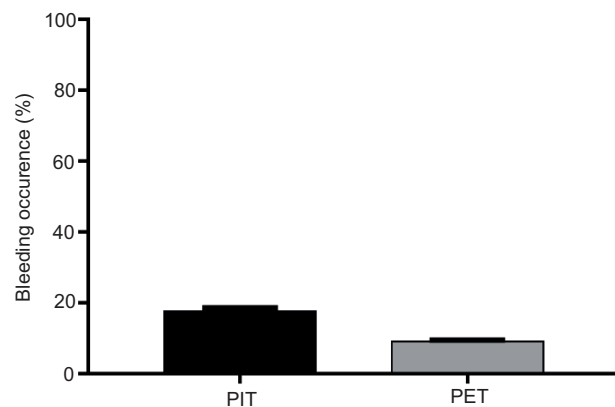
The criterion followed for deciding the successfulness of each surgical method was the rate of occurrence of postoperative complications such as bleeding, crustation, and atrophic rhinitis. The cases were endoscopically examined for the presence of nasal blood clots or bleeding, crust-like structures, and atrophic rhinitis. The time points for such examinations were Week No.1, Week No. 4, and Week No. 12 after the surgical interventions.

### **Statistical analysis**

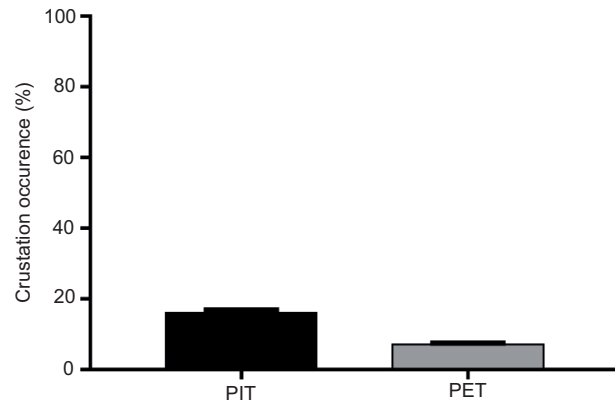
GraphPad Prism v7.00 was used to process the data using Student's *t*-test. The data are presented as mean  $\pm$  SE unless it is mentioned. The rejection of the null hypothesis was decided if *P* was less than 0.05.

## **RESULTS**

The PET group showed significantly lower incidence of bleeding ( $P < 0.0001$ ) (Figure 3) and crustation (Figure 4) than those from the PIT group; however, no significant differences ( $P > 0.05$ ) were



**FIGURE 3.** The occurrence of postoperative bleeding in partial inferior turbinectomy or powered endoscopic turbinoplasty. Significant differences are shown ( $P < 0.0001$ ).



**FIGURE 4.** The occurrence of postoperative crustation in partial inferior turbinectomy or powered endoscopic turbinoplasty. Significant differences are shown ( $P < 0.0001$ ).

observed between PIT and PET in the occurrence of atrophic rhinitis (data not shown).

## **DISCUSSION**

This research provides information about the successfulness of both surgical strategies, PIT and PET, in removing the turbinate hypertrophied structures blocking the nasal passage; however, PET has more advantages over PIT.

In the case of the blood clots or presence of bleeding, PET showed the lowest rates when compared to the high results from PIT. The procedure by PET provides an excellent surgical intervention with less traumatized tissues, leading to less postoperative presence of blood clots in the nasal airways. Interestingly, the postoperative crust formation was lesser in the PET than that after performing the PIT technique. The presence of crustation can be due to excessive damages applied directly on the mucosa by PIT; however, the soft tissue medial was kept intact when using the PET technique. The PET, according to this, ensures a proper working mucociliary clearance system. On the other hand, PIT causes major damages to the mucociliary epithelium, leading to the presence of postoperative blood clots and crusts. Moreover, the PET ensures careful and complete removal of all bony fragments with proper positioning of mucosal flap, which enhances better healing with less or no blood clots or crust formation.<sup>7,8</sup>

It has been reported that ITH can be treated with several methods; however, all of those techniques (such as cryosurgery, surface electrocautery, and total turbinectomy) cause direct tissue damage leading to the development of malfunctioned turbinate.<sup>9</sup> Though some techniques provide submucosal tissue reduction with the use of some agents such as injection of steroids, however, the action of this preservation can be maintained only for a short period of time.<sup>10</sup>

The PET technique is the most reliable method that can enhance ITH reduction with minimal occurrence of postoperative complications such as bleeding and crustation. On the other hand, the rigid endoscope-based turbinoplasty is highly preferred in the ITH reduction techniques.<sup>11–15</sup>

## CONCLUSION

PET shows promisingly less postoperative complications than PIT.

## REFERENCES

1. Gottarelli P. (2012) Introduction. In: Modified Inferior Turbinoplasty. Springer, Milano. [https://doi.org/10.1007/978-88-470-2442-7\\_1](https://doi.org/10.1007/978-88-470-2442-7_1)
2. Friedman M, Vidyasagar R. Surgical management of septal deformity, turbinate hypertrophy, nasal valve collapse and choanal atresia. In: Bailey BJ, Johnson JT, Newlands SD, editors. Head and neck surgery—Otolaryngology. 4th ed. Philadelphia, PA: Lippincott Williams & Wilkins; 2006. p. 319–34.
3. Jourdy D. Inferior turbinate reduction. Oper Tech Otolaryngol Head Neck Surg. 2014;25(2):160–70. <https://doi.org/10.1016/j.otot.2014.02.005>
4. Setliff RC, Parsons DS. The “hammer”: New instrumentation for functional endoscopic sinus surgery. Am J Rhinol. 1994;8(6):275–8. <https://doi.org/10.2500/105065894781874232>
5. Hol MK, Huizing EH. Treatment of inferior turbinate pathology: A review and critical evaluation of the different techniques. Rhinology. 2000;38(4):157–66. Available from: <http://www.ncbi.nlm.nih.gov/pubmed/11190749>
6. Lee, KC, Hwang PH, Kingdom TT. Surgical management of inferior turbinate hypertrophy in the office: Three mucosal sparing techniques. Oper Tech Otolaryngol Head Neck Surg. 2001;12(2):107–11. <https://doi.org/10.1053/otot.2001.24771>
7. Wengraf CL, Gleeson MJ, Siodlak MZ. The stuffy nose: A comparative study of two common methods of treatment. Clin Otolaryngol Allied Sci. 2019;11(2):61–8. <https://doi.org/10.1111/j.1365-2273.1986.tb00109.x>. Available from: <http://www.ncbi.nlm.nih.gov/pubmed/3708884>
8. Passali D, Passali FM, Damiani V, Passali GC, Bellussi L. Treatment of inferior turbinate hypertrophy: A randomized clinical trial. Ann Otol Rhinol Laryngol. 2003;112(8):683–8. <https://doi.org/10.1177/000348940311200806>
9. Ibrahim S, Kamel AA, El-Fouly, MS, Wahba, BM, Herzallah RH. Powered turbinoplasty versus powered turbinectomy: A comparative study. Egypt J Otolaryngol. 2017;33(1):9. <https://doi.org/10.4103/1012-5574.199402>
10. Tahmasebi S, Qasim MT, Krivenkova MV, Zeki AO, Thangavelu L, Aravindhan S, et al.

- The effects of oxygen ozone therapy on regulatory T cell responses in multiple sclerosis patients. *Cell Biol Int* 2021;45(7):1498–509. <https://doi.org/10.1002/cbin.11589>
11. Karataş A. Pretreatment prediction of the outcomes of intranasal steroid sprays in cases with inferior turbinate hypertrophy. *Turk Arch Otorhinolaryngol.* 2017;55(3):105–10. <https://doi.org/10.5152/tao.2017.2443>
  12. Shabgah AG, Qasim MT, Mostafavi SM, Zekiy AO, Ezzatifar F, Ahmadi M, et al. CXC chemokine ligand 16: A Swiss army knife chemokine in cancer. *Exp Rev Mol Med.* 2021;23:e4. <https://doi.org/10.1017/erm.2021.7>
  13. Mori S, Fujieda S, Yamada T, Kimura Y, Takahashi N, Saito H. Long-term effect of submucous turbinectomy in patients with perennial allergic rhinitis. *Laryngoscope.* 2002;112(5):865–9. <https://doi.org/10.1097/00005537-200205000-00016>
  14. Mohammed ZI, Qasim MT. Hormonal profile of men during infertility. *Biochem Cell Arch* 2021;21:2895–8. Available from: <https://connect-journals.com/03896.2021.21.2895>.
  15. Kassab AN, Rifaat M, Madian Y. Comparative study of management of inferior turbinate hypertrophy using turbinoplasty assisted by microdebrider or 980 nm diode laser. *J Laryngol Otol.* 2012;126(12):1231–7. <https://doi.org/10.1017/S0022215112002320>