



## “TO CORRELATE THE DIAGNOSTIC LAPAROSCOPIC FINDINGS WITH THE CLINICAL AND RADIOLOGICAL FINDINGS IN CHRONIC ABDOMINAL PAIN PATIENTS.”

Dr Suvriti Chaurasia<sup>1</sup>, Dr Satyam Chaurasia<sup>2\*</sup>

<sup>1</sup>Senior resident, Department of Cardiothoracic and Vascular Surgery, Netaji Subhash Chandra Bose Medical College, Jabalpur, Madhya Pradesh, India 482003, Email: suvi.chaurasia1@gmail.com

<sup>2\*</sup>Designation Senior resident, Department Pathology, Government Medical College, Satna, Madhya Pradesh, India 485001, Email: satyambdc@gmail.com

**\*Corresponding author:** Dr Satyam Chaurasia

\*Designation Senior resident, Department Pathology, Government Medical College, Satna, Madhya Pradesh, India 485001, Email: satyambdc@gmail.com

### Abstract

**Background and Objective:** Chronic abdominal pain is defined as continuous or intermittent abdominal discomfort/pain lasting for more than 3 months. Diagnostic laparoscopy is an emerging tool in diagnosis of chronic non-specific abdominal pain, the diagnosis of which remains uncertain despite employing the requisite laboratory and non-invasive imaging investigations. The aim of our study was- to correlate the findings of diagnostic laparoscopy with the clinical and radiological findings.

**Materials and Methods:** this is a prospective single centre study done in Department of Surgery of Sanjay Gandhi Memorial Hospital associated with S.S. Medical College, Rewa (M.P.) during the period of 1<sup>st</sup> June 2016 to 31<sup>st</sup> May 2017. Our study was carried out on 48 patients admitted in surgical wards. All patients having chronic abdominal pain were included in the study, and patients with acute abdominal pain, with an uncorrectable coagulopathy, or uncorrectable hypercapnia and pregnant females were excluded from the study. Detailed history, examination, baseline blood, and radiological investigations were done to reach to diagnosis. Patients were subjected to diagnostic laparoscopy, and the necessary surgical therapeutic interventions during laparoscopy were employed as per the etiology after taking informed written consent. The usefulness of laparoscopy to confirm the diagnosis and clinical management of these patients of chronic abdominal pain was evaluated.

**Result:** Our study was carried out on 48 patients admitted in surgical wards. The incidence of chronic abdominal pain was almost equal in both genders. Peak incidence was seen in the age group of 31–40 years. Abdominal pain was present in all cases 48/48 (100%) as a chief complaint followed by abdominal distension in 17/48 (35.41%). Average duration of pain was  $10.92 \pm 5.88$  months. 18 (37.5%) showed normal USG findings, 15 (31.25%) had dilated bowel loops and bowel thickening, 6 (12.5%) had ascites, 4 (8.33%) had mesenteric lymphadenopathy, while gaseous distension was seen in 2 (4.17%). CT of abdomen was done in 11 (22.9%) patients. 10 (20.8%) patients showed pathological findings (ascitis, mesenteric fat thickening, lymphadenopathy, multiloculated collection, GB mass, Dilated bowel loops, pleural effusion, bowel thickening). Koch's abdomen was the most common finding during laparoscopy followed by chronic/recurrent appendicitis. Definitive diagnosis was made in 43 patients, and 38 patients had shown resolution of pain after diagnostic

laparoscopy.

**Conclusion:** Laparoscopy offers a definitive diagnosis in a large number of patients of chronic abdominal pain and also provides therapeutic intervention. An early resort to laparoscopy can resolve the diagnostic dilemma and early treatment can be instituted.

**Keywords-** chronic abdominal pain, exploratory laparotomy, diagnostic laparotomy, bowel obstruction, tubercular abdomen.

**Introduction-** Chronic abdominal pain is defined as continuous or intermittent abdominal discomfort/pain lasting for more than 3 months. The etiology of chronic abdominal pain is very wide. Pain may arise from any system, including the genitourinary, gastrointestinal, and gynecological tracts. A clear relationship with an anatomical structure or underlying process may not always be present. People with chronic abdominal pain may also have other symptoms, depending on the cause. The most common organic conditions include intestinal adhesions, especially in patients with a past history of abdominal operations, abdominal tuberculosis, mesenteric lymphadenopathy (could also be due to infectious causes of bowel such as colitis, gastroenteritis, or enteric fever apart from tuberculosis), biliary causes, appendicular causes, and hernia, while functional conditions include irritable bowel disease, functional dyspepsia, and various motility disorders.

An accurate diagnosis is an important first step to determine the correct treatment for pain resolution. Thus, the management of chronic abdominal pain underlines the need for an interdisciplinary approach to diagnosis. This requires the focused and intelligent use of efficient diagnostic tools.

The success of laparoscopy in making definite and reliable diagnosis of abdominal disorders over the past two decades has firmly established it in the armamentarium of a general surgeon to perform this procedure safely. Due to improvements in instrumentation and greater experience with diagnostic and therapeutic laparoscopy, the procedure is no longer limited to visualization. It can identify abnormal findings and improve the outcome in majority of patients with chronic abdominal pain, as it allows surgeons to see and treat many abdominal conditions that cannot be diagnosed otherwise. It also decreases the number of unwanted laparotomies. Hence, diagnostic laparoscopy should be considered for patients suffering from chronic abdominal pain, as it is minimally invasive, safe, efficacious, and effective diagnostic modality and can be performed rapidly, safely with minimal sequel, and in selected cases, pathology can be dealt with.

**Aims-** main aim of study is-’to correlate the diagnostic laparoscopic findings with the clinical and radiological findings in chronic abdominal pain patients. In addition, a negative laparoscopic examination potentially would avoid the morbidity and unnecessary laparotomy in this group.

**Methods and materials-** The present study was carried out on patients admitted in surgical wards in the Department of Surgery of Sanjay Gandhi Memorial Hospital associated with S.S. Medical College, Rewa Madhya Pradesh, during 1<sup>st</sup> June 2016 to 31<sup>st</sup> May 2017.

**Inclusion criteria-** All patients having chronic abdominal pain were included in the study.

**Exclusion criteria-** The following criteria were excluded from the study:

1. Patients with acute abdominal pain.
2. Patients with an uncorrectable coagulopathy or uncorrectable hypercapnia.
3. Pregnant females.

A total of 48 patients getting admitted in the surgical wards through SOPD, casualty, and transferred from other departments with a complaint of chronic abdominal pain during the period of study were included in the study. On admission, detailed history and clinical examination were conducted giving emphasis on the duration, site of pain, previous history of any surgery, and other related problems. Baseline investigations such as complete blood count, urinalysis, blood sugar (fasting and post-

prandial), blood urea, serum creatinine, liver function test, coagulation profile, serum electrolytes (Na, K, Cl, and Ca), HIV, hepatitis B and C profile, blood grouping, chest X-ray, and electrocardiograph were done. Abdominal radiographs, ultrasonography (USG), skiagrams of spine in all cases, and computed tomography (CT) scan of abdomen in selected cases were done to reach to diagnosis. The data were noted on a predesigned pro forma.

Based on the clinical examinations and imaging studies, patients were subjected to diagnostic laparoscopy and the necessary surgical therapeutic interventions during laparoscopy were employed as per the etiology after taking informed written consent. Biopsy from suspected site (peritoneal lesion, omentum, and mesenteric lymph nodes) and peritoneal fluid for routine microscopy and culture-sensitivity were also taken.

Post-operatively, all patients were kept nil orally for 24–48 h. Patients were monitored with pulse, blood pressure, and temperature charting. Injectable antibiotics and analgesics were used accordingly. Ryle's tube and urinary catheter were removed depending on the condition. Appropriate treatment was started once the diagnosis was established. Patients were followed up at regular intervals post-discharge after the procedure. Subjective assessment of pain was done by asking the patients, what occurred to their pain, relief, reduced, or no change.

This study included the patients who were admitted to the hospital with a history of chronic abdominal pain with inconclusive clinical examination, laboratory, and imaging studies. The findings and outcomes of laparoscopy were recorded in a master chart and analyzed. Outcome measured which included the overall efficacy of diagnostic laparoscopy in finding a cause of chronic abdominal pain and its correlation with clinical and radiological findings, clinical diagnosis made versus final diagnosis, post-operative complications, and response to pain after procedure.

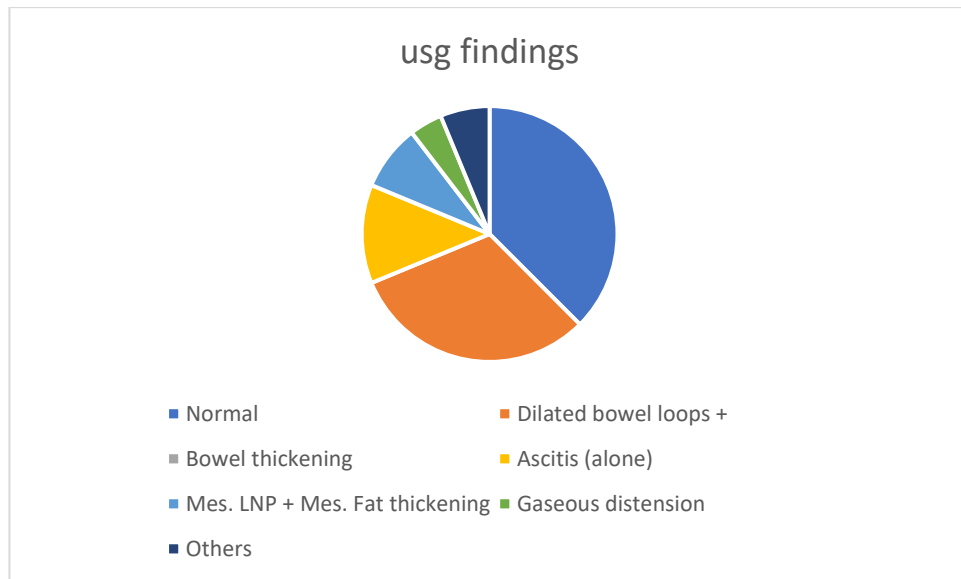
**Results:-** this is a prospective single centre study done in Department of Surgery of Sanjay Gandhi Memorial Hospital associated with S.S. Medical College, Rewa (M.P.) during the period of 1<sup>st</sup> June 2016 to 31<sup>st</sup> May 2017. Results of study are

The peak incidence was seen in the age group of 31–40 years 14 (29.17%). In our study, youngest patient was 14 years' old and oldest was 65 years' old. The mean age of presentation was  $35.95 \pm 13.65$  years. The incidence of chronic abdominal pain was almost equal in both females 25 (52.1%) and males 23 (47.9%). Mean age of presentation in males was  $36.26 \pm 13.88$  and mean age in females was  $35.68 \pm 13.71$  years.

Abdominal pain was present in all cases 48/48 (100%) as a chief complaint followed by abdominal distension in 17/48 (35.41%), fever in 13/48 (27.08%), and 10 patients (20.8%) presented with nausea and vomiting (6 had nausea alone). Anorexia/weight loss was present in 8/48 (16.67%) of patients.

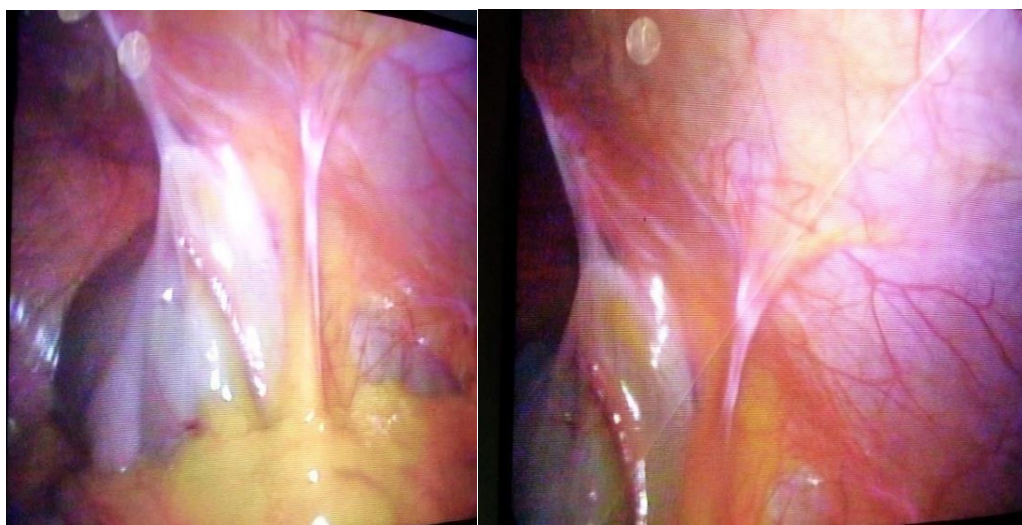
Most of the patients 29 (60.42%) had duration of pain ranging between 7 and 12 months, followed by 3–6 and 13–18 months in 8 (16.67%), 19–24 months in one (2.08%), and >2 years in 2 patients. Average duration of pain was  $10.92 \pm 5.88$  months. Most of the patients was presented with right lower quadrant pain 19 (39.58%), followed by diffuse pain in 13 (27.08%), periumbilical pain in 7 (14.58%), left lower quadrant pain in 2, right upper quadrant pain in 2, left upper quadrant region pain in 2, and right and left lower quadrant pain in 3 cases. 13 (27.08%) had a history of previous surgery and 35 (72.92%) had no history of surgery. All patients who presented with post-operative adhesion had a previous history of surgery [Table 1].

18 (37.5%) showed normal USG findings, 15 (31.25%) had dilated bowel loops and bowel thickening, 6 (12.5%) had ascites, 4 (8.33%) had mesenteric lymphadenopathy, while gaseous distension was seen in 2 (4.17%). Other findings were seen in 3 (6.25%) cases.



Of the 18 patients with normal USG findings, 5 had no abnormality detected during diagnostic laparoscopy, while 13 patients had new findings (4 had findings suggestive of Koch's abdomen [Figure 1], 4 of chronic/recurrent appendicitis, 3 of pelvic inflammatory disease (PID), one had findings suggesting post-operative adhesion, and one patient had findings suggestive of chronic hepatitis).

### Diagnostic Laparoscopy

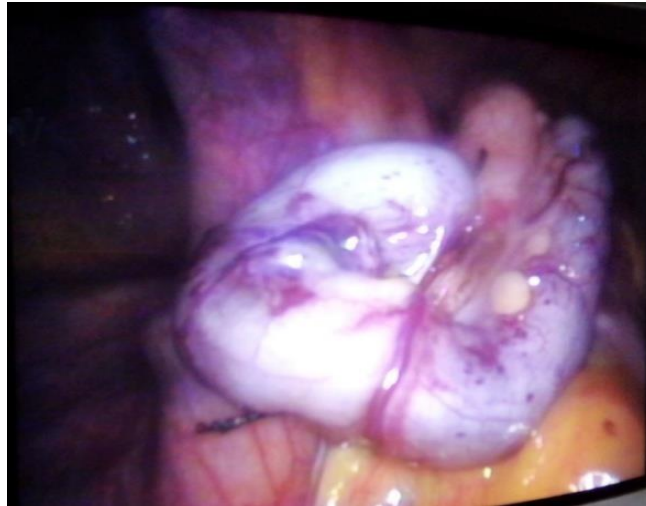


1(a)

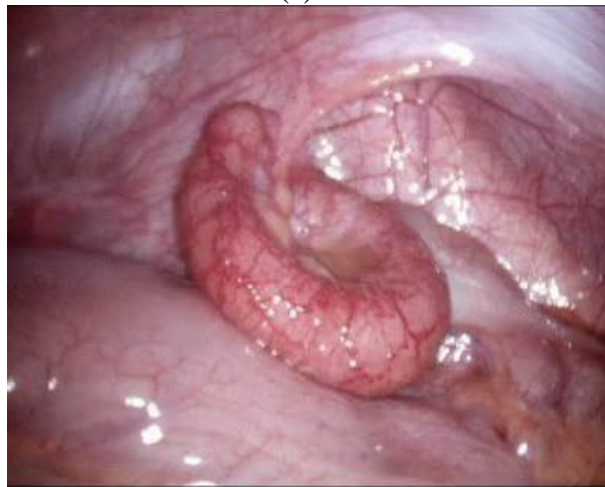1(b)

**Fig.1(a and b): Bowel adhesions to anterior abdominal wall**



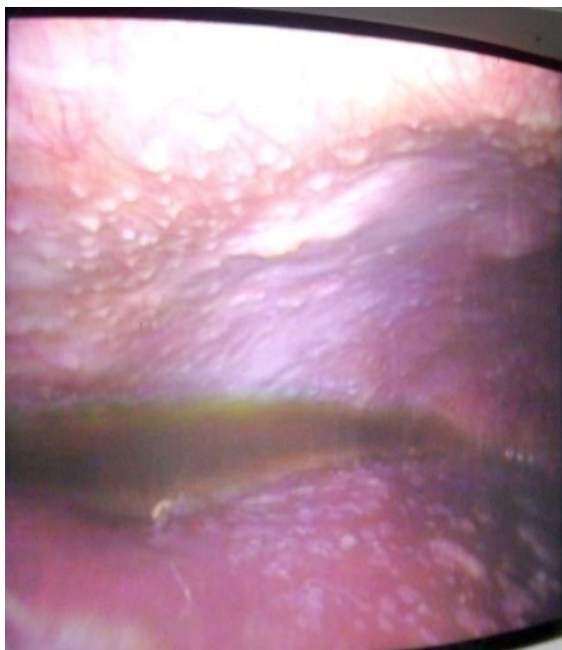

2(a)

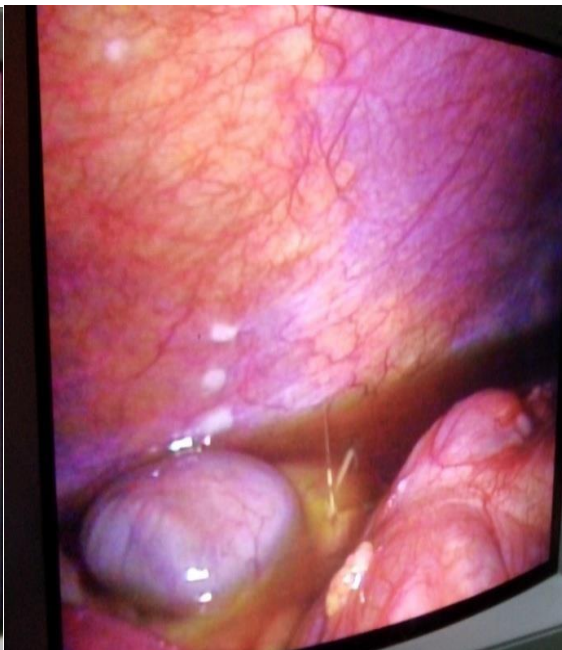


2(b)

**Fig.2(a and b): Inflamed appendix seen during laparoscopy.**

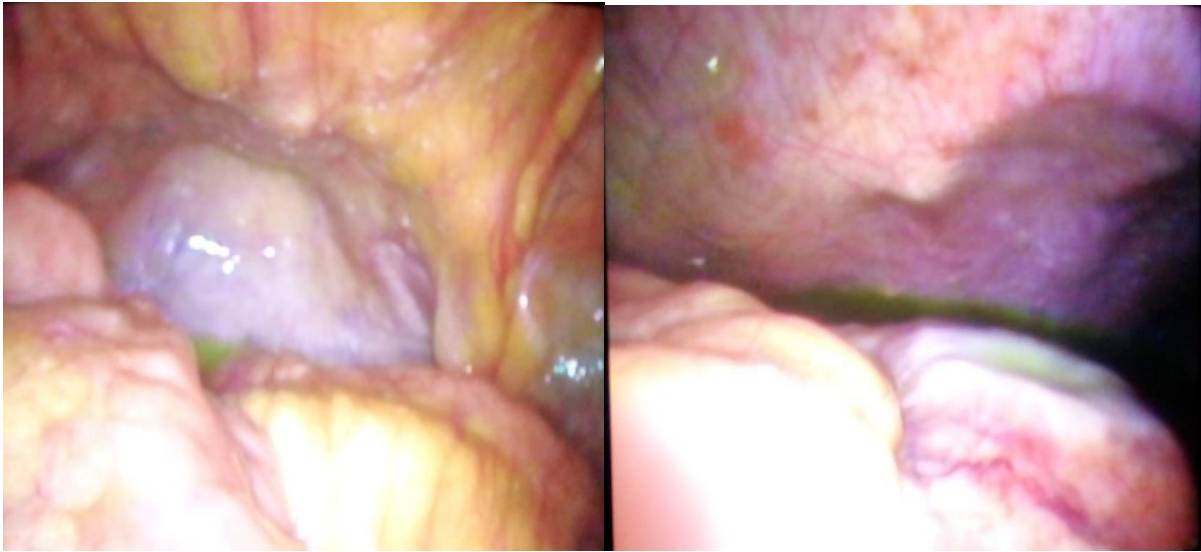

3(a)

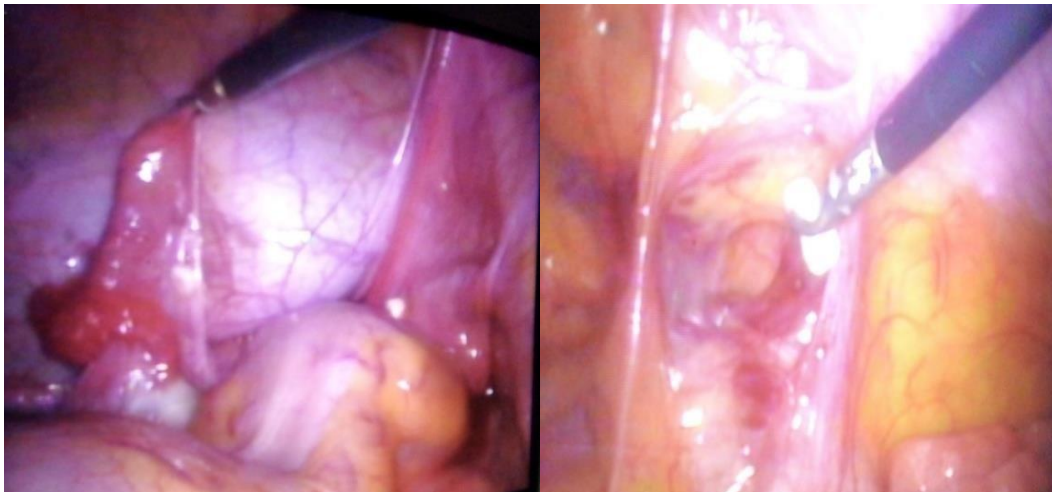


3(b)

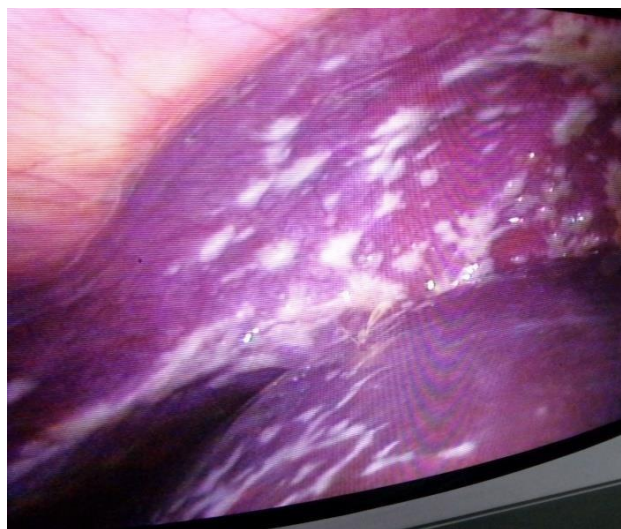
**Fig.3(a and b): Peritoneal tubercles with ascitis (Koch's abdomen).**



4(a) 4(b)  
**Fig.4(a and b): GB fossa malignancy with hepatic metastasis.**



5(a) 5(b)  
**Fig.5(a and b): Pelvic adhesions around misplaced tubal ring.**



**Fig.6: Hepatic metastasis.**

laparoscopy, 6 (12.5%) had altogether new findings, while 12 (25%) had new findings in addition to previous findings. USG showed 50% efficacy in diagnosing CAP. In all 48 patients X-ray abdomen (erect view) and X-ray chest was done. In 4 patients few dilated bowel loops were seen; followed by minimal right pleural effusion in 3, minimal bilateral effusion in 2 and both effusion with dilated bowel loops in 2 patients. No major/gross finding was seen in X-ray.

CT of abdomen was done in 11(22.9%) patients. 10(20.8%) patients showed pathological findings (ascitis, mesenteric fat thickening, lymphadenopathy, multiloculated collection, GB mass, Dilated bowel loops, pleural effusion, bowel thickening) in CT while, one CT was normal. In 5 patients CT showed change in findings when compared with the findings on ultrasonography. CT scan was better to suggest dilatation of gut loops and retroperitoneal/mesenteric lymphadenopathy. From the above table it is evident that in majority of the patients 30 (62.5%), 3 ports were used during surgery; followed by 2 ports in 17 (35.42%) and 4 ports were used in one case.

**Table no-1 operative findings during laparoscopy**

<b>finding Operative</b>	<b>No. of patients(n=48 )</b>	<b>%</b>
<b>Abdominal Koch's</b>	17	35.42
<b>Chronic/ recurrent appendicitis</b>	11	22.91
<b>Post op adhesion</b>	7	14.58
<b>Malignancy</b>	3	6.25
<b>PID</b>	2	4.17
<b>Ovarian cyst (Endometriosis)</b>	2	4.17
<b>Chronic hepatitis</b>	1	2.08
<b>No abnormality detected</b>	5	10.42

Out of 48 patients with chronic abdominal pain 17 had findings suggestive of Koch's abdomen, 11 of chronic/ recurrent appendicitis, 7 of post op adhesion. 3 patients had findings suggestive of malignancy (2 had suspicion of GB fossa malignancy and 1 of colonic ca.), 2 cases of PID, 2 had ovarian cyst and one showed hepatic scar. 5 Patients had no abnormality detected during laparoscopy. Positive finding during diagnostic laparoscopy was seen in 43 (89.6%) patients.

**Table no- 2 operative procedure**

<b>Operative Procedure</b>	<b>Number of patients(n=48)</b>
<b>Tubercle/Omental/LN/suspicioustissue biopsy</b>	17
<b>Appendectomy (alone/with adhesiolysis)</b>	15
<b>Adhesiolysis (alone)</b>	7
<b>Ascitic fluid sampling (alone)</b>	4
<b>Excision of cyst</b>	1
<b>Diagnostic laparoscopy only</b>	4

Positive finding during diagnostic laparoscopy was seen in 43 (89.6%) patients. After correlating clinical and radiological findings and findings of diagnostic laparoscopy, abdominal Koch was the most common diagnosis in our study in 17 (35.42%) patients, followed by chronic/recurrent appendicitis in 14 (29.2%), post- operative adhesion in 7 (14.58%), malignancy with metastasis in 3 (60.25%), and PID and ovarian cyst in 2 (4.16%) each. Two patients had no abnormality detected during laparoscopy, and histopathology report was also negative. Only 3 patients had post-operative complications, fever (2) and surgical site infection (1). No major complications were observed.



Complications were managed conservatively and patients recovered well. Of 48 patients, 3 had discontinued follow-up (they were referred for adjuvant therapy). Of remaining 45,38 (84.4%) patients had shown resolution of pain during follow-up. No change was seen in 7 (15.6%) cases after laparoscopy.

**Discussion-** Chronic abdominal pain is among the most challenging and demanding conditions to treat across the whole age spectrum. Clinical symptoms and signs are usually insufficient, ambiguous, and often misleading for a conclusive diagnosis in these patients. After ruling out common diseases by careful investigations, many patients are still undiagnosed and represent a major diagnostic challenge to the surgeon.<sup>[1]</sup> The most common organic conditions include intestinal adhesions,<sup>[2,3]</sup> appendicular,<sup>[4]</sup> and biliary causes,<sup>[5,6]</sup> while functional conditions include irritable bowel disease,<sup>[7]</sup> functional dyspepsia,<sup>[8]</sup> and various motility disorders.<sup>[9]</sup> Abdominal wall pain is also common and frequently mistaken for visceral pain.<sup>[10,11]</sup>

Diagnostic laparoscopy makes it possible for the surgeon to visualize surface anatomy of intra-abdominal organs with greater details better than any other imaging modality. However, laparoscopy has got its own limitations such as non-visualization of deep parenchymal organs, processes of retroperitoneal space, and the inner surface of hollow organs and not allowing the surgeon to palpate the organs.<sup>[12]</sup> All patients included in this study had chronic abdominal pain, and they were subjected to laparoscopic evaluation after exclusion of all organic causes of the pain by detailed history, complete clinical examination, laboratory tests, and radiographic evaluations.

The study confirmed that in this difficult patient group, laparoscopy could safely identify abnormal findings and can improve the outcome in a majority of cases. The subjective benefit of laparoscopy for both the operating surgeons and the patient is the definitive answer that if no serious pathology is found intra-abdominally, the placebo effect of laparoscopy may explain at least partly the patient pain relief.<sup>[13]</sup> Based on the findings of above study, it is also clear that early diagnostic laparoscopy can prevent the delay in the arrival at a definite diagnosis and institution of appropriate treatment.

The common causes of chronic abdominal pain were abdominal tuberculosis, chronic appendicitis, gynecological pathology, bands, adhesions, and abdominal malignancy in our study. In many developing countries including India, infectious disease such as tuberculosis is a more common cause of chronic abdominal pain than cancer.

In our study, 18 patients had normal USG finding. Of 30 (62.5%) patients with positive USG findings, 12 (25%) patients had similar findings during laparoscopy, 6 (12.5%) had altogether new findings, while 12 (25%) had new findings in addition to previous findings. USG showed 50% efficacy in diagnosing chronic abdominal pain. Thus, diagnostic laparoscopy clearly scores above the imaging studies in picking up tubercles, nodules, minimal ascites, bands, and adhesion. In our study, abdominal Koch's was the most common finding 17 (35.45%), followed by chronic/recurrent appendicitis 11 (22.91%), and is comparable to the study by Tulaskar *et al.*,<sup>[13]</sup> Rathod *et al.*,<sup>[14]</sup> Lal,<sup>[15]</sup> and Saxena.<sup>[16]</sup>

In our study, besides laparoscopy and biopsies, therapeutic surgeries were performed laparoscopically in 23 patients. In patients diagnosed as abdominal Koch's and suspected of malignancy, biopsy was taken, while in 15 patients, appendectomy was done. It is comparable to the study by Rathod *et al.*,<sup>[14]</sup> Chaphekar *et al.*,<sup>[17]</sup> Saxena,<sup>[16]</sup> and Chao *et al.*<sup>[18]</sup> in his study concluded that diagnostic laparoscopy is worthwhile for patients with chronic right iliac fossa pain and concurrent appendectomy should be considered in young patients with episodic, well localized symptoms associated with systemic malaise.



In the present study, no cases required conversion to laparotomy for therapeutic management. Salky and Edey<sup>[19]</sup> reported no conversion rates. Raymond *et al.*<sup>[20]</sup> in their study of patients with chronic abdominal pain showed no conversion rate to laparotomy. Klingensmith *et al.*<sup>[21]</sup> in their study reported no conversion rate. Of a total of 48 patients of chronic abdominal pain, positive diagnosis was made in 46 (95.83%) patients in our study and is comparable to the study by Arya *et al.*,<sup>[22]</sup> Karvande *et al.*,<sup>[23]</sup> Paajanen *et al.*,<sup>[24]</sup> and Saxena.<sup>[16]</sup> In our study, 38 (84.4%) patients had shown resolution of pain during follow-up after laparoscopy. It is comparable to the study by Kumar *et al.*<sup>[25]</sup> and Chaphekar *et al.*<sup>[17]</sup>

There were no major laparoscopy or anesthesia-related complications. Most of patients were discharged in a 2–6 days. Morbidity was 6.25% and there was no mortality. Finding no abnormal pathology on laparoscopic exploration is also considered a useful outcome, as this provides reassurance to the patient and avoids further costly investigations and treatment, as this provides reassurance to the patients and avoids further costly investigations and treatment. Thus, this study highlights the positive role of laparoscopy in patients of chronic non-specific abdominal pain.

**Conclusion-** In many patients presenting with chronic abdominal pain, even battery of investigations fail to confirm any diagnosis. Many patients remain undiagnosed for prolong periods because conclusive diagnosis largely depends on direct visualization of abdominal viscera, histology, and further evaluation of ascitic fluid, which requires invasive intervention in the form of laparoscopy or laparotomy. A delay results in progression of the underlying disease, prolonged morbidity and complications. It not only results in inevitable emergency abdominal surgery but also is associated with morbidity and mortality. The lack of accurate diagnosis leads to undesirable burden of human sufferings and wastage of resources. A conclusive diagnosis by direct visualization with the help of laparoscopy along with histology, culture, or ascitic fluid studies is becoming a necessity in the present-day scenario for initiation of treatment in patients of chronic non-specific abdominal pain. Early diagnosis with the help of laparoscopy allows a prompt treatment to be initiated with advantages for the patients and savings to health-care system. Our study establishes the role of diagnostic laparoscopy as a safe and useful adjunct to other diagnostic modalities in management of chronic abdominal pain.

#### References-

1. Galili O, Shaoul R, Mogilner J. Treatment of chronic recurrent abdominal pain: Laparoscopy or hypnosis? *J Laparoendosc Adv Surg Tech A* 2009;19:93-6.
2. Peters AA, Van den Tillaart SA. The difficult patient in gastroenterology: Chronic pelvic pain, adhesions, and sub occlusive episodes. *Best Pract Res Clin Gastroenterol* 2007;21:445-63.
3. Van Goor H. Consequences and complications of peritoneal adhesions. *Colorectal Dis* 2007;9:25-34.
4. Fayed JA, Toy NJ, Flanagan TM. The appendix as the cause of chronic lower abdominal pain. *Am J Obstet Gynecol* 1995;172:122-3.
5. Dumont RC, Caniano DA. Hypokinetic gallbladder disease: A cause of chronic abdominal pain in children and adolescents. *J Pediatr Surg* 1999;34:858-61.
6. Johnson CD. ABC of the upper gastrointestinal tract. Upper abdominal pain: Gall bladder. *BMJ* 2001;323:1170-3.
7. Mertz HR. Irritable bowel syndrome. *N Engl J Med* 2003;349:2136-46.
8. Tack J, Lee KJ. Pathophysiology and treatment of functional dyspepsia. *J Clin Gastroenterol* 2005;39:S211-6.
9. Abell TL, Werkman RF. Gastrointestinal motility disorders. *Am Fam Physician* 1996;53:895-902.
10. Lindsetmo RO, Stulberg J. Chronic abdominal wall pain a diagnostic challenge for the surgeon. *Am J Surg* 2009;198:129-34.

11. Costanza CD, Longstreth GF, Liu AL. Chronic abdominal wall pain: Clinical features, health care costs, and longterm outcome. *Clin Gastroenterol Hepatol* 2004;2:395-9.
12. Von Korff M, Dworkin SF, Le Resche L, Kruger A. An epidemiologic comparison of pain complaints. *Pain* 1988;32:173-83.
13. Tulaskar N, Nichkode P, Dasgupta S, Choudhary A, Zamad R, Panchbhai K, *et al.* Evaluation of role of laparoscopy in chronic abdominal pain. *Int J Bio Med Res* 2013;4:3230-3.
14. Rathod P, Gujar N, Hosmani I, Sachin DM. Study to evaluate the role of laparoscopy in chronic abdominal pain. *Int J Curr Res* 2014;6:6376-9.
15. Kumar S. To study the efficacy of diagnostic laparoscopy in chronic abdominal pain. *J Evid Based Med Healthcare* 2014;1:1771-87.
16. Saxena P. The role of laparoscopy in diagnosis of patients with chronic abdominal pain. *Int Surg J* 2017;4:326-33.
17. Chaphekar AP, Vankipuram S, Nawalkar PR, Sutar SA, Devlekar SM. Does laparoscopy have a role in chronic abdominal pain? *Int J Contemp Med Res* 2016;3:2582-5.
18. Chao K, Farrell S, Kerdemelidis P, Tulloh B. Diagnostic laparoscopy for chronic right iliac fossa pain: A pilot study. *Aust N Z J Surg* 1997;67:789-91.
19. Salky BA, Edye MB. The role of laparoscopy in the diagnosis and treatment of abdominal pain syndromes. *Surg Endosc* 1998;12:911-4.
20. Nar AS, Bawa A, Mishra A, Mittal A. Role of diagnostic laparoscopy in chronic abdominal conditions with uncertain diagnosis. *Niger J Surg* 2014;20:75-8.
21. Klingensmith ME, Soybel DI, Brooks DC. Laparoscopy for chronic abdominal pain. *Surg Endosc* 1996;10:1085-7.
22. Arya PK, Gaur KJ. Laparoscopy, A tool in diagnosis of lower abdominal pain. *Indian J Surg* 2004;66:216-20.
23. Karvande R, Kamble R, Kharade M. A study of role of diagnostic and therapeutic laparoscopy in chronic and recurrent abdominal pain. *Int Surg J* 2016;3:1336-40.
24. Paajanen H, Pulkunen K, Waris H. Laparoscopy in chronic abdominal pain. *J Clin Gastroenterol* 2005;39:110-4.
25. Kumar A, Sarwar MY, Pandey NK. Role of diagnostic laparoscopy in nonspecific chronic abdominal pain: Experience of 100 cases. *J Evol Med Dent Sci* 2013;2:9361-6