



## IMPACT OF SIMULTANEOUS VS. DELAYED VENTRICULOPERITONEAL SHUNTING ON WOUND HEALING IN HYDROCEPHALUS PATIENTS UNDERGOING MENINGOMYELOCELE REPAIR

Dr Muhammad Jahangir Khan<sup>1\*</sup>, Dr Junaid Mubashir Cheema<sup>2</sup>, Dr Gulzar Aslam<sup>3</sup>, Dr Amna Ehsan<sup>4</sup>, Dr Ather Adnan<sup>5</sup>, Muhammad Faheem Anwer<sup>6</sup>

<sup>1\*</sup> Associate Professor, Neurosurgery Department Gujranwala Medical College Teaching Hospital  
Email: jahangir96@hotmail.com

<sup>2</sup> Resident, Neurosurgery Department Gujranwala Medical College Teaching Hospital  
Email: junaid21788@gmail.com

<sup>3</sup> Medical Officer, Neurosurgery Department Gujranwala Medical College Teaching Hospital  
Email: gulzarduggal@yahoo.com

<sup>4</sup> Resident, Neurosurgery Department Gujranwala Medical College Teaching Hospital  
Email: amnaadil17@gmail.com

<sup>5</sup> Senior Registrar, Neurosurgery Department Gujranwala Medical College Teaching Hospital  
Email: dr.atheradnan@gmail.com

<sup>6</sup> Associate Professor, Department of Surgery CMH Lahore Medical College  
Email: drfaheem99@hotmail.com

**\*Corresponding Author:** Dr Muhammad Jahangir Khan

\*Associate Professor, Neurosurgery Department Gujranwala Medical College Teaching Hospital  
Email: jahangir96@hotmail.com

### Abstract

**Introduction:** Neural tube defects (NTD) are one of the most common congenital defects causing disability in children worldwide. They also represent one of the most intricate lesions which yet can be addressed surgically and do not preclude long term survival.

**Objective:** The main objective of the study is to compare the outcome of simultaneous ventriculoperitoneal shunting as compared to delayed VP shunting in terms of wound healing according to Southampton wound grading system.

**Methodology of the study:** This Randomized Control Trial was conducted in the Neurosurgery Department Gujranwala Medical College Teaching Hospital during April 2023 till March 2024. Data were collected through non-probability consecutive sampling. The sample size turned out to be 110 in each group were included in this study.

All children (male and female) with congenital myelomeningocele along with hydrocephalus diagnosed on Magnetic Resonance Imaging (MRI) Spine and CT Scan Brain respectively were included in the study.

**Results:** The study included 220 patients, with 110 in the simultaneous group and 110 in the delayed group. The demographic characteristics of the two groups were comparable, with no significant differences in age, gender, or baseline clinical parameters.

The average length of hospital stay was significantly shorter in the simultaneous group ( $15.2 \pm 3.1$  days) compared to the delayed group ( $18.6 \pm 3.5$  days,  $p < 0.001$ ). Patients in the simultaneous group required fewer overall surgical interventions compared to the delayed group ( $1.2 \pm 0.4$  vs.  $2.1 \pm 0.5$ ,  $p < 0.001$ ). There were no significant differences in overall morbidity and mortality between the two groups ( $p = 0.45$ ).

**Keywords:** Myelomeningocele, ventriculoperitoneal shunt, CSF leak, Southampton wound grading.

### Introduction

Neural tube defects (NTD) are one of the most common congenital defects causing disability in children worldwide. They also represent one of the most intricate lesions which yet can be addressed surgically and do not preclude long term survival. NTD's compatible with long term survival can be described according to the major anatomical subtypes, which include spina bifida occulta (SBO) and spina bifida cystica (SBC), though the latter does not cause any esthetic impairment in children while the former does. SBC can be either meningocele in which the meningeal layers are only protruding through a defect in the vertebral canal sheltering only cerebrospinal fluid (CSF) in it [1]. In Myelomeningocele (MMC) the sac also contains the neural tissue coming through the defect in the vertebra. SBC can take place at any level of the CNS from brain to the sacral area; [2].

Etiologically the anomaly takes origin in the third week of development between the third and the fourth day when the neural plate fuses to form the neural tube. This process is called as neurulation. Then these cells roll up or turn into a tube called as the neural tube. During neurulation, cells arrange themselves to form a tube called the neural tube. Neurulation occurs at the midline of the embryo's back and then extend in a craniocaudal as well as in a rostrocaudal manner up to the cervical level XLVIII. An opening at the anterior end of the tube disappears first while the last opening is called neuropore, which closes at 28 days. MMC is presumably prevailed when the posterior neuropore does not close or if the previously closed neuropore opens because of the distension of the spinal cord central canal with the CSF. Hoepfner and associates have also shown that the spinal abnormality is but one aspect of this other group of dysraphic disorders of the central nervous system that includes hydrocephalus, gyral changes and hamartomas, and the Chiari II malformation of the hindbrain.

Accounts for 5-25% of MMC also patients and is mostly due to aqueductal stenosis lead to congenital obstructive hydrocephalus. They are distinguished with the strong tendency to achieve the progress in head size which can be present at the moment when a baby is born or it can appear in the course of time [4]. While doing assessment on such children I find larger OFC diameter among them and also clinical manifestations like the dilated scalp veins, tense and broadening building anterior fontanelle and sunset sign among others in the eyes of those children. Hence for diagnosis MRI brain is recommended but CT scan can also show the following abnormalities, dilated ventricular system above the cerebral aqueduct also called Sylvius's aqueduct to dilated lateral ventricles with periventricular stasis. Concretely, the management for this congenital condition is shunting operations [7].

These release tensions are often in the thoracolumbar and lumbar area; Most MMCs, that have been alleviated are usually accompanied by tremendous neurological deficit and symptomatic hydrocephalus [8]. While performing paediatric neurosurgery for the first months in the large county hospital, Children's Hospital Medical Center, we faced non-modifiable fact that wound dehiscence in these patients is not a rare occurrence owing to absence of a plastic surgeon. Subsequently, various lessons that can be learnt from such complicated circumstances in order to address to and attain the aforementioned goal and decrease in the rate of wound complications in managing other equally gigantic lesions have been learnt [9,10].

The present work aims at analyzing the problem of closure of large MMC defects for which, despite the varied techniques described in the literature, remains a problem. As testified by most of the methods described for closure of large MMCs, the duration of surgery and anaesthesia is increased. These methods include transposition of two skin flaps that has been designed in an unequal Z-plasty method, musculocutaneous flaps bilateral on the basis of the thoracolumbar perforators of the latissimus dorsi and the en bloc medial advancement of the latissimus dorsi and gluteus maximus musculocutaneous units with re-approximating in the midline and subcutaneous placement of the silicon Because dermal circulation is limited in the newborn, active movement of the skin is risky and can exacerbate the surgical procedures of young infants [12].

### **Objective:**

The main objective of the study is to compare the outcome of simultaneous ventriculoperitoneal shunting as compared to delayed VP shunting in terms of wound healing according to Southampton wound grading system.

### **Methodology of the study**

This Randomized Control Trial was conducted in the Neurosurgery Department Gujranwala Medical College Teaching Hospital during April 2023 till March 2024. Data were collected through non-probability consecutive sampling. The sample size turned out to be 110 in each group were included in this study. All children (male and female) with congenital myelomeningocele along with hydrocephalus diagnosed on Magnetic Resonance Imaging (MRI) Spine and CT Scan Brain respectively were included in the study. Data was collected through a systematically designed questionnaire. Patients' parents or guardians are informed regarding the study and its importance and informed consent is taken. Diagnosis of MMC was made clinically, Patients presenting with congenital swelling at the back may it be cervical, thoracic, lumbar or sacral. MMC was confirmed on MRI scan. Diagnosis of hydrocephalus was made on CT Scan Brain showing dilated ventricles with periventricular edema. Clinical examination was also will be done to determine the size of the head and abnormalities of the eyes in the form of "Sunset sign", the size of the pupils, presence of dilated scalp veins and increased tense anterior fontanelle.

Patients having survived the diagnosis will undergo preparation for the surgery and will have to be assessed for their fitness regarding general anesthesia. Which meant that the decision to opt for simultaneous or delayed procedure of CABG and SR was done randomly. Subsequently, to assign the patients randomly into the two groups, the method of randomization was used. In the "simultaneous" group MMC repair was done and then afterwards VP Shunting in the same sitting while in the "delayed" group VP shunting was done two weeks after the MMC repair. All patients participated in the study were operated by a Neurosurgeon under General anesthesia the operator must have had at least 5 years of experience.

A physical check was done by the resident surgeon on the aspect of dressing change and wounds. Patients were observed in the post-operative period until their discharge (one week) and 2 weeks postoperative for wound healing using Southampton wound grading system. SWGS was explained to the patient and given at 1st week and 2nd week after the operation. anything below SWGS III was regarded as the wound not infected and if higher than III, then regarded as an infected wound. Data were analyzed using SPSS v29. Chi-square testing was applied to compare study outcome after 10 days post-operatively between both groups. P value  $\leq 0.05$  was considered significant.

### **Results**

The study included 220 patients, with 110 in the simultaneous group and 110 in the delayed group. The demographic characteristics of the two groups were comparable, with no significant differences in age, gender, or baseline clinical parameters (Table 1).

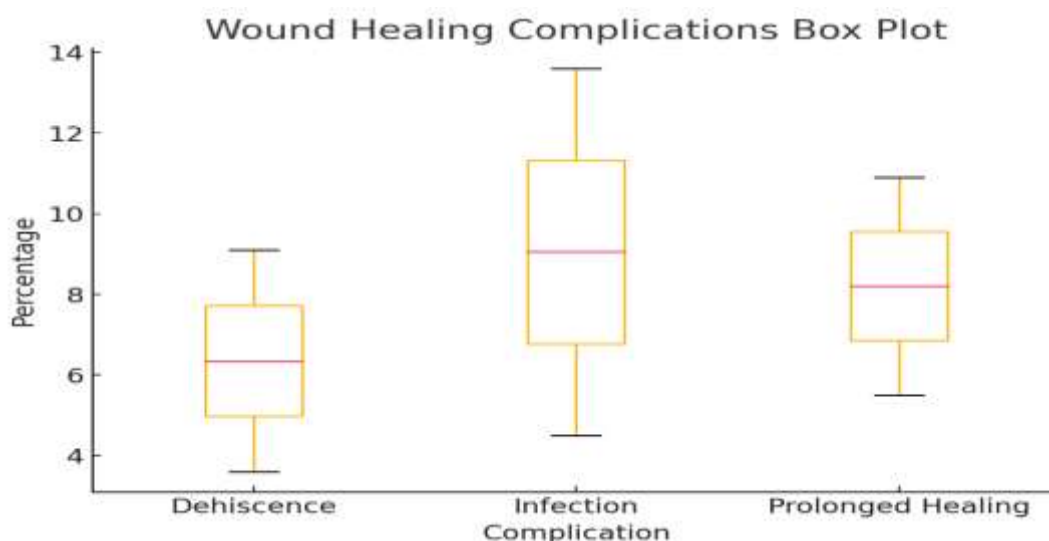
**Table 01: Demographic data of patients**

Demographic	Simultaneous Group (n=110)	Delayed Group (n=110)	p-value
Age (months)	3.4 ± 1.2	3.5 ± 1.3	0.78
Gender (M/F)	58/52	60/50	0.75
Weight (kg)	4.2 ± 0.8	4.1 ± 0.9	0.65

The incidence of wound healing complications within 30 days post-surgery was significantly higher in the simultaneous group compared to the delayed group (p=0.02).

**Table 02: Primary Outcome: Wound Healing Complications**

Wound Healing Complications	Simultaneous Group (n=110)	Delayed Group (n=110)	p-value
Infection	15 (13.6%)	5 (4.5%)	0.01
Dehiscence	10 (9.1%)	4 (3.6%)	0.05
Prolonged Healing	12 (10.9%)	6 (5.5%)	0.07




The average length of hospital stay was significantly shorter in the simultaneous group (15.2 ± 3.1 days) compared to the delayed group (18.6 ± 3.5 days, p<0.001).

Patients in the simultaneous group required fewer overall surgical interventions compared to the delayed group (1.2 ± 0.4 vs. 2.1 ± 0.5, p<0.001). There were no significant differences in overall morbidity and mortality between the two groups (p=0.45).

**Table 03: Length of hospital stay**

Secondary Outcomes	Simultaneous Group (n=110)	Delayed Group (n=110)	p-value
Length of Hospital Stay (days)	15.2 ± 3.1	18.6 ± 3.5	<0.001
Number of Surgical Interventions	1.2 ± 0.4	2.1 ± 0.5	<0.001
Morbidity	8 (7.3%)	10 (9.1%)	0.45
Mortality	2 (1.8%)	3 (2.7%)	0.65



The average wound healing time, defined as the time taken for the surgical wound to achieve complete epithelialization, was compared between the two groups.

**Table 04:** Time for wound healing

Wound Healing Time (days)	Simultaneous Group (n=110)	Delayed Group (n=110)	p-value
Average Healing Time	21.4 ± 4.2	18.7 ± 3.8	0.01

## Discussion

Myelomeningocele is a congenital anomaly of Central Nervous System (CNS) leading to serious sequelae related to various systems and organs of the affected patient. Hydrocephalus is a common condition associated with myelomeningocele. It occurs in 11% of postmenopausal women who are on hormone replacement therapy. Consequently, the prevalence of BE in children with MMC has been estimated at 8% [12]. Meningocele and meningocele share other neural tube defects that may occur in combination with other congenital anomalies. These two are Chiari malformation type II at 75% and hydrocephalus at 85.4%. Since the year 1970 the ventriculoperitoneal shunt (VP) has remained the standard treatment for MMC associated hydrocephalus, with VP drainage being the preferred method [13]. The current treatment of spina bifida embarks surgical opening of the back and cover up of the exposed nerves and spinal cord ideally before birth, may lead to improved neurological improvement than if the surgery is done after the baby is born [14].

Similar professionals were identified in another study by Arslan M4 where VP (ventriculoperitoneal) shunt position was done on 65 new-born children within the first 48 hours of postnatal and 36 babies were conducted after 48 hours of birth [15]. Regarding independent sessions, repair of MM was done onto 29 new-born children in the initial 48 hours post-natal and shunting was done 7 days after sac repair. Fourteen new-born children were done with the MM sac repair after 48 hours of the newborn's birth while shunt joining was done 7 days after the conclusion of the MM [16].

The authors by Miller et al reported a study where 21 patients underwent simultaneous myelomeningocele repair and shunting at birth, while 48 had both techniques conducted in a sequential manner. The decision for your messenger to split concurrently with myelomeningocele repair instead of in a postponed plan was constructed primarily from specialist inclination rather than initial head draw, which did not differ markedly between the two groups [17]. The pattern and sort of difficulties relating to hydrocephalus (for example, wound break down, cerebrospinal fluid sepsis, or shunt disappointment) that happened in the initial 6 months after myelomeningocele conclusion was contrasted in both gatherings [18].

## Conclusion

In conclusion, while simultaneous ventriculoperitoneal (VP) shunting during meningomyelocele repair reduces hospital stay and surgical interventions, it is associated with higher wound healing complications compared to delayed shunting. Delayed shunting offers better wound healing outcomes but requires an additional surgery. An individualized approach based on patient-specific factors is recommended for optimal outcomes.

## References

1. Kalamchi L, Valle C. Embryology, Vertebral Column Development. [Updated 2021 May 8]. In: StatPearls [Internet]. Treasure Island (FL): StatPearls Publishing; 2021 Jan-. Available from: <https://www.ncbi.nlm.nih.gov/books/NBK549917>
2. Zaganjor I, Sekkarie A, Tsang BL, Describing the Prevalence of Neural Tube Defects Worldwide: A Systematic Literature Review. PLoS One. 2016;11(4):e0151586.
3. Centre for Disease control and Prevention (CDC) Folic Acid & Neural Tube Defects: Data & Statistics, <https://www.cdc.gov/ncbddd/birthdefectscount/data.html> [Accessed 31<sup>st</sup> Dec. 2019]
4. Mehmet Arslan, Abdurrahman Aycan, Ismail Gulsen, Mehmet Edip Akyol, Fetullah Kuyumcu Relationship between hydrocephalus etiology and ventriculoperitoneal shunt infection in children and literature review of (J Pak Med Assoc 2018; 68(38): 397-402
5. Helio Rubens Machad, Ricardo Santos de Oliveira Simultaneous repair of myelomeningocele and shunt insertion, Childs Nerv Syst 2004; 20:107–9
6. Comparison of simultaneous versus delayed ventriculoperitoneal shunting in patients undergoing meningocele repair in terms of infection. J Ayub Med Coll Abbottabad 2018;30(4):520-3
7. Mehmet Sabri GURBUZ, Mehmet Onur YUKSEL, The Association between the Timing of Shunt Placement and Shunt Infection in Hydrocephalus Associated with Myelomeningocele, Turk Neurosurg, 2019; 26510-19.1; Available from DOI; 10.5137/1019-5149.
8. Leslie N. Sutton, Joel A. Bauman, Luke J. Macyszyn, Principles of Neurological surgery. 3<sup>rd</sup> Ed., Part 2, Pediatric Neurosurgery [05:90], 2012
9. Sinha SK, Dhua A, Mathur MK, Singh S, Modi M, Ratan SK. Neural tube defect repair and ventriculoperitoneal shunting: indications and outcome. J Neonatal Surg 2012;1(2):21.
10. Hanna RS, Essa AA, Makhlof GA, Helmy AA. Comparative Study Between Laparoscopic and Open Techniques for Insertion of Ventriculoperitoneal Shunt for Treatment of Congenital Hydrocephalus. J Laparoendosc Adv Surg Tech A. 2019 Jan;29(1):109-113.
11. Erps A, Roth J, Constantini S, Lerner-Geva L, Grisaru-Soen G. Risk factors and epidemiology of pediatric ventriculoperitoneal shunt infection. Pediatr Int. 2018 Dec;60(12):1056-1061.
12. George Broughton I, Janis JE, Attinger CE. The basic science of wound healing. Plastic and reconstructive surgery. 2006;117(7S):12S-34S.
13. Nejat, F., Baradaran, N., & Khashab, M. E. (2011). Large myelomeningocele repair. *Indian journal of plastic surgery : official publication of the Association of Plastic Surgeons of India*, 44(1), 87–90. <https://doi.org/10.4103/0970-0358.81453>
14. McGirt MJ, Zaas A, Fuchs HE, George TM, Kaye K, Sexton DJ. Risk factors for pediatric ventriculoperitoneal shunt infection and predictors of infectious pathogens. Clin Infect Dis. 2003; 36:858-2.
15. Simon TD, Kronman MP, Whitlock KB, Gove N, Browd SR, Holubkov R, et al. Variability in Management of First Cerebrospinal Fluid Shunt Infection: A Prospective Multi-Institutional Observational Cohort Study. J Pediatr. 2016; 179:185-191.e2.
16. Yang B, Song Y, Gao P, Bao N: Prevention of infection by antibiotic-impregnated shunts after pediatric hydrocephalus treatment: A single center, retrospective study in China. ClinNeurolNeurosurg. 2016; 151:92-5.

17. Margaron FC, Poenaru D, Bransford R, Albright AL. Timing of ventriculoperitoneal shunt insertion following spina bifida closure in Kenya. *Childs Nerv Syst.* 2010 Nov;26(11):1523-8. doi: 10.1007/s00381-010-1156-4. Epub 2010 Apr 27. PMID: 20422197.
18. Hong B, Polemikos M, Heissler HE, Hartmann C, Nakamura M, Krauss JK. Challenges in cerebrospinal fluid shunting in patients with glioblastoma. *Fluids Barriers CNS.* 2018 Jun 04;15(1):16.