



## OPTIMIZING MATERNAL-FETAL HEALTH: APPROACHES TO ACUTE APPENDICITIS DURING PREGNANCY

Dr. Durre Shahwar<sup>1\*</sup>, Mufaddal Ammar Hussain<sup>2</sup>, Ayesha Erum Hadi<sup>3</sup>, Ummyia Faisal<sup>4</sup>, Shahd Tag Elsir Eltom Abdalla<sup>5</sup>, Ayodele-Ale Oluwajomiloju Precious<sup>6</sup>, Yaseen Khan<sup>7</sup>

- <sup>1\*</sup>Senior Registrar, Department of Gynaecology and Obstetrics, Niazi Medical and Dental College, Sargodha, Pakistan, Email: durreshahwar808@gmail.com  
<sup>2</sup>MBBS, Department of Internal Medicine, Indian, Email: muffa\_97@hotmail.com  
<sup>3</sup>Junior resident, Dr. D.Y Patil Medical College, Hospital and Research Centre, Pune Department of Diagnostic Radiology, India, Email: ayesahadi@hotmail.com  
<sup>4</sup>MBBS, Multan Medical and Dental College, Pakistan, Email: ummiyafaisal1@gmail.com  
<sup>5</sup>Faculty of Medicine, Department of Obstetrics and Gynecology, University of Khartoum, Sudan, Email: shahd.altaaj@gmail.com  
<sup>6</sup>Student, Department of Medicine, V.N Karazin Kharkiv National University, Ukraine, Email: Jomiloju99@gmail.com  
<sup>7</sup>Medical Officer, Khalifa Gul Nawaz Teachig Hospital, Bannu, Pakistan, Email: yaaceenkhan47@gmail.com

**\*Corresponding Author:** Dr. Durre Shahwar

\*Senior Registrar, Department of Gynaecology and Obstetrics, Niazi Medical and Dental College, Sargodha, Pakistan, Email: durreshahwar808@gmail.com

### ABSTRACT:

**Background:** Acute appendicitis is the most common cause of acute surgical abdomen during pregnancy. However, the anatomical and physiological changes occurring during pregnancy often obscure its clinical presentation, posing challenges for diagnosis and management.

**Methods:** This structured review examines the diagnostic and management strategies for acute appendicitis in pregnant women. Relevant literature was identified through a comprehensive search of electronic databases.

**Results:** Diagnostic uncertainty necessitates a prompt and comprehensive approach, integrating clinical evaluation, laboratory tests, and imaging examinations. Appendectomy remains the gold standard treatment, with options including open or laparoscopic procedures. Early diagnosis and intervention are critical for reducing maternal-fetal morbidity and mortality.

**Conclusion:** Acute appendicitis in pregnancy requires heightened clinical suspicion and a multidisciplinary approach. Timely diagnosis and appropriate management strategies are paramount to optimizing outcomes for both the mother and fetus.

**Keywords:** laparoscopy; acute abdomen; pregnancy; appendicitis; diagnosis.

### INTRODUCTION:

Known as inflammation of the vermiform appendix, acute appendicitis is the most common nonobstetric surgical cause of pregnancy (1 in 500–1000 cases). The following surgical causes during pregnancy are listed in order of frequency: pancreatitis, cholecystitis, and abdominal

blockage. Nowadays, the diagnosis is made using vital signs, blood tests, and physical examinations; nevertheless, because of the unique physiological and anatomical changes that happen during pregnancy, which can hide the pathology, this can be difficult in many cases. One illustration of this is when uterine development makes it harder to perform the abdominal exam (Ashbrook et al., 2022).

Images are frequently used to support the diagnosis because as it gets bigger, it starts to compress and alter the distribution of the surrounding abdominal organs, making it harder to pinpoint the location of the pain. In order to improve the impact on maternal-fetal morbidity and mortality, the goal of this study is to conduct an updated assessment of the features of acute appendicitis in pregnancy as well as of the diagnostic and therapeutic tools now available (Choi et al., 2023 Şenocak et al., 2020).

**EPIDEMIOLOGY**

The most frequent cause of nonobstetric acute abdomen during pregnancy is appendicitis. An estimated 1 in 500–1000 occurrences are expected, with 40% of those cases occurring in the second trimester of pregnancy and in nulliparous women. Although there is no known risk factor for appendicitis during pregnancy, there is a correlation between pregnancy and a higher incidence of appendix perforation, which raises maternal morbidity and death. Fetal death rates are reported to be 20–37% in cases of perforated appendicitis and 1.5% in cases of uncomplicated appendicitis. These rates can rise by as much as 66% in response to delays in identification and treatment. Therefore, in addition to a 1.3 times increased risk of peritonitis, pregnant women with acute appendicitis also have a 2.68 times increased risk of placental abruption and preterm birth (Di Saverio et al., 2020).

**Table 1: Epidemiology of Acute Appendicitis in Pregnancy**

Parameter	Details
Frequency	1 in 500–1000 pregnancies
High-Risk Trimester	40% of cases occur in the second trimester
Risk Factors	No specific risk factors were noted, but a higher incidence of appendix perforation during pregnancy.
Complications	Increased risks of peritonitis, placental abruption, and preterm birth
Fetal Mortality Rate	20–37% in perforated appendicitis; 1.5% in non-perforated cases
Maternal Morbidity Rate	Increased due to delayed diagnosis and complications

**THE APPENDIX'S ANATOMY DURING PREGNANCY**

During pregnancy, physiological and anatomical changes take place that may alter the typical clinical presentation of acute appendicitis. The uterus will stay intrapelvic, and the appendix will remain in its natural anatomical position during the first trimester. The uterus becomes intra-abdominal as the pregnancy progresses, displacing multiple organs, including the appendix, which has a cranial displacement above McBurney's point during the first trimester; by the second trimester, the appendix is located on the right iliac crest; by the eighth month, it is located in the right subcostal region in 80% of cases. At term, the uterus shares a right-side border with the ascending colon, cecum, and appendix. These modifications may result in a delayed diagnosis, raising the possibility of a perforation (Vagholkar, 2020).

**Table 2: Anatomical Changes of the Appendix During Pregnancy**

Trimester	Position of Appendix
First	Remains in natural position, close to McBurney's point
Second	Moves to the right iliac crest
Third	Located in the right subcostal region in 80% of cases
At Term	Near the ascending colon, the cecum

**MEDICAL APPEARANCES**

The most typical symptom is crampy stomachache pain. It may be found on the left side as well as the right, just above McBurney's point in the first quarter. The right iliac fossa (McBurney's sign) has been the site of the pain in recent months, originally coming from the periumbilical region. Pain at this phase may be lessened as uterine expansion pushes the appendix and cecum upward. Psoas and Rovsing symptoms are not clinically significant since they may be decreased. The Adler maneuver, which is carried out with the patient in the supine position, can be used to differentiate between extrauterine and uterine pain. The patient is asked to turn onto her left side while the pain doctor applies pressure to the most painful area. It is extrauterine if the pain goes away or becomes less noticeable as you shift positions; intrauterine if it remains constant (Lapsa et al., 2021).

**Typical and Atypical Medical Appearances of Acute Appendicitis**

Symptom	Typical Presentation	Atypical Presentation
Pain Location	Initially periumbilical, later right iliac fossa; may vary due to displacement	
Pain Quality	Crampy stomach pain	Lower back pain, vaginal/rectal pain
Other Symptoms	Nausea (70-85%), Fever (~38°C in 50% cases)	Diarrhea, tenesmus, general malaise, dysuria

Seventy to eighty-five percent of women report experiencing nausea and vomiting. In these circumstances, though, the symptoms become nonspecific because they are common discomforts that patients have during pregnancy, particularly in the first trimester, and are therefore classified as abnormal. In 50% of instances, a fever (around 38°C) may be present. While most patients have a conventional clinical presentation, some present atypically with secondary symptoms such as tenesmus, diarrhea, gastritis, suprapubic discomfort, or general malaise when the appendix is retrocausal, the patient may have pain in the lower back, pain when instead of palpating the abdomen, perform a vaginal or rectal examination; associate nonspecific pain radiating to the right lower limb rather than localized discomfort; and occasionally associate urine symptoms like dysuria (Talan & Di Saverio, 2021).

**DIAGNOSTIC APPROACHES:**

Acute appendicitis is diagnosed clinically in both pregnant and non-pregnant patients; however, laboratory results and imaging studies are helpful in making this diagnosis. The most significant laboratory results were microscopic hematuria, modest elevations in bilirubin, increased protein C, and left-shifting leukocytosis (numbers exceeding 18,000 indicative of appendicitis) (Echevarria et al., 2023).

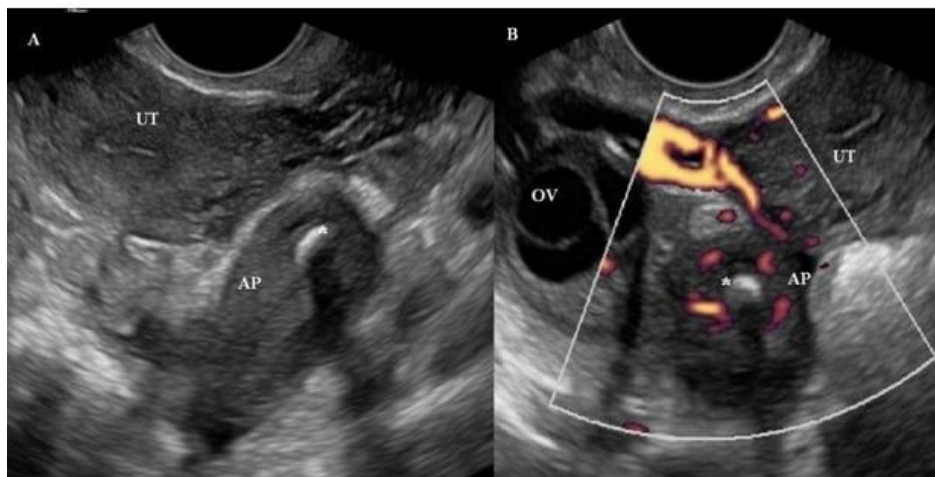
**Diagnostic Approaches for Acute Appendicitis in Pregnancy**

Modality	Details
Ultrasound	First-line; Sensitivity 30-83.7%, Specificity 92-95%, best before 16th week
MRI	High accuracy (Specificity 94-98.6%, Sensitivity 90.5-100%); recommended if US inconclusive
CT Scan	Sensitivity is 92%, and Specificity is up to 99%; it is used cautiously due to radiation risks.

**ULTRASOUND:**

The first radiological test performed on pregnant women who may have acute appendicitis is an ultrasound (US). Its Specificity can reach 92-95%, and its sensitivity ranges from 30-83.7%. Due to the size of the uterus, its effectiveness peaks at the beginning of the gestational age, particularly before the 16th week, and declines after the 32nd week. This approach is safe since it gathers

information about the fetus's condition without using ionizing radiation. A blind, echo lucent, more than 7 mm (figure 1) uncompressed tubular image in the right iliac fossa (which could be indicative of a dilated cecal appendix with wall edema) and target images (produced by calcified fecaliths within the cecal appendage) as well as enlarged mesenteric lymph nodes and free fluid will be the main ultrasonography findings of acute appendicitis (Heise et al., 2021).



**Figure 1:** 26-week gestational abdominopelvic ultrasonography during pregnancy

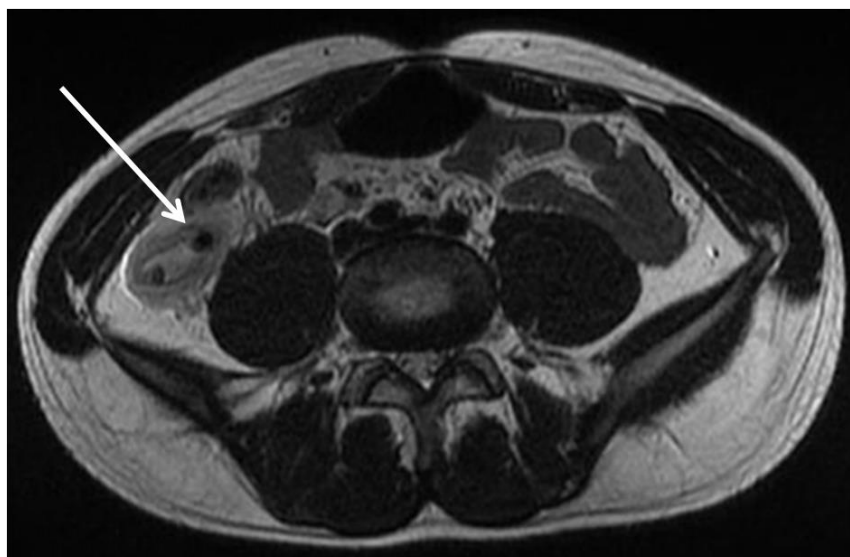
*Remark. Picture A: Acute appendicitis-related 9 mm noncompressible hypoechoic tubular structure. Image B shows a color Doppler that supports the appendicitis diagnosis (Monsonis et al., 2020).*

Even if the appendix is expected, the diagnosis shouldn't be ruled out unless the results point to something different. Though MRI is still the gold standard since it typically shows the appendix, the American College of Radiology advises using ultrasonography as the initial diagnostic tool for expectant mothers. In practical practice, MRI should only be used when ultrasonography is dubious (Arruzza et al., 2022).

Magnetic resonance of nuclear energy As previously indicated, magnetic resonance imaging (MRI) is a great diagnostic substitute in cases where ultrasound and clinical examination yield conflicting results. Its Specificity is 94-98.6%, and its sensitivity is 90.5-100%; yet, this is one study that did not. All health centers carry it. However, it is pricey and not usually well tolerated. The primary benefit of MRI is that, in 12% of cases, it can assist in finding different treatments for stomach pain without exposing the patient or the fetus to radiation. Similar to the ultrasound results, an MRI showing appendicitis will show a diameter of more than 7 mm, wall thickness greater than 2.5 mm, a strong signal on the T2 sequence (figure 2) because of intraluminal content, and hyperdensity of peripheral fat. Free fluid appendicular on T2 (Keven et al., 2023).

#### ***Ankle-level computerized tomography***

With a sensitivity of 92% and a specificity of up to 99%, computed axial tomography (CT) is the most effective tool for diagnosing acute appendicitis. However, it exposes the fetus and the pregnant woman to radiation, which is harmful because of the potential effects of teratogenesis and carcinogenesis, where the main risk factors are gestational age and radiation dose (Moris et al., 2021).



**Figure 2:** Appendicitis using nuclear magnetic resonance imaging

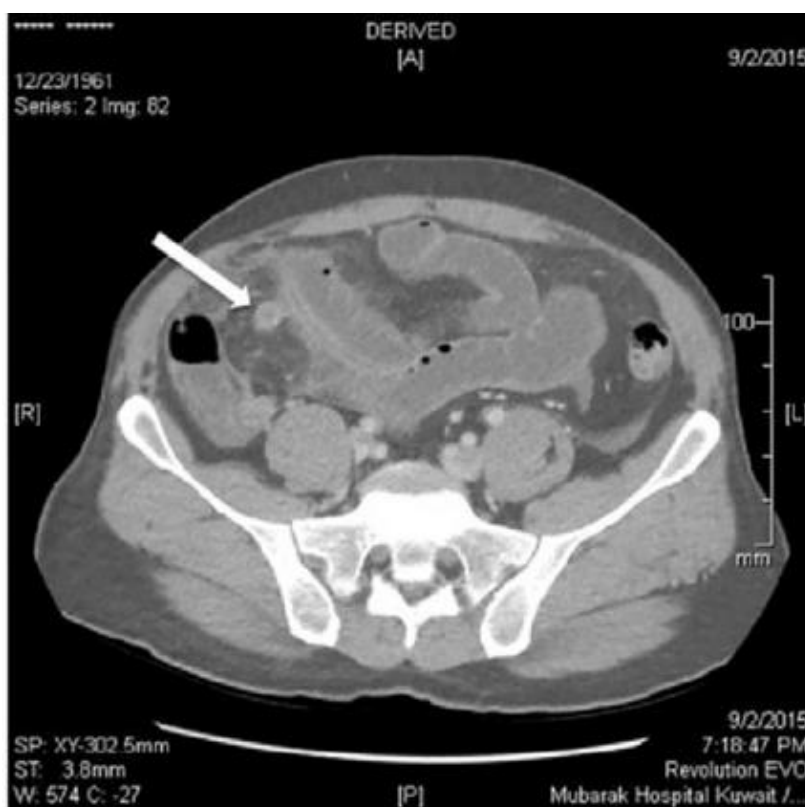*Remark. An acute case of appendicitis is seen in the axial T2 scan (arrow) (Krzyzak & Mulrooney, 2020).*

Since the danger of deformity increases at doses above 15 rad and the risk of teratogenesis is insignificant at doses of 5 rad or less, it is anticipated that the total radiation dosage acquired in the embryo during pregnancy should be less than 5 rad. In children, radiation may raise the risk of hematologic malignancies. Only in cases when MRI access is not possible at the health center (Figure 3), when clinical results are not unequivocal, or when an ultrasound is not definitively clear should CT be employed (Bom et al., 2021).

### **DISTINCTIVE DIAGNOSIS**

It is essential to rule out an ectopic pregnancy in all pregnant women experiencing stomach pain. A differential diagnosis will be conducted if the acute abdomen has other causes. Among the organizations that These should be thrown away (Peksöz et al., 2022):

- Intestinal: peptic ulcer, acute gastroenteritis, acute pancreatitis, acute appendicitis, and intestinal blockage.
- Urological: renal-ureteral colic brought on by urolithiasis, acute pyelonephritis, and urinary tract infection (Kirshtein et al., 2009).
- Vascular conditions include right ovarian vein syndrome, thromboembolic venous disease, thrombosis, and mesenteric infarction (Kirshtein et al., 2009; Yoo et al., 2016).
- Respiratory: pulmonary thromboembolism, right basal pneumonia.
- Obstetrics and gynecology: placenta percreta, abruptio placentae, ovarian torsion, septic abortion, uterine fibroid degeneration, HELLP syndrome, and chorioamnionitis.
- Other conditions include sickle cell anemia, diabetic ketoacidosis, splenic rupture, and abdominal trauma (Eom et al., 2012).



**Figure 3:** Appendicitis using nuclear-computed tomography

*Remark. The appendix is seen by arrows, along with surrounding peritoneal enlargement and streaks of appendicular fat (Bazdar et al., 2018).*

#### **DIRECTORY:**

The primary goal of managing acute appendicitis in pregnancy is to minimize the risks of maternal-fetal morbidity and mortality by assembling a multidisciplinary team that includes surgeons, obstetricians, anesthesiologists, and pediatricians (if needed). The laparoscopic procedure is the Gold Standard for treating acute appendicitis during pregnancy since it is safe for both the mother and the fetus and can be done in any trimester of pregnancy, according to research. This method has fewer side effects, faster recovery periods after surgery, smaller incisions, reduced incidence of surgical wound infection, and shorter hospital stays.

Using this approach, various abdominal and pelvic organs can be examined through the laparoscope in the event that an appendicitis false positive arises, helping to identify alternative reasons for pain (Ashbrook et al., 2022).

Additionally, minimal manipulation of the uterus during a laparoscopy lowers the risk of uterine irritation while giving the surgeon a wider field of view. When using this method, it's essential to take into account the port's original placement in order to determine the uterine fundus' height. In nonobstetric patients, the CO<sub>2</sub> used to create pneumoperitoneum is typically at pressure levels of 13-14 mmHg; in pregnant women, a gas pressure between 8–12 mmHg minimizes uterine hypoperfusion and consequences for the mother's lungs. In order to increase uteroplacental blood flow and lessen pressure on the inferior vena cava, the operating table should ideally be positioned laterally tilted to the left. This will assist in lowering the risk of fetal hypoxia (Kozan et al., 2020).

The third trimester is typically when the open procedure approach (laparotomy) is carried out (after 28 weeks). Because of the uterus's enlarged size and the potential for perforation during laparoscopic trocar (port) placement, which is why closed method management is advised during the first two trimesters, this approach was selected. In order to enable better access into the cecoappendicular region, the incision made during the laparotomy will vary depending on the gestational age. For example, the McBurney incision is made in the first trimester, and in the second

and third trimesters, it is made farther up on the right or in the upper midline. Although some authors report a significant frequency of preterm delivery (less than 37 weeks of gestation) and risk of fetal death with laparoscopy (6% vs. 3% with the open procedure), recent research shows that there is no difference between the laparoscopic and open approaches (Mantoglu et al., 2020; Yavuz et al., 2021).

The decision to convert from laparoscopic to open surgery during the procedure will be based on a number of criteria, including the doctor's Experience and past performance. Preoperative use of broad-spectrum antibiotics is advised in all patients of acute appendicitis to reduce the risk of postoperative septic complications. These medicines should cover both aerobic and anaerobic bacteria as well as Gram-positive and Gram-negative bacteria (Choi et al., 2023).

### CONCLUSION:

The most frequent nonobstetric surgical pathology that occurs during pregnancy is acute appendicitis. A thorough history and physical examination, along with laboratory testing and imaging, are necessary to obtain an accurate diagnosis since the physiological and anatomical changes that are typical of pregnancy can affect the clinical presentation and confound the diagnosis. Preterm delivery and appendix perforation are two potential risks that can be avoided with prompt detection and treatment before 24 hours. When there is uncertainty, MRI is the next diagnostic test for acute appendicitis, which is ultrasound in the first trimester of pregnancy in particular. Because of the radiation risks associated with CT, it is only utilized as a last resort. The method will always be surgical, involving both open and laparoscopic appendices. Based on the patient's traits, clinical symptoms, and gestational age, this will be determined.

### REFERENCES:

1. Arruzza, E., Milanese, S., Li, L., & Dizon, J. (2022). Diagnostic accuracy of computed tomography and ultrasound for the diagnosis of acute appendicitis: A systematic review and meta-analysis. *Radiography*, 28(4), 1127-1141.
2. Ashbrook, M., Cheng, V., Sandhu, K., Matsuo, K., Schellenberg, M., Inaba, K., & Matsushima, K. (2022). Management of complicated appendicitis during pregnancy in the US. *JAMA Network Open*, 5(4), e227555-e227555.
3. Bazdar, S., Dehghankhalili, M., Yaghmaei, S., Azadegan, M., Pourdavood, A., Niakan, M. H., & Bananzadeh, A. M. (2018). Acute appendicitis during pregnancy; results of a cohort study in a single Iranian center. *Bulletin of Emergency & Trauma*, 6(2), 122.
4. Bom, W. J., Scheijmans, J. C., Salminen, P., & Boermeester, M. A. (2021). Diagnosis of uncomplicated and complicated appendicitis in adults. *Scandinavian Journal of Surgery*, 110(2), 170-179.
5. Choi, Y. S., Seo, J. H., Yi, J. W., Choe, Y.-M., Heo, Y. S., & Choi, S. K. (2023). Clinical Characteristics of Acute Appendicitis in Pregnancy: 10-Year Experience at a Single Institution in South Korea. *Journal of Clinical Medicine*, 12(9), 3277.
6. Di Saverio, S., Podda, M., De Simone, B., Ceresoli, M., Augustin, G., Gori, A., Boermeester, M., Sartelli, M., Coccolini, F., & Tarasconi, A. (2020). Diagnosis and treatment of acute appendicitis: 2020 update of the WSES Jerusalem guidelines. *World journal of emergency surgery*, 15, 1-42.
7. Echevarria, S., Rauf, F., Hussain, N., Zaka, H., Ahsan, N., Broomfield, A., Akbar, A., Khawaja, U. A., & Farwa, U. E. (2023). Typical and atypical presentations of appendicitis and their implications for diagnosis and treatment: a literature review. *Cureus*, 15(4).
8. Eom, J. M., Hong, J. H., Jeon, S. W., Choi, J. S., Lee, J. H., Kim, H. O., Kim, H., Choi, P. C., & Han, S. K. (2012). Safety and clinical efficacy of laparoscopic appendectomy for pregnant women with acute appendicitis. *Annals of the Academy of Medicine-Singapore*, 41(2), 82.
9. Heise, J. W., Kentrup, H., Dietrich, C. G., Cosler, A., Hübner, D., & Krumholz, W. (2021). Laparoscopic appendectomy: A safe and definitive solution for suspected appendicitis. *Visceral Medicine*, 37(3), 180-188.

10. Keven, A., Tekin, A. F., Arslan, F. Z., Özer, H., & Durmaz, M. S. (2023). Two-dimensional shear wave elastography can improve the diagnostic accuracy of ultrasonography in acute appendicitis. *Journal of Ultrasound*, 26(2), 471-477.
11. Kirshtein, B., Perry, Z. H., Avinoach, E., Mizrahi, S., & Lantsberg, L. (2009). Safety of laparoscopic appendectomy during pregnancy. *World journal of surgery*, 33, 475-480.
12. Kozan, R., Bayhan, H., Soykan, Y., Anadol, A. Z., Sare, M., & Aytac, A. B. (2020). Acute appendicitis in pregnancy: how to manage? *Şişli Etfal Hastanesi Tıp Bülteni*, 54(4), 457-462.
13. Krzyzak, M., & Mulrooney, S. M. (2020). Acute appendicitis review: background, epidemiology, diagnosis, and treatment. *Cureus*, 12(6).
14. Lapsa, S., Ozolins, A., Strumfa, I., & Gardovskis, J. (2021). Acute appendicitis in the elderly: a literature review on an increasingly frequent surgical problem. *Geriatrics*, 6(3), 93.
15. Mantoglu, B., Gonullu, E., Akdeniz, Y., Yigit, M., Firat, N., Akin, E., Altintoprak, F., & Erkorkmaz, U. (2020). Which appendicitis scoring system is most suitable for pregnant patients? A comparison of nine different systems. *World journal of emergency surgery*, 15, 1-8.
16. Monsonis, B., Mandoul, C., Millet, I., & Taourel, P. (2020). Imaging of appendicitis: Tips and tricks. *European Journal of Radiology*, 130, 109165.
17. Moris, D., Paulson, E. K., & Pappas, T. N. (2021). Diagnosis and management of acute appendicitis in adults: a review. *Jama*, 326(22), 2299-2311.
18. Peksöz, R., Dişçi, E., Kaya, A., Ağırman, E., Korkut, E., Aksungur, N., Altundaş, N., Kara, S., & Atamanalp, S. S. (2022). Significance of laboratory parameters in diagnosing acute appendicitis during pregnancy. *ANZ Journal of Surgery*, 92(1-2), 121-127.
19. Şenocak, R., Çelik, S. U., & Kaymak, Ş. (2020). Diagnosis, management and clinicopathological features of acute appendicitis in pregnant women and its impact on fetal outcomes. *İstanbul Tıp Fakültesi Dergisi*, 135-140.
20. Talan, D. A., & Di Saverio, S. (2021). Treatment of acute uncomplicated appendicitis. *New england journal of medicine*, 385(12), 1116-1123.
21. Vagholkar, K. (2020). Acute appendicitis in adults. *International Surgery Journal*, 7(9), 3180-3186.
22. Yavuz, Y., Sentürk, M., Gümüş, T., & Patmano, M. (2021). Acute appendicitis in pregnancy. *Turkish Journal of Trauma and Emergency Surgery*, 27(1), 85.
23. Yoo, K. C., Park, J. H., Pak, K. H., Kim, K. Y., Lee, B. H., Kim, B. C., & Kim, J. W. (2016). Could laparoscopic appendectomy in pregnant women affect obstetric outcomes? A multicenter study. *International journal of colorectal disease*, 31, 1475-1481.