



RADIOFREQUENCY CATHETER ABLATION OF IDIOPATHIC LEFT POSTERIOR FASCICULAR VENTRICULAR TACHYCARDIA IN SINUS RHYTHM

Zahoor Ahmad Khan^{1*}, Hameedullah², Zahid Aslam Awan³

^{1*} Assistant Professor Cardiac Electrophysiology Department Hayatabad Medical Complex, Peshawar - Pakistan

² Associate Professor Cardiac Electrophysiology Department Hayatabad Medical Complex, Peshawar - Pakistan

³ Professor Cardiac Electrophysiology Department Hayatabad Medical Complex, Peshawar - Pakistan

Corresponding Author: Zahoor Ahmad Khan

* Assistant Professor Cardiac Electrophysiology Department Hayatabad Medical Complex, Peshawar – Pakistan, Email: drzahoorcd_79@yahoo.com

Abstract

Objective: To determine the Radiofrequency catheter ablation of idiopathic left posterior fascicular ventricular tachycardia in sinus rhythm.

Methodology: This study was conducted at the Cardiac Electrophysiology Department, Hayatabad Medical complex Peshawar Pakistan from February 2015 to December 2021. A total of 75 Patients with both gender and any age group were included in this study. Total 75 individuals of any age and gender who met the Zippes Triad criteria for idiopathic left ventricular tachycardia were included. For these individuals, radiofrequency ablation procedures were performed. Diastolic potential was the primary focus of ablation. Using SPSS version 18, data was input and examined for descriptive statistics.

Results: 12 women and 63 men made up the total of 75 patients. Sixty percent of the patients reported having palpitations, and ninety-six percent had chest discomfort in addition to palpitations. Most frequent ECG result was right bundle branch block with left axis deviation, whereas 2.6% of patients had right bundle branch block with right axis deviation. Only 6.6% of instances had recurrence after all successful ablations. All ablations, with the exception of one, were performed using retrograde approach.

Conclusion: The most prevalent arrhythmia in our group is idiopathic left ventricular tachycardia, for which radiofrequency catheter ablation is the recommended course of treatment.

Keywords: Radiofrequency; catheter ablation; idiopathic left posterior fascicular ventricular tachycardia; sinus rhythm

Introduction

Left posterior fascicular ventricular tachycardia (LPF-VT), with QRS morphology displaying a right bundle branch block (RBBB), is the most prevalent kind of idiopathic left ventricular (LV) tachycardia. (1) The distal, intermediate, and proximal parts of the Purkinje network surrounding the LPF may be the source of the egress for LPF-VT. Mapping of such tachycardias from the fascicles

can be guided by the His-ventricular (HV) interval during LPF-VT (2) Ventricular tachycardia results in wide-complexity, accounting for approximately 8% of cases. Typically, myocardial scar-related (VT) is monomorphic in individuals with acute coronary syndrome, while it can be polymorphic. Acute myocardial infarction increases the risk of death by ventricular tachycardia.(3). Electrolytes imbalances, hypokalemia, and hypocalcemia are among the other causes of ventricular (and subsequent) tachycardia.(4) Idiopathic ventricular tachycardia is an uncommon form of VT. It is common to find it in younger people who do not have any structural heart disease. The most prevalent causes of idiopathic ventricular tachycardia are outflow tracts, mitral/tricuspid annulus, and left bundle branch fascicles.(5)The effectiveness of catheter ablation in treating drug-refractory ventricular tachycardia has been demonstrated. Only a limited number of individuals with severe ischemic cardiomyopathy who are not sensitive to amiodarone or other antiarrhythmic drugs should receive it (6). The mortality rate for ventricular tachycardia ablation in experienced centers is less than 1%, making it a relatively safe procedure. Similar to other electrophysiology procedures, vascular access causes complications similar to stroke, but not as often as temporary. (7) Radiofrequency, or RF, catheter ablation is the first-line therapy for many tachyarrhythmias and has become the standard treatment for many arrhythmias.(8) RF ablation utilizes high-frequency (500–750 Hz) current to create lesions through thermal injury. When the ablation catheter is in contact with tissue, resistance to heat causes damage. The heat that is generated causes damage to deeper tissues.(9).the current study was performed to determine Radiofrequency catheter ablation of idiopathic left posterior fascicular ventricular tachycardia in sinus rhythm

Material and method

This study was conducted at the cardiac Electrophysiology Department, Hayatabad Medical complex Peshawar Pakistan from February 2015 to December 2021. A total of 75 Patients with both gender and any age group were included in this study.

This retrospective study involved radiofrequency catheter ablation of 75 individuals with LPF-VT. Patients were excluded if they had RBBB, LPF block, or left anterior fascicular block during the baseline sinus rhythm (SR) ECG and could not be induced to induce LCF-VT.

Before the technique drugs were stopped for 5 half-lives. All the participants were given Alprazolam 0.25 mg 12 hours before the procedure. In a typical four wire study, used 'Cournand' Quadripolar catheter (CRD) from right atrium and right ventricle, and another CRC-2 for HIS. A St.jude Decapolar catheter was used for mapping the Coronary Sinus. Our ablation was achieved by using a Quadripolar Therapy TM catheter from St. Jude with a 2mm spacing and curved 4 mm tip. Four 6F sheaths were passed using the Seldinger technique, with 3 on the left and 1 on the right, while a 7 F sheath was passed in the right femoral artery for ablation. To achieve ablation, a right-sided catheter was inserted into the right femoral artery and advanced through it to the LV. A bolus injection of up to 55,000 units was administered. The electrograms were recorded in a bipolar intracardium using filtered bandwidth of 30 to 400 Hz. aVL, ECG leads I. Sinus rhythm was displayed alongside V1, along with intracardiac electrograms from RA, RV, and HIS on a multichannel system using Bard Lab System TM Pro EP Recording system (Seattle, WA, USA). Diastolic potential (DP) and Purkinje Potential (PP) were given more importance than ever before.(9,10) Atrial Extra systole (AEST) was responsible for inducing tachycardia at varying speeds of 500 ms to 370ms. The VT duration was 36573 ms. The LV basal septal area had a diastolic potential and the posterior third of the SV septum had an APS. Prior to VT, the DP was mapped in the sinus rhythm, preceding the PPs and following the activation of the ventricles. Ablation was favored for sinus rhythm and targeted the PP. The VT was self-terminated and intermittently induced during sinus rhythm. The VT's inducibility was tested using AEST. To check for any recurrence, patients were observed and monitored for 24 hours before being given Aspirin 75 mg for one month. Follow-up visits were scheduled at 1 month and 4 months after ablation.

Results

A total of 75 individuals participated in this study in which males were 63 while female were 12. The majority of the patients were between 36 and 55 years old. 65% were males. In 96% of cases, palpitations were a presenting symptom, and in 60%, chest pain and palpitation were present. Almost all (97%) of RBBB morphology was left-sided. 4 percent of the electrocardiographic data was found. Only 2 specimens displayed RBBB morphology with a right axis configuration. Electrophysiological findings and outcome of patients with ILVT **shown table 1.**

The site of earliest ventricular activation during VT of RBBB with LAD, the exit site was in the region of the inferoposterior LV septum in 97.4% of ILVTs, i.e. of LPF, and with patients with RBBB with RAD was near the anterosuperior LV septum in 2.6% of the left ventricle **as shown in figure 1-3.** In most cases, ventricular electrograms were discrete in both the normal sinus rhythm. (**FIG.2**) VT ablation was done successfully in all cases (100%) as shown in **figure 4.** Recurrence occurred in only 6.6% of the patients

Discussion

An idiopathic left ventricular tachycardia (ILVT) is a common VT that affects the heart. The most frequent symptoms of ILVT in patients include palpitations and chest pain. These patients have a very good prognosis. Treatment can be medical or radiofrequency catheter ablation, which is recommended in class I cases exhibiting symptoms. Our study data is related to worldwide information (10). In young adults aged 15-40 years, ILVT is more prevalent and affects males 60%–80(11,12) The most common clinical manifestation is paroxysmal palpitations and dizziness. Up to 6% of individuals with persistent tachycardia have been diagnosed with induced cardiomyopathy. Following ablation, it is typically reversible.(13) Although most episodes happen at rest, exercise, emotional stress, and catecholamine infusion can serve as triggers. Most similar studies use a retrograde technique of radiofrequency ablation. The ablation we have utilized with this technique has been effective. The rate of recurrence in our study was similar to that found in other studies. The use of catheter ablation is highly effective and recommended in ILVT (11). Although there are some complications, the success rate is high.(12) It is significant to know and treat ILVT primary with RF ablation in such cases. Radiofrequency catheter ablation is the best choice for the management of ILVT (13).

Conclusion:

Idiopathic left ventricular tachycardias are major arrhythmias in our country and catheter ablation is the standard treatment

Table 1: Baseline characteristics			
Total number of patients	Total suspected patients 119	ILVT 75	
Age in years	15-35	10	
	36-55	60	
	56-75	5	
Gender	Male	Female	
	63	12	
Presentation	Palpitation with chest pain	Palpitations	
ECG	RBB with LAD	RBB with RAD	RBB with normal axis
	97.4%	2.6%	0.0%

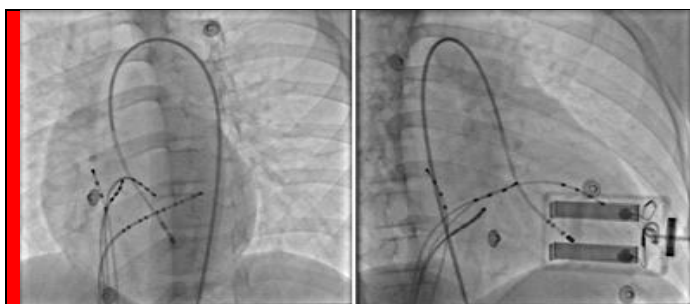


Figure 1: Fluoroscopic images LAO 40 and RAO 30 showing ablation catheter on mid inferior septum

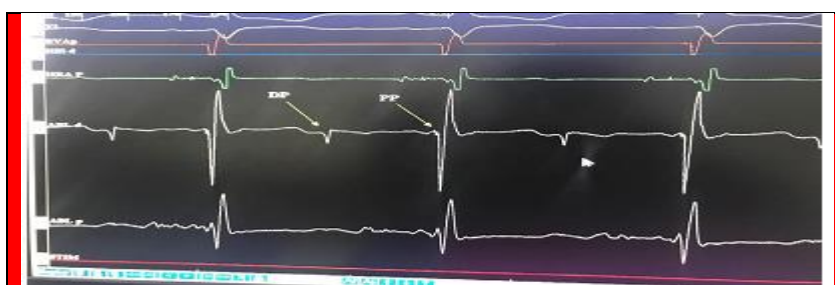


Figure 2: Mapping in sinus rhythm display diastolic potential and Purkinje potential

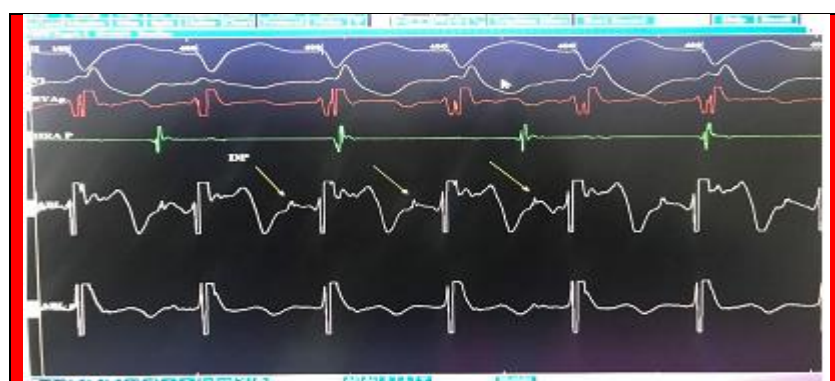

Figure 3: Electrophysiological tracing showing diastolic potential during tachycardia leads the QRS

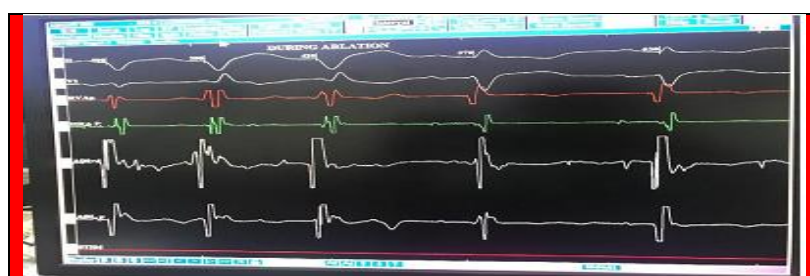

Figure 4: Electrophysiological tracing through effective ablation showing termination of tachycardia

References

1. Nakagawa H, Beckman KJ, McClelland JH, Wang X, Arruda M, Santoro I, Hazlitt HA, Abdalla I, Singh A, Gossinger H. Radiofrequency catheter ablation of idiopathic left ventricular tachycardia guided by a Purkinje potential. *Circulation*. 1993;88:2607–2617
2. Liu Q, Shehata M, Jiang R, Yu L, Chen S, Zhu J, Ehdai A, Sovari AA, Cingolani E, Chugh SS, Jiang C, Wang X. Macroreentrant loop in ventricular tachycardia from the left posterior

- fascicle: new implications for mapping and ablation. *Circ Arrhythm Electrophysiol.* 2016;9:xxx–xxx. doi: 10.1161/ CIRCEP.116.004272.
3. Jabbari R, Engstrøm T, Glinge C, Risgaard B, Jabbari J, Winkel BG, Terkelsen CJ, Tilsted HH, Jensen LO, Hougaard M, Chiuve SE, Pedersen F, Svendsen JH, Haunsø S, Albert CM, Tfelt-Hansen J. Incidence and risk factors of ventricular fibrillation before primary angioplasty in patients with first ST-elevation myocardial infarction: a nationwide study in Denmark. *J Am Heart Assoc.* 2015 Jan 05;4(1):e001399
 4. Koplán BA, Stevenson WG. Ventricular tachycardia and sudden cardiac death. *Mayo Clin Proc.* 2009 Mar;84(3):289-97
 5. Kobayashi Y. Idiopathic Ventricular Premature Contraction and Ventricular Tachycardia: Distribution of the Origin, Diagnostic Algorithm, and Catheter Ablation. *J Nippon Med Sch.* 2018;85(2):87-94
 6. Al-Khatib SM, Daubert JP, Anstrom KJ, Daoud EG, Gonzalez M, Saba S, Jackson KP, Reece T, Gu J, Pokorney SD, Granger CB, Hess PL, Mark DB, Stevenson WG. Catheter ablation for ventricular tachycardia in patients with an implantable cardioverter defibrillator (CALYPSO) pilot trial. *J Cardiovasc Electrophysiol.* 2015 Feb;26(2):151-7
 7. Sapp JL, Wells GA, Parkash R, Stevenson WG, Blier L, Sarrazin JF, Thibault B, Rivard L, Gula L, Leong-Sit P, Essebag V, Nery PB, Tung SK, Raymond JM, Sterns LD, Veenhuyzen GD, Healey JS, Redfearn D, Roux JF, Tang AS. Ventricular Tachycardia Ablation versus Escalation of Antiarrhythmic Drugs. *N Engl J Med.* 2016 Jul 14;375(2):111-21
 8. Guidelines for Clinical Intracardiac Electrophysiological and Catheter Ablation Procedures. A report of the American College of Cardiology/American Heart Association Task on Practice Guidelines (Committee on Clinical Intracardiac Electrophysiologic and Catheter Ablation Procedures). Developed in collaboration with the North American Society of Pacing and Electrophysiology. *Circulation.*2000;92(3):673–691
 9. Nath S, DiMarco JP, Haines DE. Basic aspects of radiofrequency catheter ablation. *J Cardiovasc Electrophysiol.* 2000;5(10):863–876
 10. Nogami A, Naito S, Tada H, Taniguchi K, Okamoto Y, Nishimura S et al. Demonstration of diastolic and presystolic purkinje potentials as critical potentials in a mac
 11. Wen MS, Yeh SJ, Wang CC, Lin FC, Wu D. Successful radiofrequency ablation of idiopathic left ventricular tachycardia at a site away from the tachycardia exit. *J Am Coll Cardiol.* 1997;30:1024–31
 12. Ramprakash, B., Jaishankar, S., Rao, H. B., & Narasimhan, C. Catheter ablation of fascicular ventricular tachycardia. *Indian pacing and electrophysiology journal.* 2008;8:193-202
 13. Ohe T, Aihara N, Kamakura S, Kurita T, Shimizu W, Shimomura K. Long-term outcome of verapamil-sensitive sustained left ventricular tachycardia in patients without structural heart disease. *J Am Coll Cardiol.* 200;25:54–8.