



## ASSOCIATION OF SONOGRAPHIC GRADES OF VARICOCELE WITH SEMEN ANALYSIS IN INFERTILE MEN IN KHYBER PAKHTUNKHWA

Hanif ullah Rabbani<sup>1</sup>, Sahar Fahim<sup>2\*</sup>, Mir Abid Jan<sup>3\*</sup>, Raham Bacha<sup>4</sup>, Zahid Saddique<sup>5</sup>

<sup>1</sup>University Institute of Radiological Sciences & Medical Imaging Technology, University of Lahore – Pak, Email: rabanihanifullah@gmail.com

<sup>2\*</sup>Radiology department, Hayatabad Medical Complex, Peshawar – Pak,  
Email: sahar.fahim@ymail.com

<sup>3\*</sup>Andrology department. (IKD), Hayatabad Medical Complex, Peshawar – Pak  
Email: drmirabid@yahoo.com

<sup>4</sup>University Institute of Radiological Sciences & Medical Imaging Technology, University of Lahore – Pak Email: raham.bacha@rsmi.uol.edu.pk

<sup>5</sup>Social Security Teaching Hospital Multan Road, Lahore – Pak, Email: drzahid1963@gmail.com

**\*Corresponding Author:** Sahar Fahim  
Email: sahar.fahim@ymail.com,

Mir Abid Jan  
Email: drmirabid@yahoo.com

---

### ABSTRACT

**Objectives:** To find the sonographic grades of varicocele in infertile men. To compare sonographic grades of varicocele with semen analysis.

**Methodology:** This cross-sectional analytical study was conducted at Department of Radiology Institute of Kidney Diseases Peshawar, Pakistan. A total of 195 infertile patient with a history of primary and secondary infertility were observed from 15sep. 2022 to April 2023.

**Results:** Total 195 infertile male patients were included by consecutive sampling. The minimum age of patient was 18Y and maximum age was 45Y in this study. The mean age was 30 years. Total mean and standard deviation of semen volume in grade I, Grade II & Grade III varicocele were 2.03±0.87cc. Rapid progression was 18.6±16.92 per/ml. Non-motile (dead) was 48.13±23.45per/ml. In slow progression was 25.03±15.81per/ml. In morphology normal was 11.06±17.91 per / field. In morphology abnormal was 80.73±29.92per/field. Sperm count was 44.97±25.90 million/ml. Slow progression, normal morphology, abnormal morphology and sperm count had large effect i.e.  $n^2=0.14$ .

**Conclusion:** Abnormal sperm morphology was significantly affected by the grades of varicocele. Similarly the sperm count was also affected but the rest of all the parameters in semen analysis were not significantly affected by different grades of varicocele.

**Keywords:** Infertility, Semen analysis, scrotal colour Doppler ultrasound, primary infertility, grades of varicocele, secondary infertility.

## INTRODUCTION

Varicocele is a common cause of infertility in males, affects 15% male population in general & 21-39% in sub-fertile male. Still the pathogenesis is unclear, reduced testicular volume, Leyden cell malfunction, and progressive testicular damage are its defining characteristics. Physical examination is used to clinically diagnose varicocele, varicocele have only specificity of 70% & confirmed by scrotal colour Doppler ultrasound (sensitivity 97% and specificity 94%).<sup>1</sup>

Internationally one out of every six couples reports in infertility clinics for treatment of infertility. Among these 40-50% are due to male factors, 25 % cases are due to female , 20% are due to a combination of female and male factors while 10% have unexplained infertility. The prevalence of varicocele is 25% of males who have abnormal semen analysis.<sup>2</sup> Varicocele occurs in around one third of infertile males, infertility in men are caused by varicocele, Varicocele in most of the patients was on left side of scrotum.<sup>3-4</sup>

Varicocele disrupts scrotal temperature, which affects spermatogenesis negatively and causes male infertility.<sup>5</sup>

Varicocele is the most common treatable factor in male infertility. It seen up to 80% of secondary infertile men & in 35%–40% of all males with history of primary infertility.<sup>6</sup>

Adult infertile males with clinically identified varicocele had significantly lower sperm counts, motility & semen morphology.<sup>7</sup>

About 90% of varicocele are left-sided, where they are more prevalent. The varicocele rather common among adult males (11–15%) and infertile men (19–41%).<sup>8</sup>

Men with varicocele and secondary infertility had considerably higher mean blood FSH levels, which may indicate more severe damage to the seminiferous tubule.<sup>9</sup>

Given that varicoceles high males risk of infertility and are known negatively affect sperm function.<sup>10</sup>

The majority of research found that patients with varicocele had lower-quality sperm.<sup>11</sup> One of the main factors leading to male infertility is varicocele. The semen analysis and different degrees of varicoceles in infertile males are compared in current study.

## MATERIAL AND METHODS

Gray-scale and colour Doppler ultrasound was performed with help of the high frequency (7.5 MHz) linear ultrasound transducer for optimal resolution and better results. These vascular lesions divided into three grades on the basis of vein diameter, The Dubin grading system is the one that is used the most frequently, Grade 3: palpable & visible, Grade 2: only palpable at rest, Grade 1: during Valsalva maneuver palpable, Subclinical varicocele: diagnosed on colour doppler ultrasound scan but not palpable/visible at rest or under Valsalva maneuver technique, The semen analysis report was received from the pathology dept. Data entry and analysis were done by using SPSS version-24. Variables like semen parameter, and sonographic findings were presented with mean  $\pm$  SD, frequency and percentage. Spearman correlation test was applied. P- Value  $\leq$  0.05 will be considered significant. The grading of varicocele and parameter of semen analysis were compared with one way ANOVA.

**Study Design:** Cross-sectional analytical study.

**Settings:** This cross-sectional analytical study was conducted at Department of Radiology, Institute of Kidney Diseases Peshawar, Pakistan.

**Sample Size:** A total of 195 male infertile patient with a history of primary and secondary infertility were observed from 15sep. 2022 to April 2023.

**Inclusion Criteria:**

Infertile men between 18 to 45 years with varicocele.

Patient with semen analysis test.

**Exclusion Criteria:**

Undescended testicles, Testicular injury, Testicular masses

Pt. who have undergone varicocelectomy.

**Results**

This was a cross sectional analytical study of infertile patients who were included in this research study. Total 195 infertile patients were included by purposive sampling. The minimum age of patient was 18Y and maximum age was 45Y in this study, Mean age of the participants involved in study was  $30.24 \pm 4.13$  years. According to table 5.1 shows there are high changes on semen parameter through varicocele are the total mean and standard deviation of semen volume in grade one, Grade two and Grade three varicocele was  $2.03 \pm 0.87$ cc. In Rapid progression was  $18.6 \pm 16.92$ per/ml. In Non-mobile (dead) was  $48.13 \pm 23.45$ per/ml. In slow progression was  $25.03 \pm 15.81$ per/ml. In morphology normal was  $11.06 \pm 17.91$  per / field. In morphology abnormal was  $80.73 \pm 29.92$ per/field. In sperm count was  $44.97 \pm 25.90$  million/ml. In pus cell was  $7.18 \pm 4.86$ per/HPF. Respectively.

The significant positive correlation from the table 5.2 shows the association was measured between eight variable where we assumed that semen volume, non-motile, puss cell had a small effect i.e.  $n2=0.01$ , where rapid progression had medium effect i.e.  $n2=0.06$  and the remaining were slow progression, normal morphology, abnormal morphology and sperm count had large effect i.e.  $n2=0.14$ . To completely comprehend the effects modification in correlation between varicocele and semen parameters, more study is necessary. Improved counselling, care, and support for those with varicocele will result from a greater comprehension of the cumulative impact of varicocele on sperm quality and ultimately fertility. The apparent lack of a correlation between the diameter of the varicocele vein and the quality of the semen points to the need for further research into additional variables that may contribute to the pathogenicity of varicocele. When determining the severity of varicocele, diagnostic value of colour Doppler US can be carefully interpreted and clinically connected.

The Fig 5.3 Bar chart shows different grades of varicoceles which effect on semen morphology abnormal, the total 20pt (10.2%) in grade II, 18pt (9.2%) in grade I varicocele and 13pt (6.6%) in grade III varicocele have semen morphology abnormal 97.00% Per/field, 16pt (8.2%) in grade I, 13pt (6.6%) in grade two shows 11pt (5.6%) in grade three varicocele have morphology abnormal 98.00% per/ml, 13pt (6.6%) in grade I, 11pt (5.6%) in grade II and 3pt (1.5%) in grade III varicocele have morphology abnormal 96.00% per/ml, 7pt (3.5%) in grade II, III and 2pt (1.02%) in grade I varicocele have 00% morphology abnormal.

One way ANOVA was applied to know mean more than two independent variables where from the results Semen volume, Rapid progression, Non mobile Dead, Slow progression, Morphology normal and on pus cell were not statistically significant different between group means as determine by one way ANOVA. On the other side, morphology abnormal and sperm count were statistically significant (Table 5.4)

**Table 5.1:** To compare the different grades of varicocele effect on semen volume, rapid progression, non-motile (dead), slow progression, morphology normal, morphology abnormal, sperm count and on pus cell.

Grade of varicocele I,II,III		Semen volume	Rapid progression	Non motile (Dead)	Slow progression	Morphology normal	Morphology abnormal	Sperm count	pus cell	Patient Number
1	Mean	2.01	20.23	49.63	27.48	8.51	88.80	51.40	7.25	75
	Std. Deviation	0.91	18.28	20.77	15.54	13.82	20.19	25.77	5.37	
2	Mean	2.11	18.28	47.37	24.42	11.76	78.38	41.23	6.86	71
	Std. Deviation	0.90	15.18	24.33	16.18	18.97	32.03	23.34	4.56	
3	Mean	1.97	16.57	46.96	22.18	13.90	71.82	40.55	7.55	49
	Std. Deviation	0.78	17.23	26.26	15.42	21.39	36.08	28.07	4.54	
Total	Mean	2.04	18.60	48.13	25.04	11.05	80.74	44.97	7.18	195
	Std. Deviation	0.87	16.92	23.45	15.81	17.91	29.92	25.90	4.87	

From the table 5.2 reveal the association was measured between eight variable where we assumed that semen volume, non-motile, puss cell had small effect i.e.  $n^2=0.01$ , where rapid progression had medium effect i.e.  $n^2=0.06$  and the remaining were slow progression, normal morphology, abnormal morphology and sperm count had large effect i.e.  $n^2=0.14$ .

**Measures of Association**

	Eta	Eta Squared
Semen volume * Grade of varicocele I,II,III	.067	.004
Rapid progression * Grade of varicocele I,II,III	.086	.007
Non mobile Dead * Grade of varicocele I,II,III	.051	.003
Slow progression * Grade of varicocele I,II,III	.134	.018
Morphology normal * Grade of varicocele I,II,III	.122	.015
Morphology abnormal * Grade of varicocele I,II,III	.230	.053
Sperm count * Grade of varicocele I,II,III	.197	.039
pus cell * Grade of varicocele I,II,III	.056	.003

**ANOVA Table**

		Sum of Squares	df	Mean Square	F	Sig.
Semen volume * Grade of varicocele I,II,III	Between Groups (Combined)	.661	2	.331	.432	.650
	Within Groups	146.890	192	.765		
	Total	147.551	194			
Rapid progression * Grade of varicocele I,II,III	Between Groups (Combined)	407.287	2	203.644	.709	.493
	Within Groups	55115.513	192	287.060		
	Total	55522.800	194			
Non mobile Dead * Grade of varicocele I,II,III	Between Groups (Combined)	276.589	2	138.295	.249	.779
	Within Groups	106433.944	192	554.343		
	Total	106710.533	194			
Slow progression * Grade of varicocele I,II,III	Between Groups (Combined)	873.358	2	436.679	1.761	.175
	Within Groups	47613.391	192	247.986		
	Total	48486.749	194			
Morphology normal * Grade of varicocele I,II,III	Between Groups (Combined)	918.419	2	459.209	1.439	.240
	Within Groups	61286.166	192	319.199		
	Total	62204.585	194			
Morphology abnormal * Grade of varicocele I,II,III	Between Groups (Combined)	9169.582	2	4584.791	5.351	.005
	Within Groups	164502.079	192	856.782		
	Total	173671.662	194			
Sperm count * Grade of varicocele I,II,III	Between Groups (Combined)	5053.299	2	2526.649	3.878	.022
	Within Groups	125098.517	192	651.555		
	Total	130151.815	194			
pus cell * Grade of varicocele I,II,III	Between Groups (Combined)	14.453	2	7.227	.303	.739
	Within Groups	4578.901	192	23.848		
	Total	4593.354	194			

**Table No 5.4** Shows the ANOVA Table of Sum of Squares, df, Mean Square, F, sig, One way ANOVA was applied to know mean more than two independent variables where from the results Semen volume, Rapid progression, Non mobile Dead, Slow progression, Morphology normal and on pus cell were not statistically significant different between group means as determine by one way ANOVA. On the other side, morphology abnormal and sperm count were statistically significant (Table 5.10,

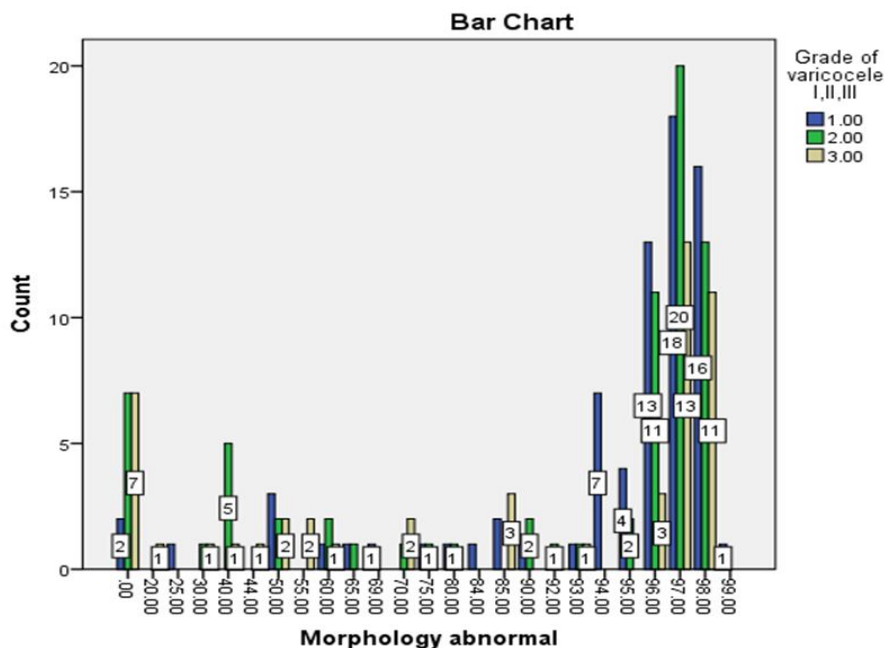


Fig 5.3 Shows the various grades of varicoceles effect on morphology abnormal.

**Discussion**

This research aimed to find the association of the various grades of varicocele with semen analysis parameters and to compare the incidence of infertility findings with different grades. Scrotal colour Doppler ultrasonography has been shown to be particularly effective in infertile patients by Rehman KU *et al*, shows varicocele clinical & physical examination with a specificity just only 70 percent & conformed through colour doppler ultrasonography (CDUS) analysis with a sensitivity 97 percent and specificity of 94 percent are used to make the varicocele diagnosis.<sup>12</sup>

In the present study varicocele have been categorized into three grades on the basis of the diameter of tortuous veins in pampiniform venous plexus of the internal & external spermatic cord. To explicate this the, out of 195 patients only 75 patients (38.5%) depicted in grade I varicocele, whereas in out of 195 patients only 71 patients (36.4%) were in grade II varicocele. In addition to it in grade III out of 195 patients only 49 patients (25.1%) show grade III varicocele. According to the research, males with abnormal semen analysis are 25% more likely to have varicocele. It is the most prevalent cause of infertility in males and affects between 30% and 81% of infertile men as a whole.<sup>13</sup>

The measurements found in our study are in important step as no previous data have ever been reported in such measurements in infertility from our province Khyber Pakhtunkhwa.

In present study the total mean and standard deviation of semen volume shows in grade I, II & grade III varicocele was 2.03±0.87cc. Total mean and standard deviation of Rapid progression in grade I, II and grade III varicocele was 18.6±16.92per/ml. Total mean and standard deviation of Non-mobile (dead) in grade I, II , III varicocele was 48.13±23.45per/ml. total mean and standard deviation of slow progression in grade 1, grade 2 and grade 3 varicocele was 25.03±15.81per/ml. total mean and standard deviation of morphology normal in grade I, II and III varicocele was 11.06±17.91 per / field. Total mean and standard deviation of morphology abnormal in grade one, two and grade three varicocele was 80.73±29.92per/field. Total mean and standard deviation of sperm count in grade I, II and III grades varicoceles was 44.97±25.90 million/ml. total mean and standard deviation of pus cell in grade 1, grade 2 and grade 3 varicocele was 7.18±4.86per/HPF. (Table 5.1). The following literature shows the similar results according to present study shows the reason of infertility that reveals 35 (69 percent) of 51 male with zero semen motile sperm and 12 (55%) of the 22 men with azoospermia before operation had motile sperm in semen analysis test observed in their ejaculate after varicocele surgery varicocelectomy. Before the varicocelectomy,

there were 0.08 6 0.02 3 106 motile sperm per ejaculate; following the procedure, there were 7.2 6 2.3 3 106 motile sperm per ejaculate. 24 males (31%) participated in pregnancies that resulted in live births (15 unaided [19%]), 3 of whom had azoospermia before to surgery. Microsurgical varicocelectomy was performed on 52 men with severe oligoasthenospermia and 22 men with azoospermia. 44 males (79%) showed postoperative improvement in the quality of their sperm. The average postoperative sperm count for 31 men (55%) was 1 3 106, whereas the average postoperative sperm count for 15 men (27%) was 5 3 106. 35 (69%) of 51 men who had no motile sperm in semen analysis before varicocele operation (of whom 12 had azoospermia and 23 had severe oligoasthenospermia) recovered sperm in postoperative semen testing.<sup>14</sup>

The results revealed different grades of varicoceles which effect on semen morphology total 20pt (10.2%) on grade II, 18pt (9.2%) on grade I varicocele and 13pt (6.6%) on grade III varicocele have semen morphology abnormal 97.00% Per/field, 16pt (8.2%) on grade I, 13pt (6.6%) on grade II and 11pt (5.6%) on grade III varicocele have morphology abnormal 98.00% per/ml, 13pt (6.6%) on grade I, 11pt (5.6%) on grade II and 3pt (1.5%) on grade III varicocele have morphology abnormal 96.00% per/ml, 7pt (3.5%) on grade II, III and 2pt (1.02%) on grade I varicocele have 00% morphology abnormal. Rehman KU et al. shows the similar results according to above present study, shows findings that the Mean age of the patients in the research was  $31.77 \pm 7.48$ , from 20Y to 50 years. The semen sperm count, progressive motility, non-progressive motility of sperm, & immotile sperm (dead) and morphology normal of spermatozoa of the infertile patients was  $32.42 \pm 32.51$  million/ml,  $16.47 \pm 14.53$ percent,  $60.37 \pm 25.24$ percent,  $18.71 \pm 13.23$ percent, &  $5.18 \pm 5.47$ percent, respectively.<sup>15</sup>

According to our research, bilateral & right-sided varicocele are less common than left-sided varicocele. The following literature shows the similar results according to present study shows The longer left spermatic vein with its right-angle insertion into the left renal vein &/or the absence of valves may be the cause, which results in a greater hydrostatic pressure & causing dilatation in the left spermatic vein. One of the following important factors including an increase in venous pressure in the left renal vein, insufficient spermatic vein valves, and collateral venous anastomoses, has been linked to the development of varicocele. Varicocele in most of the patients was on left side of scrotum.<sup>16, 17, 18, 19,</sup>

Grades of varicocele ultrasonographic abnormalities in infertile male that have been investigated extensively.

## CONCLUSION

Different grades of varicocele were found to be significant causes of male infertility. In all grades of varicocele compared with semen parameters; abnormal sperm morphology was significantly affected by the grades of varicocele. Similarly the sperm count was also affected but the rest of all the parameters in semen analysis were not significantly affected by different grades of varicocele.

The grade I varicocele was found in majority of the infertile men but grade III was observed in a minimum infertile men's, although the difference was not reasonable.

## Acknowledgement

The present article was extracted from the thesis written by Hanif Ullah, The authors would like to thanks University Institute of Radiological Sciences & Medical Imaging Technology the University of Lahore and thankful to the Staff of Institute of Kidney Diseases Peshawar to collect data. I am thankful to Dr Raham Bacha for statistical assistance his invaluable guidance, and constant encouragement throughout the study, also thankful to all of you, readers, and audience, for reading and reflecting on my research.

## Reference

1. Rehman KU, Zaneb H, Qureshi AB, Yousaf MS, Numan A, Majeed KA, Rabbani I, Khan TM, Rehman H. Correlation between testicular hemodynamic and semen quality indices in clinical varicocele patients in Pakistan. *BioMed Research International*. 2019 Mar 7; 2019.

2. Khalid A, Khan KR, Humayoun M. Immunological and Hormonal Profile of Infertile Pakistani Males with Varicocele. *PAKISTAN JOURNAL OF MEDICAL & HEALTH SCIENCES*. 2018 Jan 1; 12(1):283-5.
3. Pryor JL, Howards SS. Varicocele. *Urologic Clinics of North America*. 1987 Aug 1; 14(3):499-513.
4. Zarin M, Zeb J, Qazi M, Subair B. Two port standard laparoscopic varicocelectomy; an experience at Khyber Teaching Hospital, Peshawar, Pakistan. *Rawal Medical Journal*. 2019; 44(2):319-21.
5. Mansoor M. Improvement in Semen Parameters and Fertility Rate after Varicocelectomy. *Journal of Surgery Pakistan*. 2020; 25(4):143-7.
6. Arraki SM. Evaluation of the effect of varicocelectomy on semen parameters and fertility. *Diyala Journal of Medicine*. 2016; 11(2):34-43.
7. Agarwal A, Sharma R, Harlev A, Esteves SC. Effect of varicocele on semen characteristics according to the new 2010 World Health Organization criteria: a systematic review and meta-analysis. *Asian Journal of Andrology*. 2016 Mar; 18(2):163.
8. Othman AI, Al-Hamamy NM. Correlation of Testicular Volume and Semen Parameter with Varicocele Grades in Mosul City: A Case-Control Study. *Al-Anbar Medical Journal*. 2021; 17(2).
9. Gorelick JJ, Goldstein M. Loss of fertility in men with varicocele. *Fertility and sterility*. 1993 Mar 1; 59(3):613-6.
10. Saleh RA, Agarwal A, Sharma RK, Said TM, Sikka SC, Thomas Jr AJ. Evaluation of nuclear DNA damage in spermatozoa from infertile men with varicocele. *Fertility and sterility*. 2003 Dec 1; 80(6):1431-6.
11. Hauser R, Paz G, Botchan A, Yogev L, Yavetz H. Varicocele and male infertility: part II: varicocele: effect on sperm functions. *Human Reproduction Update*. 2001 Sep 1; 7(5):482-5.
12. Rehman KU, Zaneb H, Qureshi AB, Yousaf MS, Numan A, Majeed KA, Rabbani I, Khan TM, Rehman H. Correlation between testicular hemodynamic and semen quality indices in clinical varicocele patients in Pakistan. *BioMed Research International*. 2019 Mar 7; 2019.
13. Khalid A, Khan KR, Humayoun M. Immunological and Hormonal Profile of Infertile Pakistani Males with Varicocele. *PAKISTAN JOURNAL OF MEDICAL & HEALTH SCIENCES*. 2018 Jan 1; 12(1):283-5.
14. Matthews GJ, Matthews ED, Goldstein M. Induction of spermatogenesis and achievement of pregnancy after microsurgical varicocelectomy in men with azoospermia and severe oligoasthenospermia. *Fertility and sterility*. 1998 Jul 1; 70(1):71-5.
15. Rehman KU, Zaneb H, Qureshi AB, Yousaf MS, Numan A, Majeed KA, Rabbani I, Khan TM, Rehman H. Correlation between testicular hemodynamic and semen quality indices in clinical varicocele patients in Pakistan. *BioMed Research International*. 2019 Mar 7; 2019.
16. Pryor JL, Howards SS. Varicocele. *Urologic Clinics of North America*. 1987 Aug 1; 14(3):499-513.
17. Zarin M, Zeb J, Qazi M, Subair B. Two port standard laparoscopic varicocelectomy; an experience at Khyber Teaching Hospital, Peshawar, Pakistan. *Rawal Medical Journal*. 2019; 44(2):319-21.
18. Pryor JL, Howards SS. Varicocele. *Urologic Clinics of North America*. 1987 Aug 1; 14(3):499-513.
19. C. K. Naughton, A. K. Nangia, and A. Agarwal. Varicocele and male infertility: part ii: pathophysiology of varicoceles in male infertility. *Hum. Reprod. Update*, 7(5):473–481, 2001.