



THE EFFICACY OF CUSTOM-DESIGNED, LIGHT-WEIGHT HOLLOW OCULAR PROSTHESIS: NON-COMPARATIVE INTERVENTIONAL PROSPECTIVE STUDY IN MAYO HOSPITAL, LAHORE, PAKISTAN

Hafiza Sadia Imtiaz^{1*}, Zahid Kamal Siddique², Fizzah Zahid³, Zahid Hafeez Sheikh⁴

^{1*}Senior Registrar/Fellow of Orbit and Oculoplastic, Mayo Hospital, Lahore, Pakistan
Email: sadiaimtiz69@gmail.com

²Professor/Head of Department, Mayo Hospital, Lahore, Pakistan Email: zahidkamal@hotmail.com

³House Officer, Mayo Hospital, Lahore, Pakistan Email: fizzaahzahid10@gmail.com

⁴Ocularist, Sights Lab, Lahore, Pakistan Email: Zahid@sights.com.pk

***Corresponding Author:** - Hafiza Sadia Imtiaz,

*Senior Registrar/Fellow of Orbit and Oculoplastic, Mayo Hospital, Lahore, Pakistan.
Email: sadiaimtiz69@gmail.com

Abstract

The study was conducted to determine the efficacy of custom-designed, light-weight ocular prosthesis in cosmetic rehabilitation of anophthalmic socket with regard to patient's satisfaction level, degree of motility, and less associated complications. The Non-comparative interventional prospective study was employed at the Eye unit III, Mayo Hospital, Lahore. After taking IRB approval, 100 patients of either age and gender, with anophthalmic socket following evisceration or enucleation where orbital volume was sufficiently restored and the fornices were adequately formed, enrolled in this study. Custom-designed and light-weight ocular prosthesis were fabricated by the ocularist and follow up were done. Patient's satisfaction score, degree of motility of ocular prosthesis and associated complications were recorded on proforma. Statistical analysis was performed using SPSS v 25. The findings show that out of 100 patients, 36% were male and 64% were female. Majority of patients (63%) had evisceration previously and the highest percentage for its cause was endophthalmitis (33%). Mean patient's satisfaction score at one month was 4.96 ± 1.25 that further improved to 5.21 ± 0.68 at 6 months follow up with a significant p-value of 0.032 (< 0.05). Degree of prosthetic eye movement was fair in majority (43%) and the most common complication was mucous discharge that too only in 17%. The findings can be concluded that custom designed and light-weight ocular prosthesis are very effective in achieving the higher satisfactory score of patients, better ocular motility and reducing the prosthesis related complications that help patients in maintaining the better quality of life.

Keywords: Custom-designed, Light-weight, Ocular prosthesis, Anophthalmic Socket

INTRODUCTION

The loss of an eye can be very traumatic event in a person's life. The disfigurement associated with loss of an eye can cause significant physical and emotional problems.¹ The rehabilitation of patient

following anophthalmic socket requires a prosthesis that will provide optimum cosmetic and functional result. The patient wants the ideal ocular prosthesis, natural looking, that friends and family don't know about. From the medical point of view this means eyelids in normal position, the ability to blink, eyelashes in normal position, symmetrical with the healthy eye, good motility, custom prosthesis.²

The history of ocular prosthesis dates back to 2900-2800BC when first evidence of use of ocular prosthesis was found in an Iranian woman.^{3,4} It was 2.5cm in diameter made up of light material probably Bitumen paste. Romans and Egyptian priests were known to have produced artificial eyes as early as fifth century constructed from painted clay.⁵ Germans introduced the art of making artificial eyes from glass and later in USA artificial eyes of acrylic paste were used.

Now-a-days wide varieties of ocular prosthesis are available. Unlike stock-based prosthesis which is not individualized for each patient, custom designed prosthesis is prepared with exact measurement of size and shape with help of accurate instruments. It is an innovative design which offers exact fitting of prosthesis on orbital socket providing improved motility.⁶

Another important change added to ocular prosthesis is weight reduction that is achieved by making it hollow. The weight of prosthesis imparts special problems with the motility and discomfort. Socket discomfort has tremendous impact on the quality of life and also influences social interaction in everyday life.⁷⁻¹⁸

The rationale of this study was to determine the behavior of custom designed, light weight ocular prosthesis in terms of its motility, comfort and reduced prosthesis related complications. As many patients present to our oculoplastic unit for cosmetic rehabilitation of anophthalmic sockets, this study would be of tremendous help in improving the quality and reducing the prosthesis related complication.

OBJECTIVE OF THE STUDY

The objective of this study was to determine the efficacy of custom-designed, light-weight ocular prosthesis in cosmetic rehabilitation of anophthalmic socket with regard to patient's satisfaction level, degree of motility, and less associated complications.

MATERIALS AND METHODS

After getting approval from Ethical Review Board and getting written informed consent from every patient according to the Declaration of Helsinki, Non-comparative interventional prospective study was conducted at Eye unit III, Institute of Ophthalmology, Mayo Hospital, Lahore. The duration of the study was sixteen years from July, 2006 to December 2022. The patients were selected by using purposive sampling technique of non-probability sampling. This study included 100 patients of either age and gender, with anophthalmic socket following evisceration and enucleation where orbital volume was sufficiently restored and the fornices were adequately formed. Exclusion criteria was patients who have not completed 6 months follow up period following ocular prosthesis rehabilitation, who had surgical time of less than 6 weeks following evisceration/enucleation, patients with contracted/ infected/ inflamed socket, patients with residual disease who need further treatment or intervention (like radiotherapy for residual tumor), and the eyes where peri-ocular tissue was sacrificed due to disease activity.

Patients fulfilling the inclusion criteria were included in this study. Ocular prostheses were fabricated 6 to 8 weeks following the surgery to allow for healing of socket. During that time, a conformer was worn to help the fornices well-formed and to avoid the contracture. The steps involved in making custom designed PMMA ocular prosthesis were to take the exact impression through selected trays,

socket impression for exact scleral shell preparation, precise iris positioning and iris color matching. The weight of these prosthesis then reduced by making them hollow from inside. (Fig. 1) These were 99.5% monomer free prosthesis where bio-incompatible residual monomers removed through specialized heat activated polymerization. In monomers of PMMA, the addition of 2% glycoldimethacrylate (GDMA) makes it hydrophobic and thus inert in nature that make it comfortable for patient's ocular surface. Thus custom-designed and light weight ocular prosthesis fabricated and fitted by the ocularist.

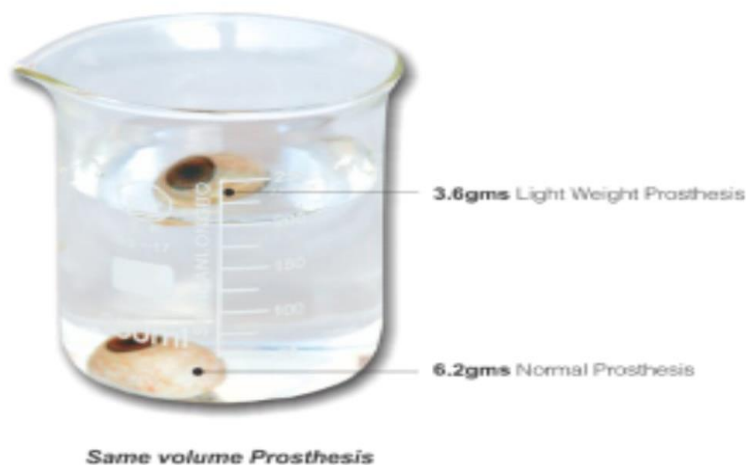


Fig.1: Depiction of light weight ocular prosthesis

The patients were followed up at 1 month and 6 months after prosthesis fitting. At each follow up, motility of prosthesis, satisfactory score (Table 1), and complications recorded on preformed proforma. Consultations and follow up of these patients were made with ophthalmologist as well as ocularist.

Table 1: Satisfaction score

Satisfaction Scores	
1	Highly satisfactory
2	Satisfactory
3	Moderately satisfactory
4	Moderately unsatisfactory
5	Unsatisfactory
6	Highly unsatisfactory

Degree of movement of prosthetic shell is an important parameter regarding cosmetic acquaintance with ocular prosthesis and it was assessed subjectively from patient's/guardian's feedback and categorized into good, fair and poor as follow;

Table 2: Grading of degree of movement of ocular prosthesis

Grading of degree of movement	Defining characteristics
Good	When prosthetic eye has nearly same degree of movement as that of normal eye
Fair	When ocular prosthesis has almost 50% movement compared to normal eye movement
Poor	When ocular prosthesis has less than 50% movement compared to normal eye movement

Statistical analysis was performed using SPSS version 25 software. Categorical data was presented as frequency and percentage while numerical data was presented as Mean±SD. Chi square test was also

used to detect the difference between scores at different follow up periods. The significance was considered at p value < 0.05.

RESULTS

100 patients were included in our study. Out of which 36% were male and 64% were female. Right eye was involved in 45% and left eye was involved in 58% and bilateral involvement in 2%. The mean age of patients in our study was 30.5 ± 2.26 with a range of 15-45 years.

Table 3: Distribution of the Respondents by Different Age Groups

Age group	No. of patients	Percentage
15-25	35	35%
25-35	40	40%
35-45	25	25%

Out of 100 patients who were enrolled for ocular prosthesis, 63% of the patients had evisceration, 25% had enucleation and in remaining 12% anophthalmic socket was either congenital or following pthiasis bulbi. The causes of anophthalmic socket following evisceration and enucleation are described as follow;

Table 4: Causes of anophthalmic socket following evisceration and enucleation

Causes	Percentage
Intraocular tumors	19%
Trauma	21%
Endophthalmitis	33%
Buphthalmos	11%
Congenital anophthalmia	7%
Pthiasis bulbi	5%
Miscellaneous	4%

Satisfaction score was determined from every patient/guardian after ocular prosthesis implantation at a scale of 1-6 at various intervals of time. The mean satisfaction score at one month was 4.96 ± 1.25 . The mean satisfaction score further improved to 5.21 ± 0.68 at 6 months follow up with a significant p-value of 0.032 (< 0.05).

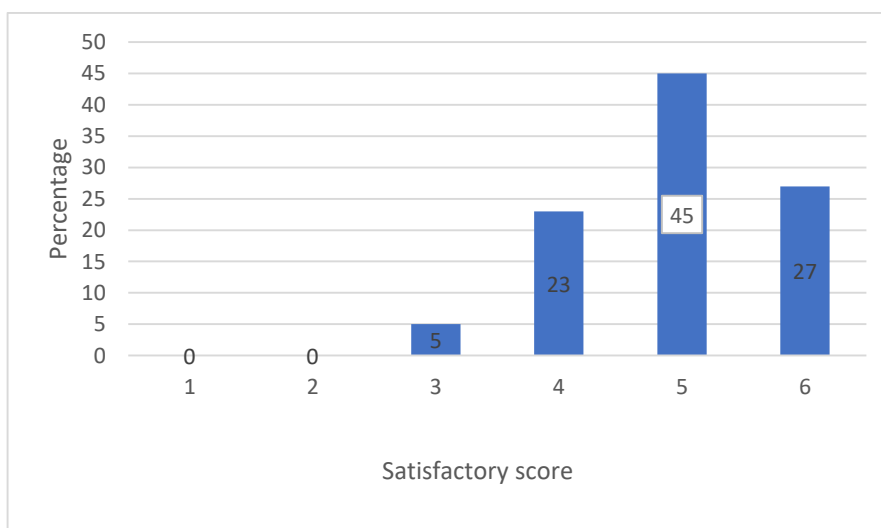


Figure 2: Bar Chart showing percentage of satisfactory score at 6 months following prosthesis fitting

The degree of movement of the prosthetic eye also improved significantly with customized lightweight approach. Following paragraph indicates the feedback of degree of movement of prosthetic eye by the patients.

Table 5: Degree of movement of the prosthetic eye

Degree of movement	Percentage
Good	37%
Fair	43%
Poor	20%

In this study, weight related complications of ocular prosthesis were reduced by 20-64% while continuous wearing time of prosthesis had a range of 30-180 days. Ocular prosthesis can cause various complications that can impact the patient’s well-being.

The different kinds of complications associated with custom designed hollow prosthesis are shown as follow;

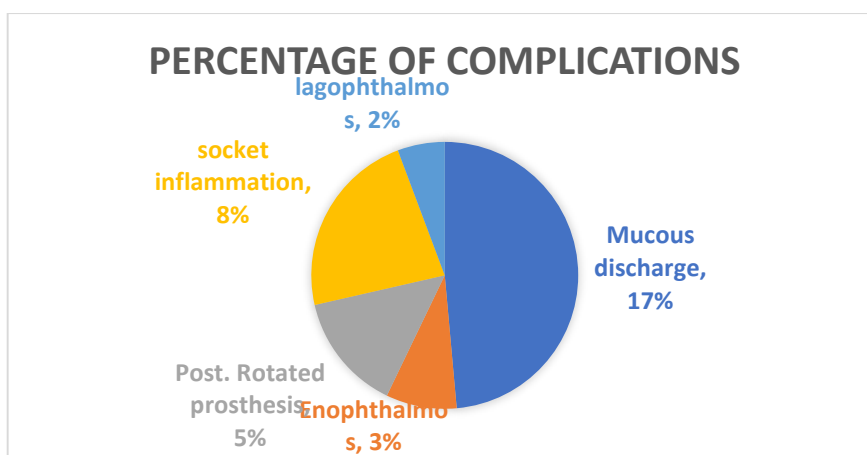


Fig.3: Pie chart showing percentage of complications associated with custom-designed light weight ocular prosthesis

Discussion

The efficiency of a prosthesis can really be judged by the similarity it has with the real, natural organ. In case of ocular prosthesis, it needs to be such that the cosmetic appearance is comparable to the healthy eye so that it may not be a hindrance in the daily social and recreational activities, reducing the psychological trauma. (Fig.4) Along with this outward perspective, there is an inward perspective i.e. the degree of comfort and reduction of complications associated with it and this purpose is achieved by custom designed and low weight ocular prosthesis upon which our study is based.

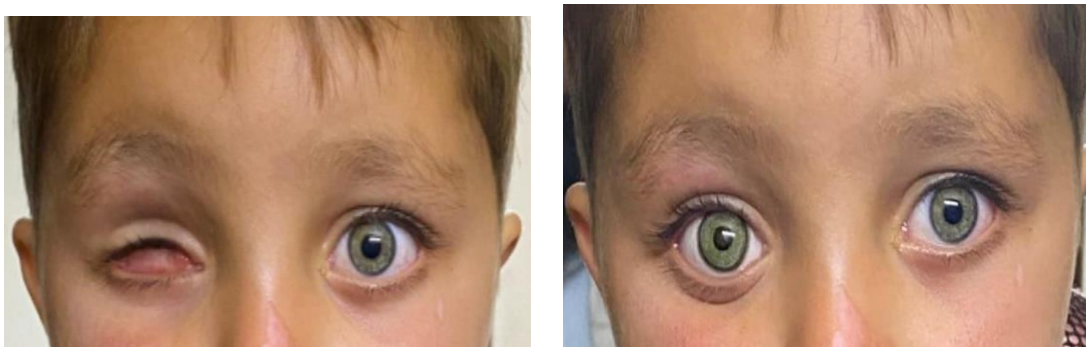

Fig.4: Above picture showing Right Anophthalmic socket following enucleation that was cosmetically corrected by custom-designed light weight ocular prosthesis in below picture

The mean age of participants in our study was 30.5 ± 2.25 years. Out of this 36% were reported to be males and 64% were reported to be females. A similar study on ocular prosthesis was conducted by Pine et al.¹³ in which the mean age of the participants was 58 years, out of which 67% were males and females were 33%. The difference in being higher percentage of females in our study compared to males, is because cosmetic appearance is more concerned for females in our society specially when it comes to their marriage and mean age of 30 years in our study also augments this point. A study conducted by Nicola et al.¹⁴ also pointed out that female patients are more concerned about the cosmetic aspect of it

Our study highlighted the importance of custom designed ocular prosthesis as compared to the stock prosthesis. This has proven to be more cosmetically efficient providing symmetry to patient's face. A similar study conducted by Imam et al.²⁰ showed the improvement in psychological and emotional status of patients of anophthalmia following implantation of ocular prosthesis.

The weight of the ocular prosthesis is also an important factor discussed in our study which can cause real problems for the patients like discomfort, lower lid sagging, discharge and ptosis etc. Lowering the weight of the prosthesis by making it hollow or using a light material like cryolite as compared to polymethyl methacrylate as discussed by Alexander et al.²¹ is a useful progress in this domain that reduces these weight related complications.

The custom designed hollow ocular prosthesis is more efficient in terms of degree of movement of the eye because of its close adaptation to the socket of the individual. Moreover, this has been proved to be better for tissue health because it eliminates any stagnating spaces as highlighted by Maretaningtias et al.²² in his study.

There are always some complications associated with the use of regular stock ocular prosthesis or conventional solid ocular prosthesis like lower lid distortion and asymmetric alignment of the palpebral fissure. The frequency of these complications has shown to be decreased by the use of custom designed hollow ocular prosthesis in our study. One such study was conducted by Vishvnathe et al.¹⁹ in which these complications were shown to be decreased by the use of custom designed hollow ocular prosthesis.

There are some gaps in our study in which further work can be done. First of all, this was a single-centered study, this can be improved by conducting a multicentred research in future. Secondly, a study comparing the effectiveness of custom designed hollow ocular prosthesis versus the conventional stock based ocular prosthesis side by side would be more helpful in future.

CONCLUSION

In conclusion, custom designed and light-weight ocular prosthesis are very effective in achieving the higher satisfactory score of patients, better ocular motility and reducing the prosthesis related complications that help patients in maintaining the better quality of life.

REFERENCES

- 1- Lbbbkin V, Sloan. S:Enucleation and psychic trauma. *Advances in Plastic and Reconstructive surgery* 1990; 8; 259-262.
- 2- Schmitzer S, Simionescu C, Alexandrescu C, Burcea M. The Anophthalmic Socket - Reconstruction Options. *J Med Life*. 2014;7 Spec No. 4(Spec Iss 4):23-9. PMID: 27478515; PMCID: PMC4962761.
- 3- London Times (February 20, 2007). "5000 years old artificial eye found on Iran-Afghan border."
- 4- 3rd millennium B C artificial eye ball discovered in Burnt city Dec. 10, 2008.
- 5- Frequently asked questions, American Society of Ocularist
- 6- Gunaseelaraj R, Karthikeyan S, Kumar MN, Balamurugan T, Jagadeeshwaran AR. Custom-made ocular prosthesis. *J Pharm Bioallied Sci*. 2012 Aug;4(Suppl 2):S177-9. doi: 10.4103/0975-7406.100264. PMID: 23066246; PMCID: PMC3467907.

- 7- De Gottrau P, Holbach LM, Naumann GO. Clinicopathological review of 1146 enucleations (1980-90). *Br J Ophthalmol* 1994;78:260-5. [Crossref] [PubMed]
- 8- Koch KR, Trester W, Muller-Uri N, et al. Ocular prosthetics. Fitting, daily use and complications. *Ophthalmologie* 2016;113:133-42. [Crossref] [PubMed]
- 9- Rokohl AC, Koch KR, Adler W, et al. Concerns of anophthalmic patients-a comparison between cryolite glass and polymethyl methacrylate prosthetic eye wearers. *Graefes Arch Clin Exp Ophthalmol* 2018;256:1203-8. [Crossref] [PubMed]
- 10- Rokohl AC, Koch KR, Trester M, et al. Concerns of Anophthalmic Patients Wearing Cryolite Glass Prosthetic Eyes. *Ophthalmic Plast Reconstr Surg* 2018;34:369-74. [PubMed]
- 11- Rokohl AC, Mor JM, Trester M, et al. Rehabilitation of Anophthalmic Patients with Prosthetic Eyes in Germany Today - Supply Possibilities, Daily Use, Complications and Psychological Aspects. *Klin Monbl Augenheilkd* 2019;236:54-62. [PubMed]
- 12- Bohman E, Roed Rassmusen ML, Kopp ED. Pain and discomfort in the anophthalmic socket. *Curr Opin Ophthalmol* 2014;25:455-60. [Crossref] [PubMed]
- 13- Pine NS, de Terte I, Pine KR. An investigation into discharge, visual perception, and appearance concerns of prosthetic eye wearers. *Orbit* 2017;36:401-6. [Crossref] [PubMed]
- 14- Pine NS, De Terte I, Pine KR. Time Heals: An Investigation into How Anophthalmic Patients Feel about Eye Loss and Wearing a Prosthetic Eye. *J Ophthalmol and Vis Sci* 2017;2:1018.
- 15- Pine NS, De Terte I, Pine KR. The Impact of Eye Loss and Prosthetic Eye Wear on Recreational, Occupational and Social Areas of Functioning. *J Ophthalmol and Vis Sci* 2017;2:1016.
- 16- Chin K, Margolin CB, Finger PT. Early ocular prosthesis insertion improves quality of life after enucleation. *Optometry* 2006;77:71-5. [Crossref] [PubMed]
- 17- Pine K, Sloan B, Stewart J, et al. Concerns of anophthalmic patients wearing artificial eyes. *Clin Exp Ophthalmol* 2011;39:47-52. [PubMed]
- 18- Hughes MO, Hughes N. Visual Field Deficits After Eye Loss: What Do Monocular Patients (Not) See? *Insight* 2015;40:11-7. [PubMed]
- 19- Udayshankar V, Mahesh Gowda E, Kumar R V, Jain V. Rehabilitation of ocular defect with hollow ocular prosthesis. *IP International Journal of Ocular Oncology and Oculoplasty*. 2019;5(4):267–70. doi:10.18231/j.ijooo.2019.06
- 20- Azhar IS, Megantara RW, Dahlan A. Custom-made ocular prosthesis for rehabilitation of missing parts of the face: A case report. *Acta Medica Philippina*. 2021;55(8). doi:10.47895/amp.v55i8.2119
- 21- Rokohl A, Trester M, Mor J, Loreck N, Koch K, Heindl L. Customizing a cryolite Glass Prosthetic Eye. *Journal of Visualized Experiments*. 2019;(152). doi:10.3791/60016
- 22- Ariani MD, Dahlan A, Waluyo WH, Subeqi MD. Custom made ocular prosthesis in elderly patients: A case report. *Journal of Applied Pharmaceutical Science*. 2022; doi:10.7324/japs.2023.55831