



Sealing on Carious Tissue (SoCT) in Primary Molars by Zinc-Reinforced Glass Ionomer Cement (ZRGIC) using Finger Pressure Technique: A Preliminary Study

Sunil Babu Kotha^{1,2}, Noura Khalid Alwatban¹, Hissah Abdulaziz almuhrij³, Hanadi Abdullah Alwafi^{1,4}, Azhar Abbas Alabbad¹, Wejdan Melfi Mohammed Alotaibi¹, Abdulrahman Al-Saffan¹, Sreekanth Kumar Mallineni^{6,8*}

¹Pediatric Dentistry Division, Preventive Dentistry Department, College of Dentistry, Riyadh Elm University, Riyadh, Kingdom of Saudi Arabia.

²Department of Pediatric and Preventive Dentistry, Sharad Pawar Dental College and Hospital, Datta Meghe Institute of Medical Sciences (Deemed to be University), Sawangi (Meghe), Wardha-442004, Maharashtra, India Resident (Pediatric Dentistry),

³Prince sultan military Medical city, Riyadh, Kingdom of Saudi Arabia

⁴Pediatric and Special care dentistry, GNP Academy, Jeddah, Saudi Arabia

⁶Pediatric Dentistry, Dr. Sulaiman Al Habib Hospital, Ar RAYYAN, Riyadh 14212, Saudi Arabia

⁷Division for Globalization Initiative, Liaison Center for Innovative Dentistry Graduate School of Dentistry, Tohoku University, Sendai 980-8575, Japan.

⁸Center for Transdisciplinary Research (CFTR), Saveetha Dental College, Saveetha Institute of Medical and Technical Sciences, Saveetha University, Chennai 600077, India

***Corresponding author:** Sunil Babu Kotha, Pediatric Dentistry Division, Preventive Dentistry Department, College of Dentistry, Riyadh Elm University, Riyadh, Kingdom of Saudi Arabia.
Email: sunil.babu@riyadh.edu.sa

Submitted: 10 March 2023; Accepted: 19 April 2023; Published: 13 May 2023

ABSTRACT

Regardless of the numerous causes, children fear the dentist for a variety of reasons, including parental unpreparedness, community influences, previous medical or dental experiences, previous dental settings, injections, dental materials, drill sounds, dental staff, and socioeconomic concerns. Conventionally, the carious tissue is removed using a local anesthetic, rubber dams, and rotational handpieces and it is preferred by the majority of dentists. Traditionally, the dental procedures are unpleasant for youngsters, therefore they avoid them. To evaluate the retention of zinc-reinforced glass ionomer cement (ZRGIC) in primary molars by sealing the carious tissue (SoCT) using the finger pressure technique in uncooperative children. Only healthy, uncooperative children with occlusal carious lesions on primary molars were involved in the study. The study did not include any children who had symptoms from a primary molar carious lesion. The ZRGIC was used by finger pressure technique to seal the occlusal carious lesion in the primary molars. The children were called back for assessments semiannually (6 months) and annually (12 months). Success and failure rates were compared based on molar tooth type and arch type. The SPSS (21.0) was used for the analysis, and the significance level was set at a 5% level of probability with a 95% confidence interval. A total of 108 children aged 5.3 ± 0.6 years with 265 primary molars and no signs or symptoms were available for evaluation in the study. After 6-month and 1-year follow-ups, the ZRGIC-created finger pressure approach for sealing carious tissues showed a high retention rate of 98.5% and 95.5%, respectively.

Among primary first molars, the ZRGIC failure rate was 2.1%, but it was only 1.2% among primary second molars, and retention was 97% among the latter rather than 92.7% among the former. There was a statistically significant difference between the retention rates for semiannual ($p=0.001$) and annual visits ($p=0.005$). At six months, the retention rate for maxillary molars was significantly ($p = 0.001$) higher than that for the mandibular arch. Similarly, a statistically significant difference ($p=0.035$) was found in the percentage of ZRGIC failures in mandibular and maxillary molars after 12 months. The sealing the carious tissue by ZRGIC using the finger pressure method has shown statistically significant success rates at the semiannual (98.5%) and annual (95.5%) follow-up visits. The sealing carious lesions with ZRGIC by using the finger pressure technique can be used in uncooperative children with occlusal carious lesions.

Keywords: *Carious lesion; Glass ionomer cement; Primary teeth; Retention rate*

INTRODUCTION

Despite the fact that there are a variety of causes for children to experience dread while going to the dental operatory [1, 2]. These causes include parental unreadiness, community influences, previous medical or dental experiences, previous dental settings, injections, dental materials, drill sounds, dental teams, and socioeconomic issues [1-3]. According to Wright and Alpern [3,] it is essential to have the understanding that it is not the number quantity of visits that will determine the level of dread, but rather the caliber of the appointments that have come before. The child's level of anxiety is typically connected to their previous painful episodes and their heightened pain perception as a result of inflating their memories [4,5]. The standard method of removing carious tissue involves the use of local anesthetic, the implantation of rubber dams, and rotational handpieces. This method is preferred by the majority of dentists. The child goes through an uncomfortable experience as a result of these processes in traditional approaches, which causes the child to avoid receiving dental care [6-9]. Walsh [8] has the opinion that there are four key factors that increase a child's level of anxiety. It includes little things (such as cutting dentin or using eugenol), sights (such as injections or rotary handpieces), sounds (such as handpieces), and sensations from high-frequency vibrations from rotary equipment. According to the findings of a study carried out in India, the kid was subjected to an unpleasant stimulus as a result of the sound produced by the rotary handpieces [10]. In the 1980s, a technique known as atraumatic restorative treatment (ART) was developed with the intention of overcoming this

preconception. ART involved the use of solely hand tools, avoiding the more traditional application of injection and rotational handpieces [11]. When ART was first implemented into dentistry, paradigm shifts in pediatric clinical practice successfully conquered dental fear [11]. Nonetheless, the use of hand devices continues to cause anxiety for a few younger individuals. Innes et al. [12] advised sealing the carious tissue by putting stainless steel crowns using Hall's approach. The authors observed that only 2% of the crowns failed after five years of follow-ups with the patients.

The application of the ART technique is currently referred to as a non-invasive method for arresting the progression of dental caries and preventing its occurrence. It has two components, the first of which involves sealing caries-prone pits and fissures, and the second of which involves utilizing sealant restorations to repair cavitated dentine lesions [13]. The use of finger pressure is required for the application of an ART sealant, which involves the insertion of a high-viscosity glass ionomer into the pits and fissures [14]. Creating sufficient access to the cavity using hand devices in order to remove soft, completely demineralized, and carious tooth tissue is required to complete an ART restoration. After this step has been completed, the cavity will be filled with an adhesive dental solution, and any remaining pits or cracks will be plugged [15]. An ART sealant is applied by pressing a high-viscosity glass ionomer into the pits and fissures using finger pressure. This provides a seal that is impermeable and hermetic. It is not considered ART to open the cavity with rotary handpiece,

clean it with hand devices, and then restore it using an adhesive restorative material [14], nor is it justified to call it modified ART. The conventional glass polyalkenoate (ionomer) restorative cement (GIC) is the material of choice for both the adjunctive restorative therapy (ART) and the interim therapeutic restoration (ITR) [15]. Its widespread use can be attributed to the fluoride-releasing properties it possesses, such as the capacity to affix itself to enamel and dentine, pulpal biocompatibility, and the ease with which it can be manipulated [15]. The application of the ART method is well established in today's dental practice; for instance, the majority of dentists employ it whenever a temporary restoration is placed in a tooth. To be successful, however, you will need to take the additional step of ensuring that adequate caries removal has been performed. Additionally, the clinician will need training in the use of the technique in order to avoid being accused of supervised negligence for failing to carry out the process in its full extent. This is an essential part of role-playing because it is a prerequisite for success. Recommendations are required for recalling or revisiting persons who have undergone such restorations in order to evaluate the carious lesions clinically and radiographically [16]. This allows for the carious lesions to be evaluated. Patients who suffer from anxiety but who stand to gain from the operation should be gradually transitioned to regular therapy approaches. According to Holmgren and Frencken [17], "ART has functioned as a catalyst for a new way of thinking about dental health care." Although the promotion of oral health through prevention is still considered to be the most important aspect of oral health, the use of the ART method is an essential component in the development of global oral health [18].

Previous research indicated that adding any material to glass ionomer cement (GIC), whether in the form of an element or a particle, improves its biocompatibility and mechanical strength, which is useful when employing GIC in carious lesions [18–21]. This improvement in biocompatibility and mechanical strength is useful when employing GIC in carious lesions. Resin-modified glass ionomers, also known by their abbreviation RMGI, are a type of material that was developed in an effort to improve the

mechanical characteristics of the material, shorten the amount of time it takes for the material to set, and make the material less sensitive to the presence of moisture [22–24]. When compared to normal glass ionomer, resin-modified glass ionomer cement (RMGIC) demonstrated favorable results in both ART and ITR [16]. This was a result of the increased wear resistance provided by RMGIC. It has been asserted that the finger pressure approach is effective, and it is considered to be a method that results in the least amount of damage that is even remotely feasible. Because they are constructed using reinforced materials such as metals, resins, or modified glass, conventional GICs have been shown to have a greater microhardness than RMGICs [16, 23]. This is attributable to the fact that traditional GICs are used. Zinc is added at several points throughout the manufacturing process of contemporary GIC in order to increase the mechanical qualities of the material. This zinc-reinforced glass ionomer cement, also known as ZRGIC, outperforms standard glass ionomer cement (GIC) in terms of its compressive and flexural strengths [25]. The clinicians were able to properly seal the carious tissue using more typical approaches, without first preparing the cavity, and these efforts also provided significant results. In addition, our efforts achieved significant outcomes. There has been no research that focused on evaluating the effectiveness of glass ionomer cement in preventing carious lesions (GIC) using the finger pressure technique. Henceforth, the purpose of the study was to evaluate the retention by zinc-reinforced glass ionomer cement (ZRGIC) in primary molars using the finger pressure technique by sealing the carious tissue (SoCT).

METHODOLOGY

This observational study used a cross-sectional approach and was carried out in Saudi Arabia between September 2020 and September 2021. Prior to the beginning of the study, approval from the Institutional Review Board Riyadh Elm University, Riyadh, Saudi Arabia, was asked for and received to comply with ethical standards. The reporting of this study follows the guidelines in the STROBE statement [26]. The study was conducted among uncooperative children [27]

(Frankl's type 1 and 2), attending the pediatric dentistry department. The teeth ZRGIC using the press finger technique without excavating any carious tissue. The study's sample size was determined using a prevalence rate of 8% [13] as its point of departure. The target level of estimating accuracy was decided at 5%. This study required 252 teeth to have a 95% confidence interval.

Inclusion criteria

1. occlusal carious lesions
2. radiolucency that does not extend beyond the inner third of the dentin.
3. absence of spontaneous pain
4. only primary molars

Exclusion criteria

1. irreversible pulpitis
2. reversible pulpitis
3. tooth mobility
4. pain
5. swelling
6. pathology
7. proximal carious lesions
8. primary incisors and canines

This technique of sealing the carious tissue is a modification of the procedure given by Frencken [28] and Cole and Welbury [29]. Pictures of the procedure (Figure 1) and its effects on carious tissue were shown to the parents (Figure 2). Children were enrolled in the study upon informed consent being signed.

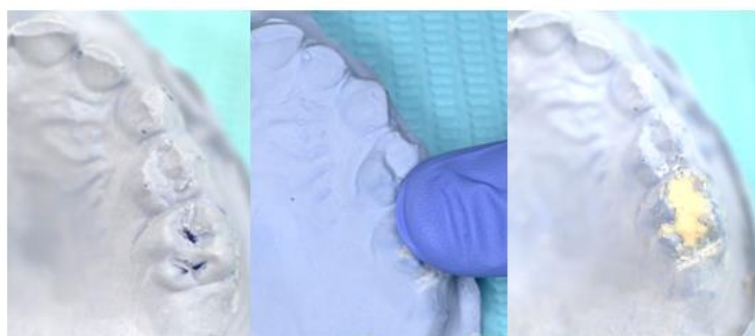


FIGURE 1: Restoration of the carious tooth with glass-ionomer cement using the finger-press technique(Cole and Welbury, 2000).

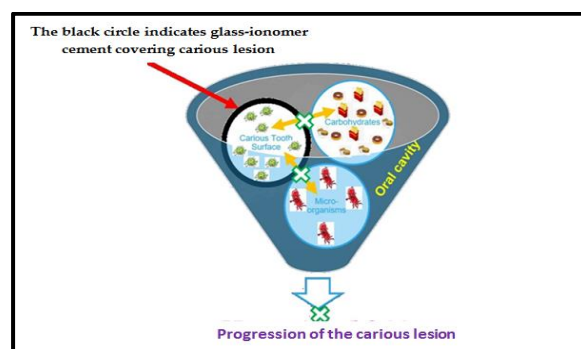


FIGURE 2: A schematic diagram of restoration of the carious tooth with zinc-reinforced glass ionomer cement t using the finger-press technique

This modified technique (Figure 3) was exclusively used for uncooperative children with apprehension towards rotary handpiece sounds

and injections in the dental operator. The steps that were followed in using ZRGIC to seal the carious tissue (SoCT) were mentioned below.

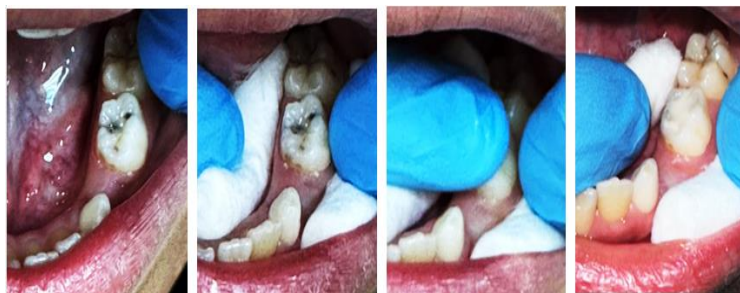

FIGURE 3: Restoration of the carious tooth with zinc modified resin glass-ionomer cement using the finger-press technique.

Step 1: Isolation of the tooth

Step 2: The surface of the carious lesion washed with wet cotton pellets to get rid of any food, then dried cotton pellets. Avoid using the three-way syringe to prevent desiccation and anxiety in young children.

Step 3: The mix of high-viscous ZRGIC zinc-reinforced glass ionomer (ZRGI) sealant material (ChemFil Rock™, Dentsply, York PA, USA) was prepared as per manufacturer instructions

Step 4: Petroleum jelly was applied to the gloved index finger, which was then pressed onto the carious surface of the tooth with the mixed ZRGIC (press-finger technique), followed by sideward removal of the finger after 10-15 seconds.

Step 5: Removal of the excess restoration was done using a carver or large excavator and a place the cotton was placed on the contralateral quadrant to avoid the opposing teeth coming into contact with the GIC.

Upon restoration, the children were requested to bite a cotton roll on the contra lateral side to allow the faster setting of restoration. This is necessary for the GIC to function properly. Molar teeth were taken into consideration for the investigation if they had occlusal carious lesions of class I, respectively. A preventive brush was used to remove the biofilm from the teeth, and subsequently, the teeth were rebuilt using zinc-reinforced GIC (finger-press technique) by SoCT. In addition to this, they were to convince the young children that they should continue to receive the same kind of treatment in the future. All the children were followed up to assess the restoration's capacity to be retained and the degree of marginal defect. an independent

evaluator who was not involved in the operation of the trial and who was also blinded to the study group at the end of six months and 12 months of the study. After six and twelve months had passed, the children were contacted again so that the repair could be assessed for its level of durability. The scheduled appointment for the therapeutic procedure was in September and October 2020. These children were contacted once more in March and April 2021, which was twelve months after the first time they were contacted, which was in September and October 2021. During the two follow-up appointments, the evaluator checked for the presence of restoration, which was one of the criteria for success, along with the patient's lack of complaint regarding pain, swelling, or mobility.

Statistical analysis

The descriptive statistics were carried out using SPSS version 21 (Armonk, NY, USA: IBM Corp.) to compare the success rates and failures of SoCT based on the tooth (primary first molars and primary second molars) and arch type (maxillary arch and mandibular arch). The chi-square test was used for comparison with a 95% confidence interval and a p-value of 0.05.

RESULTS

The sample considered for the study is 108 children with a mean age of 5.3 0.6 years, including 265 restorations in primary molars. The chi-square test showed a significant association between the tooth in general and the outcome (retention) at both the six-month and 12-month

follow-up visits. After 6-month and 1-year follow-ups, the ZRGIC using the finger pressure technique for sealing carious tissues showed a high retention rate of 98.5% and 95.5%, respectively, in primary molars (Table 1). Among primary first molars, the ZRGIC failure rate was 2.1%, but it was only 1.2% among primary second molars in six-month follow-up

visits with statistically significant ($p = 0.001$). While at the 12-month follow-up visit, the retention was 97% among the second primary molars and 92.7% in the first primary molars, respectively. There was a statistically significant difference between the retention rates at the annual follow-up visit ($p = 0.005$).

TABLE 1: Success and failure of zinc-reinforced glass ionomer cement placed by using finger pressure technique among primary molars in semiannual and annual follow-up visits.

Tooth	Six months		P-value	12 months		P-value
	Success	Failure		Success	Failure	
	N (%)	N (%)		N(%)	N(%)	
Primary First Molars	94(97.9)	2(2.1)	0.001*	89(92.7)	7 (7.3)	0.05*
Primary Second Molar	167(98.8)	2(1.2)		164(97)	5(3)	
Total	261(98.5)	4(1.5)		253(95.5)	12(4.5)	

*Statistically significance

There were statistically significantly different retention rates observed between maxillary and mandibular molars at both six months and 12 months follow-up visits; the failure rate was highest among mandibular molars compared to maxillary molars (Table 2). The comparison of the retention of ZRGIC in primary molars based on arch type at six months maxillary molars was significantly ($p = 0.001$) higher than that for the mandibular arch. The success rates of ZRGIC

were 99.1% and 98.1% in maxillary and mandibular molars respectively at six months. Similarly, a statistically significant difference ($p=0.035$) was found in the retention of ZRGIC in mandibular and maxillary molars after 12 months. The retention rates of ZRGIC using the finger pressure technique were 98.2% and 93.5% for maxillary and mandibular molars respectively after 12 months.

TABLE 2: Success and failure of zinc-reinforced glass ionomer cement placed by using finger pressure technique among maxillary and mandibular primary molars in semiannual and annual follow-up visits.

Tooth	Six months		P-value	12 months		P-value
	Success	Failure		Success	Failure	
	N (%)	N (%)		N(%)	N(%)	
Maxillary Molars	110(99.1)	1(0.9)	0.001*	109(98.2)	2(1.8)	0.035*
Mandibular Molars	151(98.1)	3(1.9)		144(93.5)	10 (6.5)	

*Statistically significance

DISCUSSION

The study focused on handling uncooperative and anxious patients and restoring caries with minimal pressure. The method used in this study is novel by using a combination of using zinc reinforced glass ionomer cement using the press-finger technique in uncooperative anxiety patients where there is a balance between methodological integrity and being generalized [30]. A carious lesion is the end consequence of the caries process, which occurs over time and is referred to as the disease "dental caries." The appearance of a carious lesion might vary considerably. Aiming to keep teeth healthy and functioning throughout the duration in children oral cavity, MID is a concept [31,32]. Many studies have been conducted on a wide range of subjects connected to dental caries, including dental biofilm, sugar, fluoride, re-restorations, and adhesive dental materials. These investigations were essential to its development [33]. As early as 1990, studies indicated that treating oral carious lesions using a "biological" or "medical" approach rather than the standard surgical treatment yielded better results. The novel approach to the treatment of carious lesions has been given the name "minimal intervention dentistry (MID)" [34,35]. This method incorporates a number of essential procedures that are designed to protect teeth from developing carious lesions. As can be observed from the various techniques, many dentists were initially under the notion that MID meant cutting smaller cavities than they had in the past [14–16, 31–32]. This is something that can be seen from the varied approaches. If oral health maintenance has been unsuccessful and a cavity has become visibly obvious, a minimally invasive operational intervention should only be carried out. Following this will be a discussion of the atraumatic restorative treatment (ART) strategy and the outcomes of its implementation in dental healthcare [36].

Dental caries can range from a small demineralized spot on the enamel to a well-demarcated cavity in the dentine, with or without pulp involvement [37]. The presence of fermentable carbohydrates, especially free sugars, and the inability to remove the cariogenic bacterial biofilm from a tooth surface sufficiently

and routinely are two major etiological factors influencing the formation and progression of carious lesions [37, 38]. Caries can be avoided if the biofilm of cariogenic bacteria that forms on the tooth's surface is eliminated [39]. Contrary to popular conception, no one microbe is responsible for a dental carious lesion [40–42]. To stop enamel carious lesions from developing into full-fledged cavitation, several non-operative treatment techniques have been developed and evaluated [43]. The use of fluoride in various preparation forms, such as gel, water, varnish, and toothpaste, has been the primary focus of research into treatments for the prevention and management of enamel carious lesions. Because fluoride has been shown to alleviate both of these conditions. Numerous studies have demonstrated that these fluoride therapies are both effective and efficient [44–49]. The other therapy with evidence for the control of enamel carious lesions is the application of a sealer to the vulnerable pits and fissures in the enamel [38]. Several enamel carious lesion-controlling medicines, such as silver diamine fluoride (SDF), chlorhexidine, casein phosphopeptides amorphous calcium phosphate (CPP-ACP), and natural antibiotics, are effective in clinical practice [44–49].

To the best of our knowledge, this study might be the first one to use this way to explore the preservation of restoration with minimum anxiety by employing zinc-reinforced glass ionomer cement on carious tissue. This is what we believe to be the case. Sadly, most children enter adulthood with a negative impression of dentists because of their parents, caretakers, or relatives [50,51]. Children will learn from their parent's experiences, which will make them more nervous about going to the dentist. Therefore, it is the dentist's responsibility to help children feel comfortable enough to return for future dental treatment by delivering that care in a calm, stress-free environment [2,4,10,52]. The treatment for dental caries uses the concept of removing the biofilm and some caries followed by restoration with conventional caries removal [18-21]. Nonetheless, such procedure was not allowed in these uncooperative patients [53,54]. In the present study the authors plan this procedure similar to the concept of Hall crown placement

where the caries lesions are left in situ and sealed along with caries using GIC [12,55,56]. Unlike the Hall technique, sealing carious tissue (SoCT) is also a procedure that involves the placement of GIC on the carious lesion using the press-finger method which is a very comfortable treatment protocol for the uncooperative child. Still, it has a compromised state of being retentive. This new modified method of SoCT is a form of a minimally invasive procedure similar to the concept mentioned by Walsh and Brostek [8] and it helps in preserving as much as tooth structure, unlike GV Black's extension for prevention. The current minimal invasive method aims to protect the tooth by inhibiting the process of demineralization and also creating a self-healing environment by using adhesive and biomimetic material [57]. The GIC is the more biocompatible one, less technique sensitive with superior handling properties, made it use efficiently on carious lesions, and is presently considered under the umbrella of Biomimetic Restorative Dentistry [58]. The release of fluoride is one of the unique qualities of this restorative material, with rapid release initially followed by a sustained lower level of diffusion-based release [59].

The most recent developments in glass ionomer cement, in which zinc was added to highly viscous glass ionomer (HVGIC), have shown promising results in prior in vitro [60,61] and in vivo experiments [28]. It has been reported that the ZRMGIC was developed to evaluate the micro-hardness, toothbrush Abrasions, surface roughness, and fracture toughness of various cement groups [59-62]. Furthermore, the authors concluded that the addition of zinc to the matrix of chemfil rock improves fracture toughness and good abrasive wear but has no effect on micro-hardness or surface roughness [61]. After reviewing the findings of the current research, we believe that the superior retention rate of 90% may be the result of an innovative product that contains zinc-containing glass with accelerated ion release. Furthermore, the incorporation of acrylic acid copolymer into this restoration likely makes it more durable and retentive [62]. In comparison to the earlier research, where the success rate was 99% [63], our investigation on the retention of zinc-reinforced GIC demonstrates that it is only successful about 95%

of the time. Likely, the fact that the authors didn't remove caries in this study contributed to the discrepancy between the two groups in terms of repair depth. In the earlier investigation, both variable sample sizes and hand-mixed GIC were utilized. In a further investigation, the same material (zinc-reinforced GIC) was used to restore many surfaces, and the researchers discovered that after two years, the restoration had a success rate of 85.3%. As compared to class I restorations, which exhibited a high success rate of 95% after only one year, this disparity is understandable and easy to comprehend. As compared to silver diamine fluoride (SDF), a prior study found that GIC was just as efficient in preventing caries after 12 months as SDF was. [64] In the course of our research, we came upon the phenomenon of improved GIC retention [65]. The current study aimed to achieve the contemporary goals of operative management of the restoration as outlined by Banerjee et al. [66] by successfully controlling the formation of biofilm during the restoration of the tooth with fluoride-releasing zinc-reinforced GIC. This was done in place of allowing caries to continue to spread throughout the tooth. In addition to this, it brought back the original form, functionality, and aesthetics [67]. This adhesive material preserved the underlying pulp-dentin complex by preventing caries from occurring. It did this by sealing the coronal area of the restoration, which prevented carbohydrates from reaching the bacteria that were present underneath the restoration. Furthermore, the incorporation of zinc into conventional GIC aids in the prevention of caries; however, the cytotoxicity of restorative materials must be evaluated prior to their use in a variety of dental applications; this is because such applications involve prolonged exposure to and contact with carious tissue, both of which have the potential to bring about cytotoxic reactions over an extended period [68, 69]. The polyacid copolymers and aluminosilicate glass that makeup Glass ionomer cement (GIC) are available commercially on the market. GIC polymers are made of polyalkenoic acids, either a homopolymer of poly(acrylic acid) or a copolymer of acrylic acid and maleic acid. In the past, the majority of the F-containing aluminosilicate glasses that were utilized

belonged to either the SiO₂-Al₂O₃-CaF₂ system or the more complex SiO₂-Al₂O₃-P₂O₅-CaO-CaF₂ system [70]. GICs are biologically active in part because they release biologically active ions into the surrounding aqueous medium at quantities that are advantageous to living organisms. Sodium, phosphate, and silicate are all types of ions that fall into this category [71]. Ion release is a crucial factor in preventing demineralization close to the tooth surface and suppressing the formation of early carious lesions. These two processes are related to each other. This is a very crucial task regarding the release of ions. In point of fact, conventional restoration dramatically reduced the formation of biofilm induced by *S. mutans* when compared to conventional GIC by interfering with the adhesion of bacteria [72]. This was accomplished by inhibiting the growth of *S. mutans*. One of the most striking aspects of the conventional restoration was how, under acidic conditions, the fluoride and zinc ions that were produced in substantial concentrations from the fluoro-zinc-silicate glass portion of the conventional restoration were one of the primary contributors [73, 74,75]. In comparison to amalgam, previous research [76,77] indicated that RMGIC was able to minimize carious margins in one-surface restorations. There is no evidence of significant carious lesions compared to conventional GIC, indicating that teeth restored with RMGIC have no secondary caries [77]. There are some similar features between ART, Hall techniques, and SoCT, but these non-conventional methods also exhibit their distinctive characteristics. This is because its labeled uses specifically mentioned situations where access to oral care facilities was difficult, which is very common. However, SoCT can also be employed as a stopgap measure prior to the execution of a more permanent restoration.

Proper isolation was not possible due to the uncooperativeness of the children who participated in the study. A three-way syringe and cotton pellet were used for isolating the tooth in the study. Maybe proper isolation using cotton rolls or rubber dams might change the success of the technique. A recent systematic review reported that 12-month and 24-month follow-ups were required for atraumatic restorative therapy based on published literature [78], and the

present was a preliminary investigation, and the primary outcomes have been clinically assessed at the 12-month follow-up. It was possible to obtain the pre-treatment radiographs; however, the follow-up radiographs were not used for the evaluation of clinical signs, including pain, swelling, abscess, mobility, and the sinus tract. This is a significant limitation of the present study. Power analysis from previous studies was used to calculate the sample size, which was achieved at 252 and 265 teeth used for the analysis; however, the large sample size was also involved to explain the retention rate of ZRGIC. In the present study, only one component—namely, retention—was taken into consideration, and the association factor between retention and the causes of failure was not observed. This is also a potential limitation of the study. Oral hygiene is one of the key factors associated with dental caries [79, 80], which were not evaluated in follow-up visits, and dentists only focused on restoration. Due to its various benefits, atraumatic restorative treatment is becoming an increasingly popular alternative to conventional therapy. When taking into consideration the severity and progression of dental caries, as well as the significance of early intervention and strategy [80], this treatment option is essential. Unfortunately, there have only been a few studies that have investigated the efficacy of sealing carious tissue in children. This is a limitation of the field. Only SoCT with finger pressure technique was used in the study; no comparisons with conventional treatments were made, which was also considered as a potential limitation. This evidence must be achieved to determine the effectiveness of such procedure using a randomised control trials in comparison to conventional treatment techniques. This is one of the main reasons why the current study is important. Even when utilizing GIC which has increased characteristics, the success rates of ART on one or more surfaces have dropped, ranging from 31 to 76.1% [81–85]. This SoCT technique, which makes use of the finger-press method, has a great deal of potential for restoring teeth in children with challenging behaviors in a short amount of time and with a small amount of anxiety among children who are not cooperative.

CONCLUSION

Within the study limitations, it is concluded that sealing the carious tissue was effective in the management of occlusal carious lesions in primary molars, with an excellent retention rate of ZRGIC restorations, with 6 and 12 months of follow-up visits. The SoCT can be considered a risk-free technique, additional scientific data with high-quality evidence must be obtained through long-term research to evaluate their efficacy.

Informed Consent Statement

Informed consent was obtained from all subjects involved in the study.

Data Availability Statement

The data will be available upon request to the correspondence author

Acknowledgments

Dr. Kotha Sunil Babu presented the part of the study at the International Association of Pediatric Dentistry (IAPD-21) virtual conference.

Conflicts of Interest

The authors declare no conflict of interest.

REFERENCES

- Mallineni S.K., Yiu C. A Retrospective Audit of Dental Treatment Provided to Special Needs Patients under General Anesthesia During a Ten-Year Period. *J. Clin. Pediatric Dent.* 2018;42:155–160. doi: 10.17796/1053-4628-42.2.13.
- Wright, G. Z. and Alpern, G. D. (1971) 'Variables influencing children's cooperative behavior at the first dental visit.', *ASDC journal of dentistry for children*, 38(2), pp. 124–128
- Wright GZ, Feasby WH. The physical aspects of behaviour management. *Ont Dent.* 1977 Feb;54(2):8-10.
- Weisenberg M, Aviram O, Wolf Y, Raphaeli N. Relevant and irrelevant anxiety in the reaction to pain. *Pain.* 1984 Dec;20(4):371-383. doi: 10.1016/0304-3959(84)90114-3.
- Al Absi M, Rokke PD. Can anxiety help us tolerate pain? *Pain.* 1991 Jul;46(1):43-51. doi: 10.1016/0304-3959(91)90032-S.
- Simon AK, Bhumika TV, Nair NS. Does atraumatic restorative treatment reduce dental anxiety in children? A systematic review and meta-analysis. *Eur J Dent.* 2015 Apr-Jun;9(2):304-309. doi: 10.4103/1305-7456.156841.
- Walsh, L. J. Anxiety prevention: implementing the 4 S principle in conservative dentistry', *Auxilliary*, 17(5),2007; pp. 24–26.
- Walsh, L. J. and Brostek, A. M. (2013) 'Minimum intervention dentistry principles and objectives', *Australian Dental Journal*, 58(SUPPL.1), pp. 3–16. doi: 10.1111/adj.12045.
- Muppa R, Bhupatiraju P, Duddu M, Penumatsa NV, Dandempally A, Panthula P. Comparison of anxiety levels associated with noise in the dental clinic among children of age group 6-15 years. *Noise Health.* 2013 May-Jun;15(64):190-3.
- Smales RJ, Yip HK. The atraumatic restorative treatment (ART) approach for primary teeth: Review of literature. *Pediatr Dent.* 2000 Jul-Aug;22(4):294-8.
- Chen KJ, Gao SS, Duangthip D, Lo ECM, Chu CH. Managing Early Childhood Caries for Young Children in China. *Healthcare (Basel).* 2018 Jan 30;6(1):11. doi: 10.3390/healthcare6010011.
- Innes NP, Evans DJ, Stirrups DR. Sealing caries in primary molars: randomized control trial, 5-year results. *J Dent Res.* 2011 Dec;90(12):1405-10. doi: 10.1177/0022034511422064.
- de Amorim RG, Leal SC, Frencken JE. Survival of atraumatic restorative treatment (ART) sealants and restorations: a meta-analysis. *Clin Oral Investig.* 2012 Apr;16(2):429-41. doi: 10.1007/s00784-011-0513-3.
- Schwendicke F, Frencken JE, Bjørndal L, Maltz M, Manton DJ, Ricketts D, Van Landuyt K, Banerjee A, Campus G, Doméjean S, Fontana M, Leal S, Lo E, Machiulskiene V, Schulte A, Splieth C, Zandona AF, Innes NP. Managing Carious Lesions: Consensus Recommendations on Carious Tissue Removal. *Adv Dent Res.* 2016 May;28(2):58-67. doi: 10.1177/0022034516639271.
- AAPD. Guideline on restorative dentistry. *Pediatr. Dent.* 2016, 38, 250–262.
- Holmgren CJ, Roux D, Doméjean S. Minimal intervention dentistry: part 5. Atraumatic restorative treatment (ART)--a minimum intervention and minimally invasive approach for the management of dental caries. *Br Dent J.* 2013 Jan;214(1):11-8. doi: 10.1038/sj.bdj.2012.1175.
- Holmgren CJ, Frencken JE. Conclusions from the symposium: two decades of ART: success

- through research. *J Appl Oral Sci.* 2009;17:134–136. doi: 10.1590/S1678-77572009000700021
18. Frencken JE, Holmgren CJ. Caries management through the Atraumatic Restorative Treatment (ART) approach and glass-ionomers: update 2013. *Braz Oral Res.* 2014;28:5-8. doi: 10.1590/S1806-83242013000600001.
 19. Kidd EA. How 'clean' must a cavity be before restoration? *Caries Res.* 2004 May-Jun;38(3):305-13. doi: 10.1159/000077770.
 20. Lo EC, Luo Y, Fan MW, Wei SH. Clinical investigation of two glass-ionomer restoratives used with the atraumatic restorative treatment approach in China: two-years results. *Caries Res.* 2001 Nov-Dec;35(6):458-63. doi: 10.1159/000047490.
 21. Duangthip D, Chen KJ, Gao SS, Lo ECM, Chu CH. Managing Early Childhood Caries with Atraumatic Restorative Treatment and Topical Silver and Fluoride Agents. *Int J Environ Res Public Health.* 2017 Oct 10;14(10):1204. doi: 10.3390/ijerph14101204.
 22. Song, F.V.; Yang, B.; Di Tommaso, D.; Donnan, R.S.; Chass, G.A.; Yada, R.Y.; Farrar, D.H.; Tian, K.V. Resolving Nanoscopic Structuring and Interfacial THz Dynamics in Setting Cements. *Mater. Adv.* 2022, 3, 4982–4990.
 23. Ong SH, Yoo SH. Surface roughness and chemical composition changes of resin-modified glass ionomer immersed in 0.2% sodium fluoride solution. *J Dent Sci.* 2021 Jan;16(1):389-396. doi: 10.1016/j.jds.2020.07.002
 24. Al-Nahedh HN. Effects of Resin-modified Glass Ionomer Cement and Flowable Bulk-fill Base on the Fracture Resistance of Class II Restorations: An Original Laboratory Experimental Study. *J Contemp Dent Pract.* 2021 Apr 1;22(4):342-348.
 25. Kumar A, Raj A, Singh DK, Donthagani S, Kumar M, Ramesh K. A New Zinc Reinforced Glass Ionomer Cement: A Boon in Dentistry. *J Pharm Bioallied Sci.* 2021 Jun;13(Suppl 1):S272-S275. doi: 10.4103/jpbs.JPBS_730_20.
 26. Vandembroucke JP, von Elm E, Altman DG, Gøtzsche PC, Mulrow CD, Pocock SJ, Poole C, Schlesselman JJ, Egger M; STROBE Initiative. Strengthening the Reporting of Observational Studies in Epidemiology (STROBE): explanation and elaboration. *PLoS Med.* 2007 Oct 16;4(10):e297. doi: 10.1371/journal.pmed.0040297.
 27. Frankl SN (1962) Should the parent remain with the child in the dental operator? *J Dent Child* 29: 150-163.
 28. Frencken JE. The state-of-the-art of ART sealants. *Dent Update* 2014;41:119-20, 122-4
 29. Cole BO, Welbury RR. The atraumatic restorative treatment (ART) technique: does it have a place in everyday practice? *Dent Update.* 2000 Apr;27(3):118-20, 122-3. doi: 10.12968/denu.2000.27.3.118.
 30. Holmgren CJ, Lo EC, Hu D. Glass ionomer ART sealants in Chinese school children-6-year results. *J Dent.* 2013 Sep;41(9):764-70. doi: 10.1016/j.jdent.2013.06.013.
 31. Holmgren C, Gaucher C, Decerle N, Doméjean S. Minimal intervention dentistry II: part 3. Management of non-cavitated (initial) occlusal caries lesions--non-invasive approaches through remineralisation and therapeutic sealants. *Br Dent J.* 2014 Mar;216(5):237-43. doi: 10.1038/sj.bdj.2014.147
 32. Alkhalaf R, Neves AA, Banerjee A, Hosey MT. Minimally invasive judgement calls: managing compromised first permanent molars in children. *Br Dent J.* 2020 Oct;229(7):459-465. doi: 10.1038/s41415-020-2154-x.
 33. Leal SC. Minimal intervention dentistry in the management of the paediatric patient. *Br Dent J.* 2014 Jun 13;216(11):623-7. doi: 10.1038/sj.bdj.2014.449.
 34. Surendranath P, Krishnappa S, Srinath S. Silver Diamine Fluoride in Preventing Caries: A Review of Current Trends. *Int J Clin Pediatr Dent.* 2022;15(Suppl 2):S247-S251. doi: 10.5005/jp-journals-10005-2167.
 35. Araujo MP, Innes NP, Bonifácio CC, Hesse D, Olegário IC, Mendes FM, Raggio DP. Atraumatic restorative treatment compared to the Hall Technique for occluso-proximal carious lesions in primary molars; 36-month follow-up of a randomised control trial in a school setting. *BMC Oral Health.* 2020 Nov 11;20(1):318. doi: 10.1186/s12903-020-01298-x.
 36. Frencken JE, Holmgren CJ. Caries management through the Atraumatic Restorative Treatment (ART) approach and glass-ionomers: update 2013. *Braz Oral Res.* 2014;28:5-8.
 37. Lam PPY, Chua H, Ekambaram M, Lo ECM, Yiu CKY. Risk predictors of early childhood caries increment-a systematic review and meta-analysis. *J Evid Based Dent Pract.* 2022 Sep;22(3):101732. doi: 10.1016/j.jebdp.2022.101732
 38. Abreu-Placeres N, Martinez-Mier EA. Stabilized stannous fluoride (snf2) toothpastes may be effective in the management of hypersensitivity, while more research is needed for its effectiveness in dental caries and erosion prevention. *J Evid Based Dent Pract.* 2021 Dec;21(4):101651. doi: 10.1016/j.jebdp.2021.101651.

39. Moores CJ, Kelly SAM, Moynihan PJ. Systematic Review of the Effect on Caries of Sugars Intake: Ten-Year Update. *J Dent Res.* 2022 Aug;101(9):1034-1045. doi: 10.1177/00220345221082918
40. Sulyanto RM, Kang M, Srirangapatanam S, Berger M, Candamo F, Wang Y, Dickson JR, Ng MW, Ho SP. Biomineralization of Dental Tissues Treated with Silver Diamine Fluoride. *J Dent Res.* 2021 Sep;100(10):1099-1108. doi: 10.1177/00220345211026838.
41. Ha DH, Spencer AJ, Moynihan P, Thomson WM, Do LG. Excess Risk of Dental Caries from Higher Free Sugars Intake Combined with Low Exposure to Water Fluoridation. *J Dent Res.* 2021 Oct;100(11):1243-1250. doi: 10.1177/00220345211007747.
42. Grier A, Myers JA, O'Connor TG, Quivey RG, Gill SR, Kopycka-Kedzierawski DT. Oral Microbiota Composition Predicts Early Childhood Caries Onset. *J Dent Res.* 2021 Jun;100(6):599-607. doi: 10.1177/0022034520979926.
43. James P, Harding M, Beecher T, Browne D, Cronin M, Guiney H, O'Mullane D, Whelton H. Impact of Reducing Water Fluoride on Dental Caries and Fluorosis. *J Dent Res.* 2021 May;100(5):507-514. doi: 10.1177/0022034520978777.
44. Urquhart O, Tampi MP, Pilcher L, Slayton RL, Araujo MWB, Fontana M, Guzmán-Armstrong S, Nascimento MM, Nový BB, Tinanoff N, Weyant RJ, Wolff MS, Young DA, Zero DT, Brignardello-Petersen R, Banfield L, Parikh A, Joshi G, Carrasco-Labra A. Nonrestorative Treatments for Caries: Systematic Review and Network Meta-analysis. *J Dent Res.* 2019 Jan;98(1):14-26. doi: 10.1177/0022034518800014.
45. Twetman S, Dhar V. Evidence of Effectiveness of Current Therapies to Prevent and Treat Early Childhood Caries. *Pediatr Dent.* 2015 May-Jun;37(3):246-53. PMID: 26063553.
46. Ruff RR, Barry-Godín T, Niederman R. Effect of Silver Diamine Fluoride on Caries Arrest and Prevention: The CariedAway School-Based Randomized Clinical Trial. *JAMA Netw Open.* 2023 Feb 1;6(2):e2255458. doi: 10.1001/jamanetworkopen.2022.55458.
47. Bourouni S, Dritsas K, Kloukos D, Wierichs RJ. Efficacy of resin infiltration to mask post-orthodontic or non-post-orthodontic white spot lesions or fluorosis - a systematic review and meta-analysis. *Clin Oral Investig.* 2021 Aug;25(8):4711-4719. doi: 10.1007/s00784-021-03931-7.
48. Wierichs RJ, Wolf TG, Campus G, Carvalho TS. Efficacy of nano-hydroxyapatite on caries prevention-a systematic review and meta-analysis. *Clin Oral Investig.* 2022 Apr;26(4):3373-3381. doi: 10.1007/s00784-022-04390-4.
49. Slayton RL, Urquhart O, Araujo MWB, Fontana M, Guzmán-Armstrong S, Nascimento MM, Nový BB, Tinanoff N, Weyant RJ, Wolff MS, Young DA, Zero DT, Tampi MP, Pilcher L, Banfield L, Carrasco-Labra A. Evidence-based clinical practice guideline on nonrestorative treatments for carious lesions: A report from the American Dental Association. *J Am Dent Assoc.* 2018 Oct;149(10):837-849.e19. doi: 10.1016/j.adaj.2018.07.002.
50. Opydo-Szymaczek, J.; Borysewicz-Lewicka, M.; Andrysiak, K.; Witkowska, Z.; Hoffmann-Przybylska, A.; Przybylski, P.; Walicka, E.; Gerreth, K. Clinical Consequences of Dental Caries, Parents' Perception of Child's Oral Health and Attitudes towards Dental Visits in a Population of 7-Year-Old Children. *Int. J. Environ. Res. Public Health* 2021, 18, 5844. <https://doi.org/10.3390/ijerph18115844>
51. Mika, A.; Mitus-Kenig, M.; Zeglen, A.; Drapella-Gasior, D.; Rutkowska, K.; Josko-Ochojska, J. The child's first dental visit. Age, reasons, oral health status and dental treatment needs among children in Southern Poland. *Eur. J. Paediatr. Dent.* 2018, 19, 265–270
52. Ramazani, N. Child dental neglect: A short review. *Int. J. High Risk Behav. Addict.* 2014, 3, e21861
53. Saatchi M, Abtahi M, Mohammadi G, Mirdamadi M, Binandeh ES. The prevalence of dental anxiety and fear in patients referred to Isfahan Dental School, Iran. *Dent Res J (Isfahan).* 2015 May-Jun;12(3):248-53
54. Nunna M, Dasaraju RK, Kamatham R, Mallineni SK, Nuvvula S. Comparative evaluation of virtual reality distraction and counter-stimulation on dental anxiety and pain perception in children. *J Dent Anesth Pain Med.* 2019 Oct;19(5):277-288. doi: 10.17245/jdapm.2019.19.5.277.
55. Clark W, Geneser M, Owais A, Kanellis M, Qian F. Success rates of Hall technique crowns in primary molars: a retrospective pilot study. *Gen Dent.* 2017 Sep-Oct;65(5):32-35. PMID: 28862586.
56. Innes NP, Evans DJ, Stirrups DR. The Hall Technique; a randomized controlled clinical trial of a novel method of managing carious primary molars in general dental practice: acceptability of the technique and outcomes at 23 months. *BMC*

- Oral Health. 2007 Dec 20;7:18. doi: 10.1186/1472-6831-7-18.
57. Duangthip D, Chen KJ, Gao SS, Lo ECM, Chu CH. Managing Early Childhood Caries with Atraumatic Restorative Treatment and Topical Silver and Fluoride Agents. *Int J Environ Res Public Health*. 2017 Oct 10;14(10):1204. doi: 10.3390/ijerph14101204.
 58. Alkhalaf R, Neves AA, Banerjee A, Hosey MT. Minimally invasive judgement calls: managing compromised first permanent molars in children. *Br Dent J*. 2020 Oct;229(7):459-465. doi: 10.1038/s41415-020-2154-x.
 59. Mobarak EH, Shabayek MM, El-Deeb HA, Mulder J, Hassan FM, Van der Sanden WJM, Frencken JE. Survival of occlusal ART restorations using high-viscosity glass-ionomer with and without chlorhexidine: A 2-year split-mouth quadruple-blind randomized controlled clinical trial. *J Adv Res*. 2019 Jan 31;17:117-123. doi: 10.1016/j.jare.2019.01.015.
 60. Zoergiebel J, Ilie N. Evaluation of a conventional glass ionomer cement with new zinc formulation: effect of coating, aging and storage agents. *Clin Oral Investig*. 2013 Mar;17(2):619-26. doi: 10.1007/s00784-012-0733-1.
 61. Al-Angari SS, Hara AT, Chu TM, Platt J, Eckert G, Cook NB. Physicomechanical properties of a zinc-reinforced glass ionomer restorative material. *J Oral Sci*. 2014 Mar;56(1):11-6. doi: 10.2334/josnusd.56.11.
 62. Kumar A, Raj A, Singh DK, Donthagani S, Kumar M, Ramesh K. A New Zinc Reinforced Glass Ionomer Cement: A Boon in Dentistry. *J Pharm Bioallied Sci*. 2021 Jun;13(Suppl 1):S272-S275. doi: 10.4103/jpbs.JPBS_730_20.
 63. Hermosillo VH, Quintero LE, Guerrero ND, Suarez DD, Hernandez MJ, Holmgren CJ. The implementation and preliminary evaluation of an ART strategy in Mexico: a country example. *J Appl Oral Sci*. 2009;17:114-121. doi: 10.1590/S1678-77572009000700019.
 64. Braga MM, Mendes FM, De Benedetto MS, Imparato JC. Effect of silver diammine fluoride on incipient caries lesions in erupting permanent first molars: a pilot study. *J Dent Child (Chic)*. 2009 Jan-Apr;76(1):28-33.
 65. Nuvvula S, Mallineni SK. Silver Diamine Fluoride in Pediatric Dentistry. *J. South asian Assoc. Pediatric Dent*. 2019;2:73-80.
 66. Banerjee A, Frencken JE, Schwendicke F, Innes NPT. Contemporary operative caries management: consensus recommendations on minimally invasive caries removal. *Br Dent J*. 2017;223(3):215-222. doi:10.1038/sj.bdj.2017.672
 67. Mickenautsch S, Yengopal V. Absence of carious lesions at margins of glass-ionomer cement and amalgam restorations: An update of systematic review evidence. *BMC Res Notes*. 2011 Mar 11;4:58. doi: 10.1186/1756-0500-4-58.
 68. Said, F.; Moeen, F.; Khan, M.T.; Mansoor, A.; Uzbek, U.H.; Alam, M.K.; Siddiqui, A.A. Cytotoxicity, Morphology and Chemical Composition of Two Luting Cements: An in Vitro Study. *Pesqui. Bras. Odontopediatria Clínica Integr*. 2020, 20, 5434.
 69. Mickenautsch S, Yengopal V, Leal SC, Oliveira LB, Bezerra AC, Bönecker M. Absence of carious lesions at margins of glass-ionomer and amalgam restorations: a meta- analysis. *Eur J Paediatr Dent*. 2009 Mar;10(1):41-6.
 70. Czarnecka B, Nicholson JW. Ion release by resin-modified glass-ionomer cements into water and lactic acid solutions. *J Dent* 2006; 34: 539-543.
 71. Krämer N, Schmidt M, Lücker S, Domann E, Frankenberger R. Glass ionomer cement inhibits secondary caries in an in vitro biofilm model. *Clin Oral Investig* 2018; 22: 1019-1031.
 72. Hasegawa T., Takenaka S., Ohsumi T., Ida T., Ohshima H., Terao Y., Naksagoon T., Maeda T., Noiri Y. Effect of a Novel Glass Ionomer Cement Containing Fluoro-Zinc-Silicate Fillers on Biofilm Formation and Dentin Ion Incorporation. *Clin. Oral Investig*. 2020;24:963-970. doi: 10.1007/s00784-019-02991-0.
 73. Naksagoon T., Ohsumi T., Takenaka S., Nagata R., Hasegawa T., Maeda T., Noiri Y. Effect of Water Aging on the Anti-Biofilm Properties of Glass Ionomer Cement Containing Fluoro-Zinc-Silicate Fillers. *Biofouling*. 2020;36:1090-1099. doi: 10.1080/08927014.2020.1856371.
 74. Liu Y., Kohno T., Tsuboi R., Kitagawa H., Imazato S. Acidity-Induced Release of Zinc Ion From BioUnion™ Filler and Its Inhibitory Effects Against *Streptococcus mutans*. *Dent. Mater. J*. 2020;39:547-553. doi: 10.4012/dmj.2019-061.
 75. AlJefri, G.H.; Kotha, S.B.; Murad, M.H.; Aljudaibi, R.M.; Almotawah, F.N.; Mallineni, S.K. Penetration and Adaptation of the Highly Viscous Zinc-Reinforced Glass Ionomer Cement on Contaminated Fissures: An In Vitro Study with SEM Analysis. *Int. J. Environ. Res. Public Health* 2022, 19, 6291. <https://doi.org/10.3390/ijerph19106291>
 76. Drachev SN, Galieva AS, Yushmanova TN, et al. Restorative treatment decisions for carious

- lesions: Do Russian dentists and dental students apply minimal intervention dentistry?. *BMC Oral Health*. 2021;21(1):638. Published 2021 Dec 15. doi:10.1186/s12903-021-01978-2
77. Qvist V, Laurberg L, Poulsen A, Teglers PT. Eight-year study on conventional glass ionomer and amalgam restorations in primary teeth. *Acta Odontol Scand*. 2004 Feb;62(1):37-45. doi: 10.1080/00016350310008689.
78. Pawlaczyk-Kamińska, T.; Torlińska-Walkowiak, N.; Borysewicz-Lewicka, M. The relationship between oral hygiene level and gingivitis in children. *Adv. Clin. Exp. Med*. 2018, 27, 1397–1401.
79. Mickenautsch S, Yengopal V, Banerjee A (2010) Atraumatic restorative treatment versus amalgam restoration longevity: a systematic review. *Clin Oral Investig* 2010;14,233–240. <https://doi.org/10.1007/s00784-009-0335-8>
80. Mallineni, S.K.; Alassaf, A.; Almulhim, B.; Alghamdi, S. Influence of Tooth Brushing and Previous Dental Visits on Dental Caries Status among Saudi Arabian Children. *Children* 2023, 10, 471. <https://doi.org/10.3390/children10030471>
81. Ersin N, Candan U, Aykut A, Önçag Ö, Eronat C, Kose T. A clinical evaluation of resin-based composite and glass ionomer cement restorations placed in primary teeth using the ART approach – results at 24 months. *Am Dent Assoc* 2006, 137,1529–1536
82. van Den Dungen GM, Huddleston Slater AE, van Amerongen WE. ART or conventional restorations? A final examination of proximal restorations in deciduous molars. *Ned Tijdschr Tandheelkd* 2004, 111,345–349
83. Lo E, Holmgren C. Provision of atraumatic restorative treatment (ART) restorations to Chinese pre-school children at 30 month evaluation. *Int J Paed Dent* 2001,11,3–10
84. Honkala E, Behbehani J, Ibricevic H, Kerosuo E, Al-Jame G .The atraumatic restorative treatment (ART) approach to restoring primary teeth in a standard dental clinic. *Int J Pediatr Dent*, 2003, 13,172–179 \
85. van Gemert-Schriks MCM, van Amerongen WE, Ten Cate JM, Aartman IHA (2007) Three-year survival of single- and two-surface ART restorations in a high-caries child population. *Clin Oral Investig* 11:337–343. <https://doi.org/10.1007/s00784-007-0138-8>