



Comparative Evaluation of Wound Healing Outcomes Between Reso-Pac® And Coe-Pak™ following Conventional Gingivectomy

Gopika Gopikrishnan Nair¹, Sharath K. Shetty^{1*}, Anita Kulloli¹, Santosh Martande¹, D. Gopalakrishnan¹, Shweta Kadam¹, Mariam Poulouse¹, Bharath Kumar Ayyanahalli Matta²

¹Department of Periodontology, Dr D.Y. Patil Dental College and Hospital, Dr. D.Y. Patil Vidyapeeth, Pimpri, Pune, India.

²Department of Periodontology, Manipal College of Dental Sciences, MAHE, Manipal, India.

*Corresponding author: Dr. Sharath K. Shetty, Department of Periodontology, Dr D.Y. Patil Dental College and Hospital, Dr D.Y. Patil Vidyapeeth, Pimpri, Pune – 411018,
Email: sharath.shetty@dpu.edu.in

Submitted: 08 March 2023; Accepted: 17 April 2023; Published: 07 May 2023

ABSTRACT

Background: The aim of this present study was to evaluate and compare the efficacy of wound healing outcomes between Reso-Pac® and Coe-Pak™ periodontal dressing following conventional gingivectomy.

Methods: Seven patients undergoing orthodontic treatment with the need for gingivectomy were considered for this study. The patients were randomized into test sites and control sites and the surgical sites were protected by Reso-Pac® and Coe-Pak™ periodontal dressing respectively. Landry's healing index was used to evaluate the postoperative healing outcomes for both sites after 3, 7, 14, 21, and 28 days.

Results: The test site exhibited a median healing index score of 3(3-4) and the control site exhibited a median score of 3(2-3) on the 3rd postoperative day. There was a statistically significant difference between the test sites and control sites on the post-surgical 7th, and 14th days proving Reso-Pac® to be the ideal periodontal dressing to provide faster and superior healing compared to Coe-Pak™ periodontal dressing. Open wounds had been epithelized completely and replaced with new tissue on the 21st and 28th days. Hence, both sites noted similar healing outcomes on the 21st and 28th days, giving a median score of 5 (5-5) each, which was not statistically significant.

Conclusion: Reso-Pac® is an ideal periodontal dressing as it is easy to apply, and provides faster and superior wound healing when compared to Coe-Pak™.

Keywords: *Gingivectomy, Periodontal dressings, Wound healing*

INTRODUCTION

Wound healing is a complex and dynamic process that restores the tissue layers and cellular structure. The secondary union is defined as the healing of large open wounds, with widespread loss of tissues and cells, which cannot be

approximated by surgical sutures.^{1,2,3} It leads to various complications such as large scar formation, intense inflammation, a larger amount of granulation tissue, and pain.^{4,5,6} Gingivectomy, an excisional removal of gingival tissue to

eliminate or reduce periodontal pockets, heals by the secondary union.⁷

Periodontal dressings serve as a protective bandage over the open surgical sites to provide better patient comfort during tissue healing, minimize postoperative pain and protect the site from mechanical trauma.¹ The most commonly used non-eugenol periodontal dressing is Coe-Pak™ (Coe laboratories, GC international Inc, UK). However, it requires manual mixing, does not contain any hemostatic agents, and when set, becomes hard and rough, leading to plaque accumulation. The bulk of Coe-Pak™ can also cause discomfort and hemorrhage.^{7,8} Reso-Pac® (Hager & Werken GmbH & Co. KG, Germany) is an antiseptic, astringent, and hemostatic ready-to-use periodontal dressing that contains cellulose and myrrh extract, a resin obtained from the Commiphoramyrtha wood. 1-6,8 It swells up to a gel-like consistency after 3 minutes due to its hydrophilic property and adheres well to wet and bleeding wounds for about 30 hours. It dissolves within 3 days leaving no residues. It helps in the formation of fibrin on the wound and has a pleasant taste. Its flexible properties relieve the wound from unwanted tension in contrast to Coe-Pak. This ensures extensive protection of the surgical area during the initial stages of wound healing. It has also been shown to possess thermal protection, during the postoperative phase 1-6,8. AN Savitha et al⁷ conducted a study to evaluate the efficacy of Reso-Pac® versus Coe-Pak™ following periodontal flap surgery. Greater mean pain scores, swelling of the face, more inflammation, and delayed wound healing from baseline to 2 weeks were noted in the Coe-Pak™ group when compared to Reso-Pac®.

Landry's Healing Index⁹ measures five postoperative wound healing parameters: Tissue color, bleeding on palpation, presence of granulation tissue, incision margin (epithelialization and connective tissue exposure), and suppuration. Our study is the first of its kind with the longest follow-up of 1 month aimed to evaluate and compare the efficacy of wound healing outcomes between Reso-Pac® and Coe-Pak™ following conventional gingivectomy.

MATERIALS AND METHODS

Patients and setting

This study was conducted from October 2019 to December 2021 in the Department of Periodontology at Dr. D.Y Patil Dental College and Hospital, Pune, Maharashtra. The present study was performed as per the ethical guidelines laid down by the Declaration of Helsinki and approved by the Ethics Committee (DPU/1184/16./2019). All patients were explained about the study, and written informed consent was obtained from each of them. An interventional in-vivo split-mouth design was considered. A convenience sampling technique was used and the surgical sites were divided into Test Sites and Control Sites randomized using the coin toss method. The test site was protected with Reso-Pac® whereas, the control site was protected with Coe-Pak™ after the gingivectomy.

This study included systemically healthy patients aged 18 years or more from both genders undergoing orthodontic treatment requiring gingivectomy. Patients with good oral hygiene maintenance and willingness to comply with all study-related procedures. Pregnant/lactating women, Tobacco usage in any form, History of any systemic diseases like hypertension, diabetes, HIV, radiation therapy, and uncooperative patients were excluded from the study.

Methods

Standard painting and draping of the patient followed by administration of local anesthesia (lignocaine hydrochloride 2% with Adrenaline 1:100000) were done. The pseudo pockets on each surface were explored with a periodontal probe. An external bevel incision was given apical to the points marking the course of the sulcus and was directed coronally to a point between the base of the sulcus and the crest of the bone. Kirkland periodontal knife was used for giving the continuous external bevel incision bevelled at approximately 45 degrees to the tooth surface to recreate the normal festooned pattern of the gingiva on the facial surface. Interproximal tissue release was achieved by Orban periodontal knife. The pseudo pocket was excised using

universal curettes 2R/2L or 4R/4L and then irrigated using saline (Figure 1).

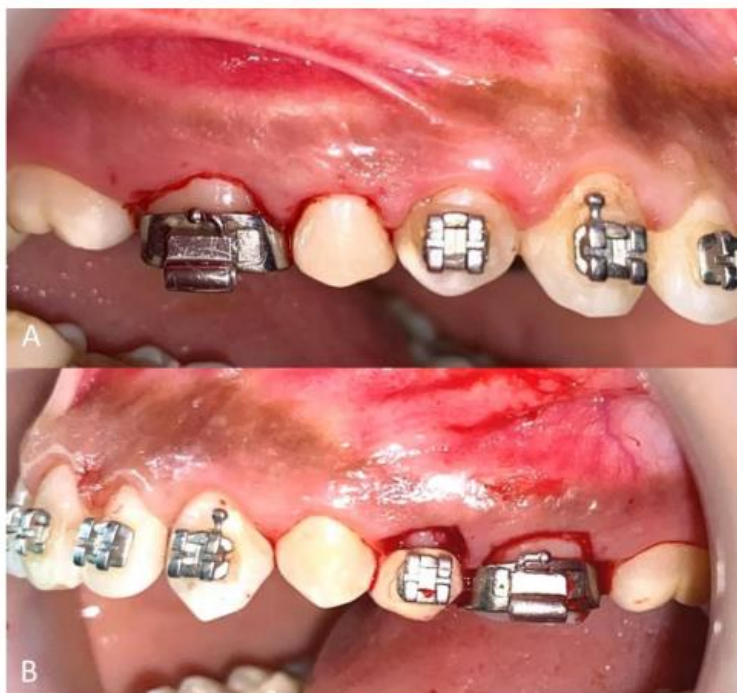

FIGURE 1: Pseudo pocket wall excised following gingivectomy A) Test site (B) Control site.

Gingivoplasty was performed using BP blade #15 and Orban periodontal knife to blend the bulky tissue, present in the buccal/labial and interproximal region (Figure 2).

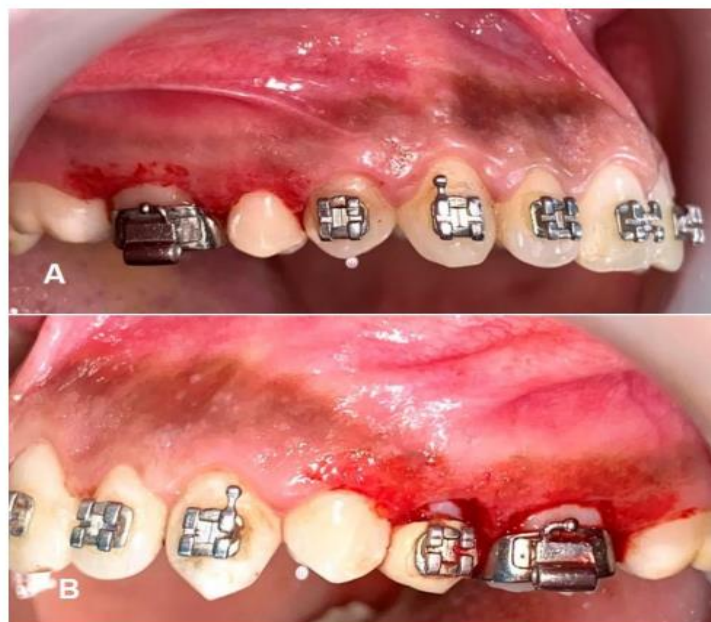

FIGURE 2: The open surgical wound created following Gingivectomy and Gingivoplasty. (A) Test site (B) Control site.

An adequate amount of Reso-Pac® was dispensed from the tube and onto thoroughly moistened gloves (Figure 3).

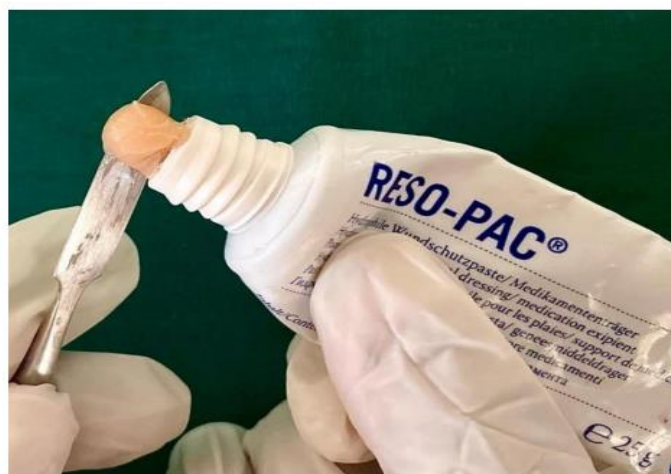

FIGURE 3: Dispensing of Pre-mixed Reso-Pac periodontal dressing

It was then manipulated into a thin roll and applied to the open surgical test site to be protected (Figure 3). For the control site, Coe-Pak™ was dispensed by taking equal streaks of

the base paste and catalyst paste on a glass slab and mixed using a cement spatula until a thick consistency and uniform color were obtained (Figure 4).

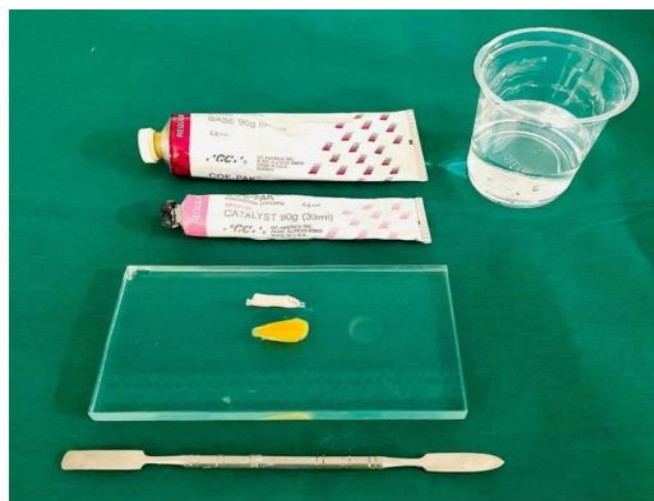

FIGURE 4: Equal streaks of base and catalyst paste of Coe- Pak dispensed on a glass slab

The mixed paste was placed in a paper cup of water at room temperature. Once the paste lost its tackiness, it was handled and moulded using gloves lubricated with water. The pack was

formed into pencil-sized rolls and was bent and fitted around the distal surface of the last tooth mechanically interlocked in the interdental spaces (Figure 5).

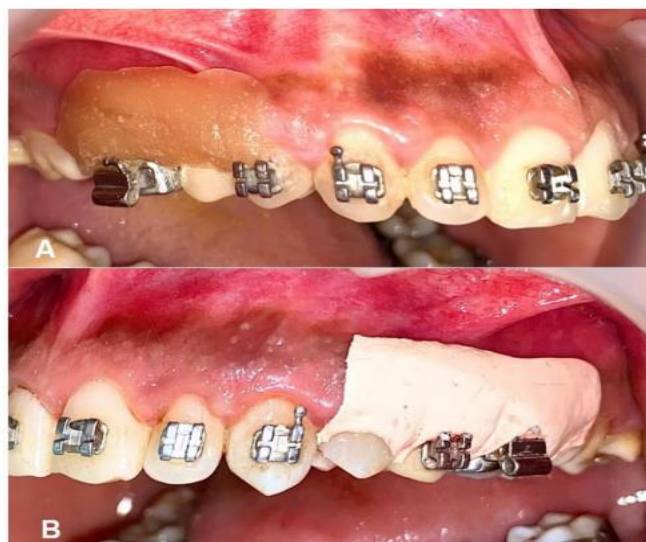

FIGURE 5: Periodontal dressing placed on the open surgical sites (A) Test site protected by Reso-Pac® (B) Control site protected by Coe-Pak™.

Postoperative instructions were given along with the recommendations to refrain from mechanical cleaning of the surgical areas. Patients were prescribed oral analgesic (Ibugesic 600 mg) immediately before the surgery and were advised to continue the same dose for 6 hours post-surgery. They were advised to rinse with 0.2% chlorhexidine mouthwash one-day post-surgery and twice daily for 15 days for oral hygiene maintenance.

Landry's healing index⁹ is one of the most used indexes which has a score from 1 (Very poor) to 5 (Excellent) depending upon the wound healing outcomes. Patients were requested to report back

after three days for evaluation. The test site protected with Reso-Pac® can get dissolved within 3 days postoperatively. Coe-Pak™ on the other hand, does not have the ability to get dissolved and requires manual removal. Hence, Coe-Pak™ applied on the control site was removed for evaluation on the 3rd day, and a new Coe-Pak™ dressing was given. This was retained at the control site until the seventh day. They were requested to be present again on the 7th day (Figure 6), 14th day (Figure 7), 21st day (Figure 8), and 28th day (Figure 9) post-surgically. At each visit, the wound healing outcomes were evaluated for both sites using Landry's healing index⁹.

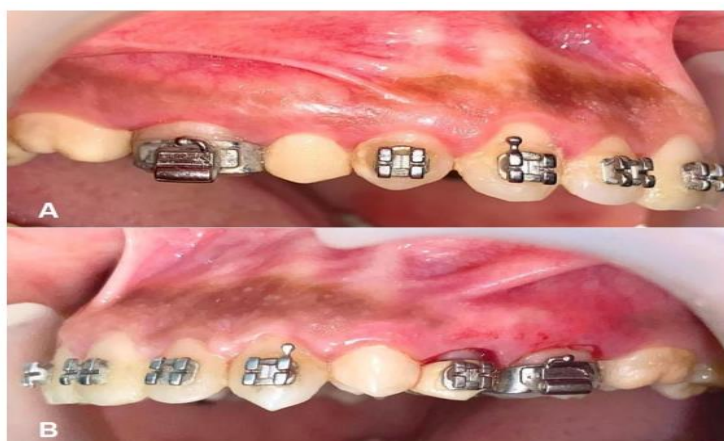

FIGURE 6: Assessment of wound healing on the 7th day (A) Remarkable healing noted on the test site (B) Slight redness still visible on the control site.

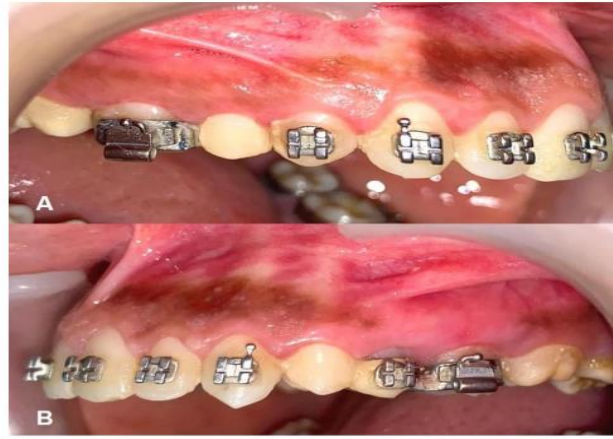


FIGURE 7: Assessment of wound healing on the 14th day (A) Complete healing achieved on the test site (B) Slight inflammation noted on the control site.

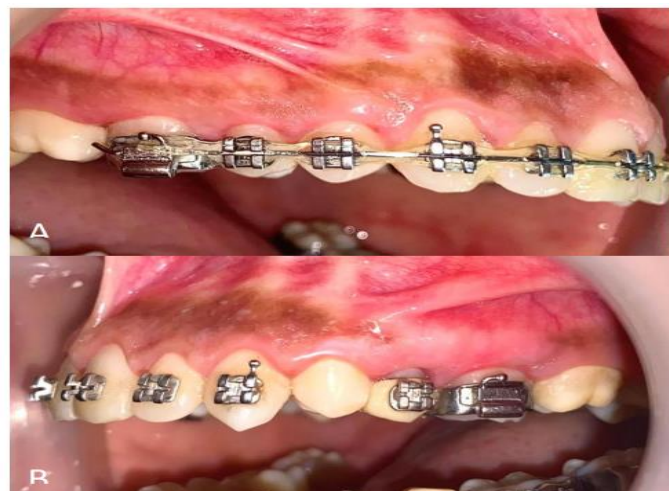

FIGURE 8: Assessment of wound healing on the 28th day. Complete wound healing was noted on both the sites (A) Test site and (B) Control site.

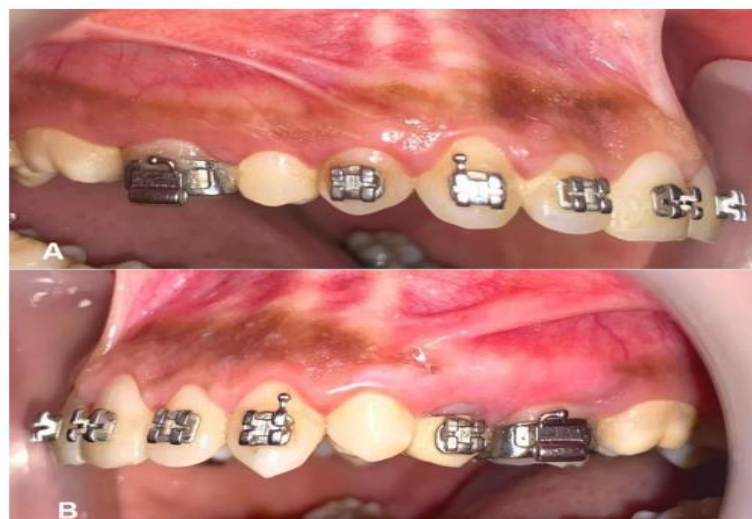

FIGURE 9: Assessment of wound healing on the 28th day. Complete wound healing was noted on both the sites (A) Test site and (B) Control site.

RESULTS

All statistics were done by using the software-Statistical Package for social sciences 21.0 version The significance level was kept at a 95% Confidence Interval and the p-value ($p < 0.05$) was considered for statistical significance. Frequency analysis (number and proportion) of all categorical variables was done. Descriptive Statistics for Mean and Standard Deviation for all continuous variables were obtained and the Mann-Whitney U test was used to compare the change in categorical variables between the two sites. Intragroup comparison of categorical data was done using Freidman pairwise comparison. Paired t-test for within-group comparison at different time intervals was done for continuous variables. Wilcoxon signed-rank test for within-the-group comparison and unpaired t-test for intergroup comparisons for continuous variables were done.

All patients were evaluated for the assessment of wound healing using Landry’s Healing Inex9

during each follow-up visit.

The third day: In the test site, 5 patients exhibited a score of 3 (good) and 2 patients exhibited a score of 4 (very good) giving a median score of 3(3-4). In the control site, 1 patient showed a score of 2 (poor) and 6 patients scored 3 (good) in the control site giving a median score of 3(2-3). This difference in proportion was statistically significant ($p < 0.05$). Therefore, Reso-Pac showed better healing outcomes when compared to Coe-Pak (Table 1).

Seventh day: Six patients scored 4 (very good) and 1 patient scored 5 (excellent) in the test site showing an increased median score of 4(4-5). In the control site, 4 patients exhibited 3 (good) and 3 patients exhibited 4 (very good). The median healing score was increased to 3(3-4). There was a statistically significant ($p < 0.05$) difference in the proportion which further proved Reso-Pac to be the better option than Coe-Pak in terms of better healing outcomes (Table 1).

TABLE 1: Intergroup comparison of the wound healing index scores between the test site and control site.

LANDRY HEALING INDEX SCORES						MEDIAN (Min-Max)	P- VALUE
SITE	1	2	3	4	5		
Healing index score on the 3rd day							
Test	0	0	5	2	0	3(3-4)	0.04*
Control	0	1	6	0	0	3(2-3)	
Healing index score on the 7th day							
Test	0	0	0	6	1	4(4-5)	0.04*
Control	0	0	4	3	0	3 (3-4)	
Healing index score on the 14th day							
Test	0	0	0	0	7	5(5-5)	0.00*
Control	0	0	1	5	1	4 (3-5)	
Healing index score on the 21st day							
Test	0	0	0	0	7	5(5-5)	1.00
Control	0	0	0	0	7	5(5-5)	
Healing index score on the 28th day							
Test	0	0	0	0	7	5(5-5)	1.00
Control	0	0	0	0	7	5(5-5)	

*: Significant at $P < 0.05$

Fourteenth day: All patients revealed a score of 5 (excellent) with a median score of 5(5-5) in the test site whereas, 1 patient scored 3 (good), 5 patients scored 4 (very good) and 1 patient scored 5 (excellent) giving a median score of 4(3-5) in the control site. This difference in proportion was also statistically significant ($P < 0.05$). Therefore, Reso-Pac demonstrated superior healing outcomes when compared to Coe-Pak.

Twenty-first and twenty-eighth day: Both the test and control sites exhibited a healing score of 5 (excellent) respectively, with a median score of 5 (5-5) which was not statistically significant ($P > 0.05$). Therefore, both sites showed similar healing outcomes on the 21st and 28th days.

DISCUSSION

Better healing outcomes were seen in the surgical sites protected by Reso-Pac® when compared to the Coe-Pak™ post-surgically after 3,7 and 14 days. According to Budisidharta et al¹⁰ the mixture of colophony and zinc present in Coe-Pak™ was noted to cause fibroblast cytotoxicity in vitro, which causes the inhibition of new tissue formation during the process of wound healing. In the surgical sites protected with Coe-Pak™ there can be continued inflammatory responses which can happen due to the adverse effects of rosin present in the dressing. The acidic nature of rosin can accelerate the polymorphonuclear cells to trigger the inflammatory process that inhibits the formation of fibroblasts, thereby delaying wound-healing which can be noted as the presence of bleeding when palpated seven days post-operatively on an open surgical site covered by Coe-Pak™. ¹⁰

When open wounds are protected by Coe-Pak™, there can be a disturbance in the oxygen supply which plays a significant role in angiogenesis, fibroblast proliferation, collagen synthesis, production of growth factors, reactive oxygen species, and the inhibition of anaerobic microbial infections due to plaque accumulation. ^{10,11} The wound healing process, seven days after surgery is still in the epithelization process,

angiogenesis, and matrix formation. Therefore, interruption of the oxygen supply can inhibit the healing process. ^{10,11}

Fourteen days post-surgically, the test site's healing index showed better healing than the control site. According to the study done by Gholami et al ¹² granulation tissue formation was less in the Reso-Pac® group which showed better and faster healing. Reso-Pac causes less plaque accumulation once dissolved it accelerates the wound-healing process. On the other hand, the debris and plaque accumulation under Coe-Pak™ dressings causes delayed healing. ¹²

There were no significant differences between both sites on the 21st and 28th day showing similar healing outcomes. This could be mainly attributed to the fact that it had already reached the stages of maturation and remodelling of collagen tissue and matrix deposition. Open wounds had been epithelized completely and replaced with new tissue. ¹⁰ Therefore, the effects of Reso-Pac® were better than Coe-Pak™ during the healing process of open wounds during the gingivectomy procedure.

The rigidity of Coe-Pak™ can cause food lodgment within the dressing leading to plaque accumulation. All these factors can lead to the initiation of bacterial assault into the wounds, where inflammation takes place as a method of self-defence to prevent the spread of bacterial endotoxins. ¹⁰⁻¹² Coe-Pak™ can also lead to hemolysis in the mucosa due to its high toxicity against osteoblasts and gingival fibroblasts.

Reso-Pac® is biocompatible with mucosa and does not cause any interference with the healing process of open wounds as it does not disturb the epithelialization of tissue, angiogenesis, and vascularization and does not initiate extreme inflammatory responses during wound healing. ¹⁰⁻¹⁴ It adheres to the oral tissues for 30 hours before dissolving in saliva preventing the disruption of the oxygen supply required for angiogenesis and preventing plaque accumulation. ¹⁰⁻¹⁴

CONCLUSION

Reso-Pac® is an ideal periodontal dressing as it is easy to apply, and has lesser plaque accumulation, providing faster and superior wound healing when compared to Coe-Pak™. Since this study is the first of its kind with the longest follow-up of 1 month, there is limited literature available regarding the comparison of Reso-Pac® and Coe-Pak™. There is a need for conducting further clinical research studies to adequately analyze and compare different clinical parameters with the above-mentioned periodontal dressings following conventional gingivectomy with a larger sample size.

ACKNOWLEDGEMENT

All authors have contributed substantially to this study and/or manuscript and all have reviewed the final paper before its submission. The authors declare that there are no conflicts of interest and no funding was procured for this work.

REFERENCES

1. Kathariya R, Jain H, Jadhav T. To pack or not to pack: the current status of periodontal dressings. *J Appl Biomater Funct Mater*. 2015;13(2): e73-86.
2. Burke JF. Effects of inflammation on wound repair. *J Dent Res*. 1971;50(2):296-303.
3. Flores-de-Jacoby L, Mengel R. Conventional surgical procedures. *Periodontol* 2000. 1995;9:38-54.
4. Mohan, Harsh. *Textbook of Pathology*. New Delhi: Jaypee Brothers, 2000.
5. Guo S, Dipietro LA. Factors affecting wound healing. *J Dent Res*. 2010;89(3):219-29.
6. Wikesjö UM, Nilvéus RE, Selvig KA. Significance of early healing events on the periodontal repair: a review. *J Periodontol*. 1992;63(3):158-65.
7. AN Savitha, Christopher S, Soumik B. Reso Pack™- A Novel Periodontal Dressing in Comparison with Coe-Pak: A Clinical Study. *I J Pre Clin Dent Res* 2015;2(1):32-37.
8. Frisch J, Bhaskar SN. Tissue response to eugenol-containing periodontal dressings. *J Periodontol*. 1967;38(5):402-8.
9. Pippi R. Post-Surgical Clinical Monitoring of Soft Tissue Wound Healing in Periodontal and Implant Surgery. *Int J Med Sci*. 2017 Jul 18;14(8):721-728.
10. Budisidharta, Y., Syaify, A., & Lastianny, S. (2020). The effects of zinc oxide non- eugenol and cellulose as periodontal dressings on open wounds after periodontal surgery. *Dental Journal (Majalah Kedokteran Gigi)*, 53(1), 45-49.
11. Kumar MBV, Narayanan V, Jalaluddin M, Almalki SA, Dey SM, Sathe S. Assessment of Clinical Efficacy of Different Periodontal Dressing Materials on Wound Healing: A Comparative Study. *J Contemp Dent Pract*. 2019;20(8):896-900.
12. Gholami L, Ansari-Moghadam S, Sadeghi F et al. Clinical and Cytotoxic Comparison of Two Periodontal Dressings after Periodontal Flap Surgery. *World J Dent* 2019;10(1):7-13.
13. Raghavan SL, Panneerselvam E, Mudigonda SK, Raja KKVB. Protection of an intraoral surgical wound with a new dressing: a randomised controlled clinical trial. *Br J Oral Maxillofac Surg*. 2020;58(7):766-770.
14. Sachs HA, Farnoush A, Checchi L, Joseph CE. Current status of periodontal dressings. *J Periodontol*. 1984;55(12):689-96.
15. Kadam S, Kulloli A, Shetty SS, Martande SS, Nair G, Poulouse M, Guruprasad M, Mehta V. Comparative Evaluation of Efficacy of Antibiotics incorporated Platelet Rich Fibrin Versus Platelet Rich Fibrin alone in the Treatment of Intra-bony Defects. *J Popul Ther Clin Pharmacol Vol* 30(2):e267–e274.