



## Pain Management of Pecto-intercostal Fascial Block Versus Intravenous Fentanyl after Pediatric Cardiac Surgery

Sameh Ghareeb Ahmed<sup>1</sup>, Mohamed Abdallah Salama<sup>1\*</sup>, Mohamed -Adel Fetouh Elgamal<sup>2</sup>, Mohamed Abdelatif Ghanem<sup>1</sup>, Enas Aly Abd Elmotlb<sup>1</sup>

<sup>1</sup>Department of Anesthesia and Surgical Intensive Care, Faculty of Medicine, Mansoura University, Mansoura, Egypt.

<sup>2</sup>Department of cardiothoracic surgery, Faculty of Medicine, Mansoura University, Mansoura, Egypt.

\***Corresponding author:** Mohamed Abdallah Salama, Department of Anesthesia and Surgical Intensive Care, Faculty of Medicine, Mansoura University, Mansoura, Egypt, Email: moohamed\_615@yahoo.com

**Submitted: 27 March 2023; Accepted: 19 April 2023; Published: 04 May 2023**

---

### ABSTRACT

**Study objective:** The intent of this investigation is to ascertain the usefulness of pectointercostal fascial block in decreasing intraoperative opioids consumption in non-cyanotic pediatric patients undergoing elective cardiac surgery. Secondary objectives include intra - operative hemodynamic reaction to stress surgical stimuli. Design: a single blinded, prospective, randomized, controlled trial study.

**Setting:** Mansoura university children hospital (MUCH).

**Patients:** Intravenous fentanyl (control group) (n=40): Patients received only intravenous fentanyl analgesia. Pecto intercostal fascial block group (experimental group) (n=40): Cases underwent 0.3 mL/kg bupivacaine 0.25% with an optimum dose of 2 mg/kg that was injected into pecto-intercostal space.

**Measurements and main results:** show that significant lower pain score among group with Pecto-intercostal group than control group at 2, 6, 12, 18 & 24 hours without statistically significant difference at 1 hour. Comparing pain score within each group with 1 hour shows statistically significant decrease during follow up and show that there is statistically significant higher total intraoperative consumption fentanyl among control than Pecto-intercostal group (145 versus 70) and statistically significant higher total postoperative 24 hours fentanyl consumption among control than pecto-intercostal group (100 versus 50 mic).

**Conclusions:** We might then assume that using a single shot PIFB in children enduring cardiac operation via median sternotomy is connected with stable intraoperative hemodynamics, lower perioperative opioid analgesic necessities, and reduced pain severity in the 1st twenty four hours after surgery.

**Keywords:** *Ultrasound Guided; Pectointercostal Fascial Block; Fentanyl; Pain; Pediatric Cardiac surgery*

## INTRODUCTION

Patients undergoing cardiac operation frequently experience intense Pain at the median sternotomy location after surgery. The pain following cardiac surgery is at its worst on the 1st day & then steadily subsides throughout the following several days. Systemic opioids have been the mainstay for the treatment of pain in children following median sternotomy for cardiac surgery during the perioperative timeframe. 1

In paediatric cardiac surgery, The suggested pre-bypass fentanyl dosage for reduce the hemodynamic and metabolic stress reaction is between twenty five- fifty  $\mu\text{g}/\text{kg}$ . 2

In order to achieve early extubation, today it is common to use lower doses. There is no assurance that the stress reaction will be absolutely eliminated at these doses. Utilizing local anaesthetic techniques is one solution to this problem. These methods can inhibit afferent signals from nerves that correlate, thereby reducing or eliminating the demand for opioids. 3

Regional anaesthetic techniques reduce pain in paediatric cardiac surgery cases for up to twenty-four hrs. Central neuraxial blockade, including spinal 4, epidural 5, and caudal blocks Sendasgupta et al., 6 have been utilised but have not attained widespread acceptance owing to concern about possible connected complications in heparinized cases, particularly epidural hematoma.

De la Torre first defined Pecto intercostal fascial block (PIFB) in breast operation patients. This innovative method inhibits the anterior cutaneous nerve, a section of the intercostal nerve that supplies the skin, soft tissue, and sternum with sensory information. A local anaesthetic can be administered amongst the pectoralis major & intercostal muscles to perform PIFB. PIFB is not related to nerve damage, dural puncture, or epidural hematoma, unlike neuraxial blockade.7

The study hypothesis is that pectointercostal fascial block can provide impactful analgesia for paediatric cardiac surgery cases.

The goal targeting of the present research is to assess impact of PIFB in reducing intraoperative opioid consumption in non-cyanotic paediatric

patients undergoing elective cardiac surgery. The secondary objectives are intraoperative hemodynamic strain reaction to surgical stimuli, analgesic utilisation in the researched groups, cross clamping and bypass time, period of extubation, Time spent in intensive care, and after surgery consequences.

## MATERIAL AND METHOD

After receiving consent from Mansoura Faculty of Medicine Institutional Research Board about the current research code Number MD.21.04.462 which is a single blinded, prospective, randomized, and controlled experimental. This investigation took place in Mansoura university children hospital (MUCH). The patient's guardian's written consent was obtained with their knowledge. The anticipated length of this study is 1 year. The research duration was from August 2021 to August 2022. The protocol was registered in clinical trial on 30/6/2021 Number (NCT04945694) Participants in the investigation according to inclusion and exclusion criteria:

**Inclusion criteria:** This research was performed on 80 pediatric patients of either sex with their age spanning the ages of 2 & 12 submitted for on pump optional repair of congenital simple left to right intra cardiac shunt via median sternotomy.

**Exclusion criteria:** Cases were excluded from the present research if their guardians refused participation, redo cardiac surgery, previous back injury or surgery, which precluded the performance of needle puncture, kyphoscoliosis, local infection of the skin & subcutaneous tissue at the injection site, hypersensitivity to local anaesthetics, coagulation disorders, renal, hepatic, or pulmonary illness, heart failure, and mild to severe pulmonary hypertension.

**Randomization & blindness:** The study was single blinded and the subjects were allocated randomly to 1 of 2 equal groups (pectointercostal group & intravenous group) using closed sealed envelope method containing computer generated randomization members

**Intravenous fentanyl (control group) (n=40):** Patients received only intravenous fentanyl analgesia.

Pecto intercostal fascial block group (experimental group) (n=40): Cases received 0.3 mL/kg bupivacaine 0.25% with an optimum dose of 2 mg/kg that was injected into pecto-intercostal space

### METHODS

Every case was forced to submit to a preoperative evaluation consisting of a clinical examination, imaging, and lab testing. Lab examinations will include a CBC, serum electrolytes, arterial blood gas, urine analysis, coagulation profile, blood Glu level, & trials of liver and renal function. ECG, transthoracic echocardiogram, and chest radiograph were performed, serum cortisol which was done basal at 8 AM clock at day of operation and 1 hour postoperative

All patients fasted for six to eight hours before their scheduled procedure. Patients were pre-medicated with intramuscular 0.1 mg/Kg midazolam Induction of general anesthesia using sevoflurane mask targeting MAC > .6 then an intravenous line was inserted and an arterial catheter was inserted into femoral artery Standard monitoring wasgin with ECG, non-invasive blood pressure monitoring (NIBP) and pulse oximetry.

Anesthesia was prompted with sevoflurane 2%, fentanyl (3µg/kg i.v) & rocuronium (0.9 mg/kg I.V) was used to enable tracheal intubation. Mechanical ventilation started using pressure-controlled mode (PCV) to sustain an end-tidal co2 of 30-35 mmHg. After administering anaesthesia, the right internal jugular vein was catheterized with a central venous catheter.

Sustaining anaesthesia required 40% oxygen in air and inhalational sevoflurane (1%-3%) targeting MAC> .6 and increments of rocuronium (0.3 mg/kg/hour) as required. Blood pressure and heart rate were maintained in (80 - 100 %) of their baseline values. Incremental doses of fentanyl (3µg/kg) were given if the rise in systolic arterial blood pressure and/or heart rate was greater than 20percent above baseline. Intravenous fluids were given per body weight and according to intraoperative loss. We maintained hemoglobin around 10 gm% in the peri-operative period.

Pecto intercostal fascial block was done after induction, A high-frequency linear probe of general electric (GE) was situated perpendicular to the longitudinal axis of the sternum on the lateral border & screened laterally in order to designate the fourth & fifth costal cartilage. Identification was performed on the pectoralis major muscle, intercostal muscle, transversus thoracis muscle, ribs, and pleura. Color Doppler ultrasonography was used to determine perforating branches of internal thoracic artery, which travel anteriorly through the anterior chest wall, piercing the intercostal muscle and PMM. A 22G, 50 mm peripheral block needle was inserted in plane with ultrasound probe, in caudal-to-cranial direction until the tip is positioned in interfascial plane between the Pectoralis major muscle and intercostal muscle. Normal saline was used to determine correct placement of needle tip in interfascial plane, as shown by separation of fascial layers then local anesthetic will be injecte. Figure 1

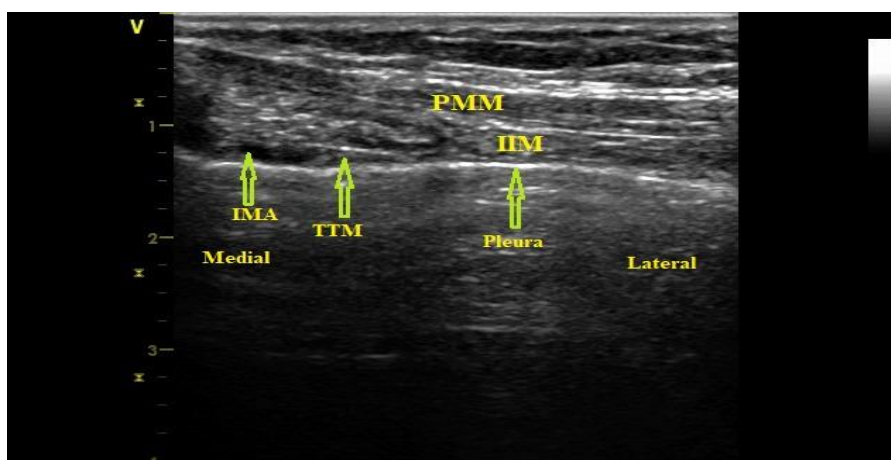
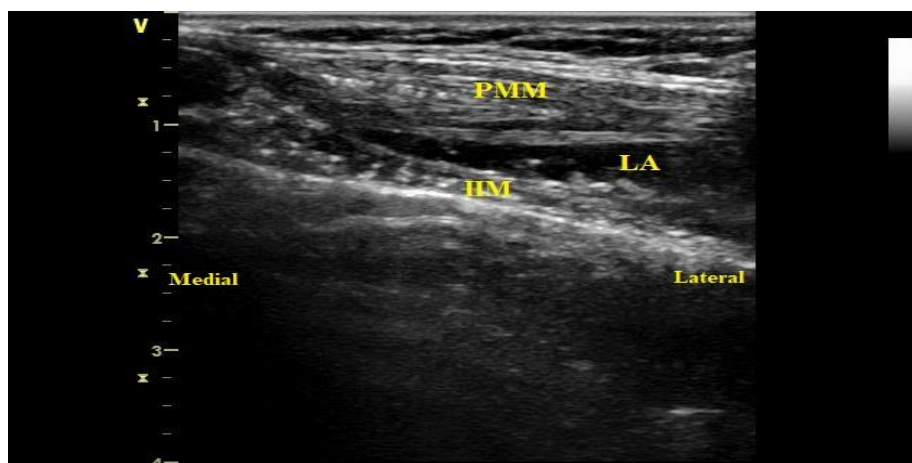


FIGURE 1 (A)



**FIGURE 1 (B)**

Figure 1 (a, b) from our cases Figure 1 (a) showing introducing needle between pectoralis major muscle and intercostal muscle Figure 1 (b) showing diffusion of local anesthetic between between pectoralis major muscle and intercostal muscle

In all patients, a typical median sternotomy is used to access the heart. The ascending aorta, superior vena cava, and inferior vena cava were inserted into a vein for cardiopulmonary bypass (CPB) using a membrane oxygenator & a roller pump with an arterial line filter when the activated clotting time (ACT) was greater than 480 seconds after complete patient heparinization with heparin (300-400) i.u/kg. Perfusion consisted of a non-pulsatile pump flow with an average rate among (100- 150) ml/kg/min.

Hematocrit was preserved among 25-30% during CPB, by incorporating blood as necessary and anesthesia was sustained by propofol infusion [200 mg diluted in 100 ml dextrose 5%] (50-200)ug/kg/min after applying 2 mg/kg to the CPB prime. Near ending of completing the repair of cardiac defects, rewarming commenced and the aortic cross-clamp was eliminated after withdrawal air bubbles from the heart. Ventilation started when the heart /start ejecting blood, after fulfilling the criteria of weaning from CPB, patients were separated from bypass and protamine were administered to reverse heparin. Postoperative care for all cases was standardized & serum cortisol level was measured 1 hour postoperative.

Recovery: Extubation performed at the earliest acceptable clinical time. In ICU, each child who was enrolled in the research followed for 24 hours postoperatively.

#### **Data collection**

The primary outcome (composite outcome): post-operative pain that was assessed at 1h, 2h, 6h, 12h, 18, 24 after extubation, and was managed according to modified objective pain score (OPDS) in children.

The Secondary outcome measures: Basal & one-hour post-operative serum cortisol levels. HR and invasive mean arterial blood pressure [MAP] was recorded; prior to induction of anaesthesia (baseline), after induction of anaesthesia, after skin incision, after sternotomy, fifteen min after CPB, and after sternum closure, time of first rescue analgesia was reported.

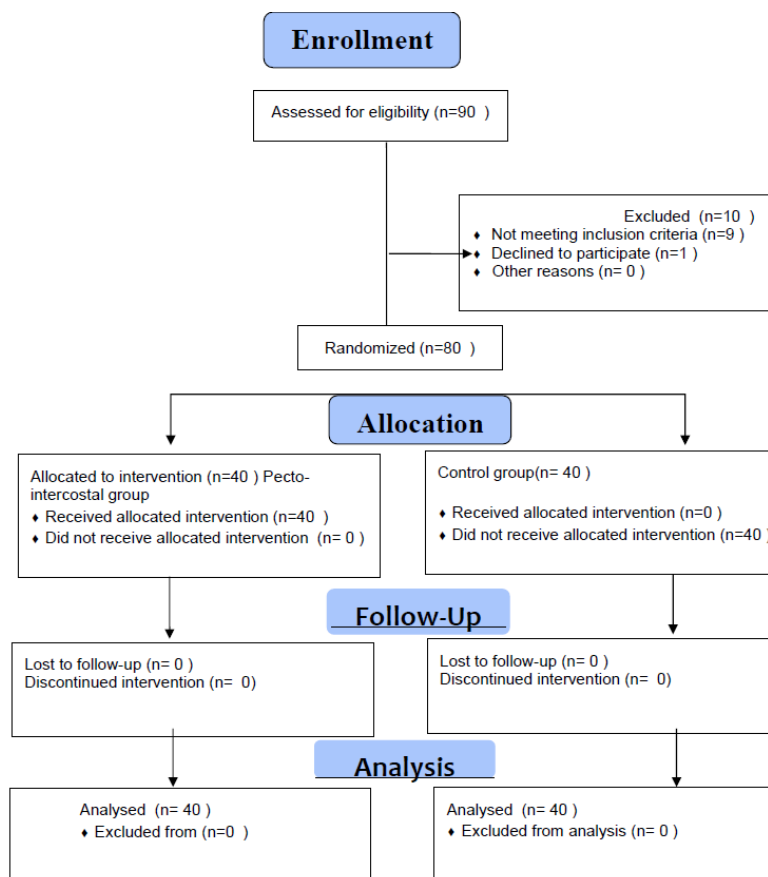
Statistical analysis: Version 22 of SPSS (statistical programme for social sciences) will serve to examine the data. Quantitative data will be examined for normality using the Kruskal-Wallis test and as stated by the mean and SD for data with a normal distribution and the median and range for non-normally distributed data. The proper statistical test will be applied based on the kind of data using the following tests: The Chi-Square test for categorical variables, the Student t test, and the Mann-Whitney U test.

**RESULTS**

The current research was a single-blinded, prospective, randomised, randomized study conducted at MUCH to determine the usefulness of PIFB in reducing after surgery pain in non-cyanotic paediatric cases undertaking a voluntary cardiac operation. The primary objectives of this

randomised research were to contrast the after surgery pain score in the 1st postoperative 24hrs & to determine the total dose of fentanyl required.

Figure (2) show the flow chart of our study design



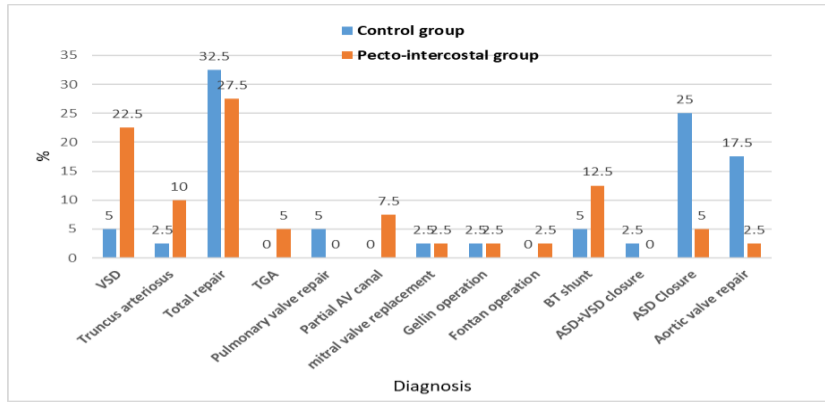
**FIGURE 2:** Consort flow chart of our study design

**TABLE 1:** demographic characteristics of the studied groups

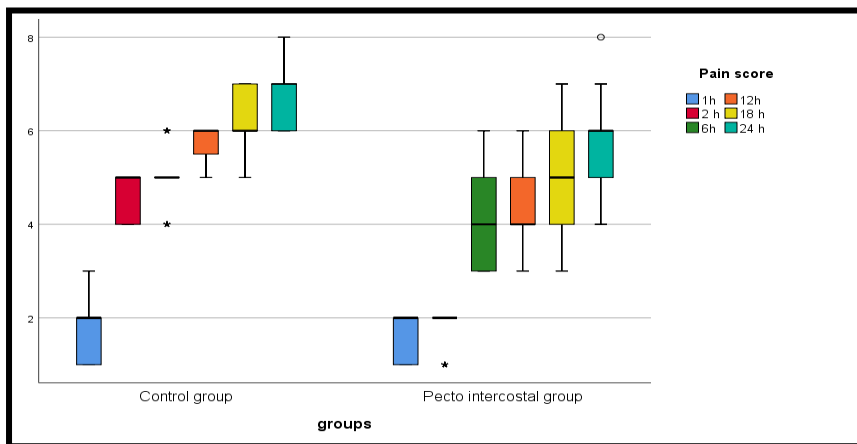
	Control group N=40	Pecto-intercostal group N=40	t/ $\chi^2$	P- value
Age/years mean±SD	5.38±2.63	4.85±2.94	0.843	0.402
Sex				
Male	15(37.5)	21(52.5)	1.82	0.178
Female	25(62.5)	19(47.5)		
Weight/kg mean±SD	18.55±6.69	15.90±6.93	1.74	0.086

t: Student t test  $\chi^2$ :Chi-square test

Table (1) demonstrates that there is no statistically substantial distinction among the groups investigated as regard their age, sex and weight.



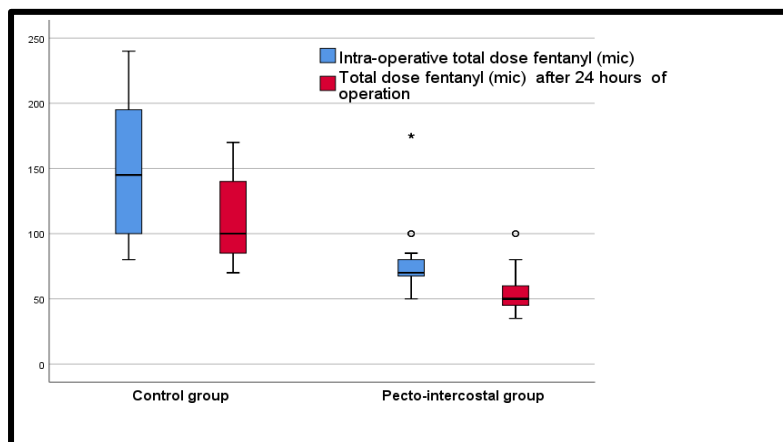
**FIGURE 3:** diagnosis distribution among studied groups is found among 22.5% of the pecto-intercostal group versus 5% among control group, ASD closure & aortic valve repair are detected among 25% & 17.5 of the control group versus 6.27 & 5% of the pecto-intercostal group.



**FIGURE 4:** pain score distribution among studied groups.

Figure 4 show statistically significant lower pain score among group with Pecto-intercostal group than control group at 2, 6, 12, 18 & 24 hours

without statistically significant difference at 1 hour .Comparing pain score within each group with 1 hour shows statistically significant decrease during follow up.



**FIGURE 5:** Total dose fentanyl distribution among studied groups.

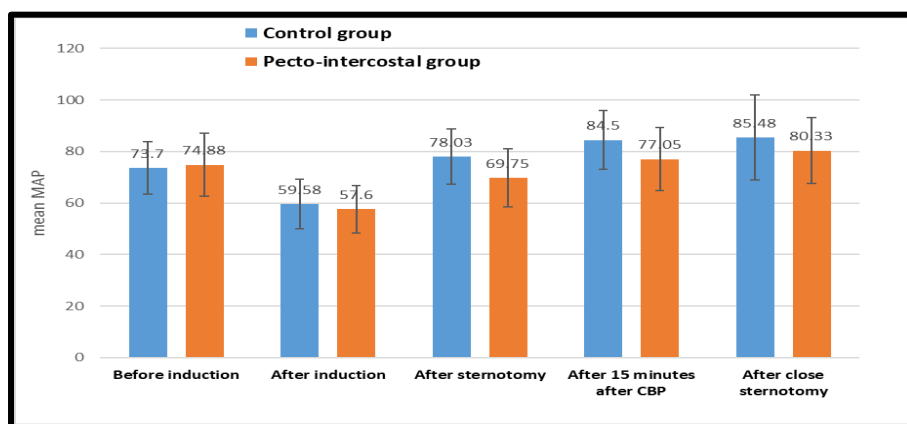
Figure 5 show that there is statistically significant higher median total intraoperative fentanyl consumption among control than Pecto-intercostal group (145 versus 70) and statistically significant higher median total postoperative 24 hours fentanyl consumption among control than pecto-intercostal group (100 versus 50 mic).

**TABLE 2:** comparison of serum cortisol between studied groups

Serum cortisol (mcg/dl)	Control group N=40	Pecto-intercostal group	t	P- value
basal	12.90±1.97	13.68±2.39	1.58	0.118
1 h	31.62±1.71	32.0±2.19	0.853	0.396

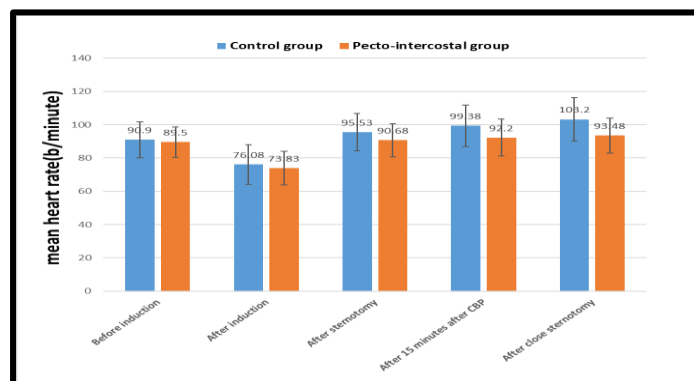
t:Student t test , \*statistically significant

Table 2 demonstrates that there is no statistically substantial distinctions among the groups and after 1 hour follow up. investigated as regard serum cortisol at baseline



**FIGURE 6:** mean MAP distribution among studied groups.

Figure 6 demonstrates a statistically substantial increase mean MAP after sternotomy and after 15 minutes after CBP among control versus pecto-intercostal group (78.03 versus 69.75) and (84.50 versus 77.05). Comparing MAP within each group with before induction shows statistically significant increase during follow up.



**FIGURE 7:** mean heart rate distribution among studied groups. Figure 3 shows that VSD

Figure 7 shows that There is no substantial statistical variance of mean heart rate before and after induction between studied groups ( $p>0.05$ ) while there is statistically substantial increase mean heart rate amongst control than pectoral

group from after sternotomy to after 15 minutes to after close sternotomy. Comparing heart rate within each group with before induction shows statistically significant increase during follow up.

**TABLE 3:** Comparison of post-operative complications

Post-operative complications	Control group N=40	Pecto-intercostal group N=40	P value
reintubation	3(7.5)	2(5.0)	$\chi^2_{FET}=0.213$ P=0.644
N/V	2(5.0)	1(2.5)	$\chi^2_{FET}=0.346$ P=0.556
Resp dep	0	0	....
pruritus	1(2.5)	0	$\chi^2_{FET}=1.01$ P=1.0
neuro def	1(2.5)	0	$\chi^2_{FET}=1.01$ P=1.0

t:Student t test ,  $\chi^2$ :Chi-square test \*statistically significant

Table (3) demonstrates that there is no statistically substantial distinction among the groups investigated as regard post-operative complications with 5% of the pecto-intercostal group have re-intubation, 2.5% nausea & vomiting versus higher rate of complications among control group; 7.5% re-intubation, 5% nausea & vomiting, 2.5% pruritis & neurological deficit.

### DISCUSSION

PIFB is a novel block in which the local anesthetic is being injected under ultrasound in the fascial plane amongst the pectoralis major muscle and intercostal muscle which targets the anterior intercostal nerves as they arise on each side of the sternum from the fascial plane among the pectoralis major muscle and intercostal muscle 8.

The purpose of this investigation is to examine the effectiveness of PIFB in decreasing intraoperative opioids consumption in non-cyanotic pediatric patients undergoing elective cardiac surgery. The secondary objectives hemodynamic, analgesic use in the examined groups, cross clamping & bypass time, timing of

extubation, length of critical care stay, and after surgery sequelae.

As regard fentanyl consumption there is statistically significant higher median dose of total fentanyl dose among control than Pecto-intercostal group and statistically significant higher median total dose of fentanyl among control than pecto-intercostal group due to blockage of anterior intercostal nerves and decrease pain of operation.

In line with our study as regard analgesic outcome Zhang et al., 9 Demonstrated through study on 110 patients to identify the perioperative pain treatment with bilateral PIFB in paediatric cases undergoing heart operation that Bilateral PIFB in paediatric open cardiac surgical cases give excellent analgesia & decrease the length of hospitalisation.

And AAGPS et al., 10 demonstrated that Compared to other regional analgesia techniques, bilateral PIFB is considered as an easy procedure and may provide safe and effective pain management for median sternotomy, particularly in pediatric population, which in turn improves patient satisfaction, clinical outcomes, minimize pain- and opioid-related postoperative adverse events. Several advantages of PIFB may increase



the application of regional analgesia in children. However, further research is needed to confirm safety and effectiveness of PIFB in pediatric population.

In contrary with our result khera et al., 11 demonstrated through study cases who received PIFB with bupivacaine revealed a decrease in cumulative opioid consumption postoperatively, but this variance among the groups was not statistically substantial, suggesting that ultrasound guided PIFB may be effective for the treatment of after surgery pain in patients having cardiac operation.

As regard serum cortisol there is no statistically substantial distinction among the groups investigated at baseline and after 1 hour which may be due to did not use adjuvant in pectointercostal block.

In the contrary to our finding El Sherif et al., 12 found through study to determine if the addition of dexatomidine to a modified pectoral block reduces after surgery pain and stress reaction in cases who are having a modified radical mastectomy. We found that the levels of cortisol and prolactin were substantially lower in the dexatomidine group in comparison to the bupivacaine group.

As regard modified objective pain score there is statistically significant lower pain score among group with Pecto-intercostal group than control group at 2, 6, 12, 18 and 24 postoperative hours without statistically significant difference at 1 hour.

In line with our result Zhang et al., 9 demonstrated through study on 100 pediatric patient undergoing cardiac surgery that divided into 2 group (pectointercostal n= 50) and (non nerve block n=50) that The modified objective pain score rose dramatically in no nerve block group at 3/6/9/12/24-h post-extubation at exercise (coughing) and rest statuses, and There was no statistically substantial distinction among the groups 48 hours after extubation.

As regard hemodynamics there is statistically significant lower mean MAP after sternotomy among pectointercostal versus control group and there is substantial increase mean heart rate amongst control than study group after

sternotomy and extend to closure of sternotomy due blockage of anterior intercostal nerves

Because this block is shallow and administered under direct visual and ultrasound guidance, significant problems such as pneumothorax, chest wall hematoma, and local anaesthetic toxicity did not occur in our research.

In conclusion, decreased perioperative fentanyl requirements, reduced pain degree as indicated by MOPS, and prolonged duration to 1st relief analgesia PIFB is a potential perioperative opioid-sparing analgesic regimen for facilitating quick recovery and early endotracheal extubation due to blocking of the anterior intercostal nerve in the absence of major adverse sequelae following paediatric open-heart surgery via median sternotomy.

### CONCLUSION

We can deduce that the use of a single dose of PIFB is affiliated with stable intraoperative hemodynamics, decreased perioperative opioid analgesic demands, decreased pain intensity in the 1st 24hrs following surgery, and early endotracheal extubation in children who had cardiac operation via median sternotomy. It is a straightforward and technically basic surface block.

### CONFLICT OF INTEREST

None.

### *Financial support and sponsorship*

None.

### REFERENCES

1. Raj N. Regional anesthesia for sternotomy and bypass—Beyond the epidural. *Pediatric Anesthesia*, 2019; 29(5): 519-529.
2. Duncan HP, Cloote A, Weir PM, et al. Reducing stress responses in the pre-bypass phase of open heart surgery in infants and young children: a comparison of different fentanyl doses. *British journal of anaesthesia*, 2000; 84(5): 556-564.
3. Wolf AR. Effects of regional analgesia on stress responses to pediatric surgery. *Pediatric Anesthesia*, 2012; 22(1): 19-24.
4. Humphreys N, Bays SM, Parry AJ, et al. Spinal anesthesia with an indwelling catheter reduces the

- stress response in pediatric open heart surgery. *The Journal of the American Society of Anesthesiologists*, 2005; 103(6): 1113-1120.
5. Mehta Y, Arora D. Benefits and risks of epidural analgesia in cardiac surgery. *Journal of cardiothoracic and vascular anesthesia*, 2014; 28(4): 1057-1063.
  6. Sendasgupta C, Makhija N, Kiran U, et al. Caudal epidural sufentanil and bupivacaine decreases stress response in paediatric cardiac surgery. *Annals of Cardiac Anaesthesia*, 2009; 12(1): 27.
  7. Kumar AK, Chauhan S, Bhoi D, et al. Pectointercostal fascial block (PIFB) as a novel technique for postoperative pain management in patients undergoing cardiac surgery. *Journal of Cardiothoracic and Vascular Anesthesia*, 2021; 35(1): 116-122.
  8. Toscano A, Capuano P, Rinaldi M, et al. Successful use of single-shot pectointercostal fascial block for awake sternal wound revision. *Annals of Cardiac Anaesthesia*, 2022; 25(3): 377.
  9. Zhang Y, Zhang X, Chen S. Perioperative Pain Management with Bilateral Pecto-intercostal Fascial Block in Pediatric Patients Undergoing Open Cardiac Surgery, 2022.
  10. AAGPS J, Sukmono RB, Perdana A. Bilateral Pecto-intercostal Fascial Block as Analgesia for Median Sternotomy in Children, 2020.
  11. Khera T, Murugappan KR, Leibowitz A, et al. Ultrasound-guided pecto- intercostal fascial block for postoperative pain management in cardiac surgery: a prospective, randomized, placebo-controlled trial. *Journal of Cardiothoracic and Vascular Anesthesia*, 2021; 35(3): 896-903.
  12. El Sherif FA, Street EM, al Omara M, et al. Effect of dexmedetomidine added to modified pectoral block on postoperative pain and stress response in patient undergoing modified radical mastectomy. *Pain physician*, 2018; 21, E87-96.