

Concomitant Caesarian section and ovarian ectopic pregnancies: A case report of rarest forms

Rasha Khudair Abbas Alshammari^{1*}, Faik T. Al-Gailani², Marwah A.Hussein³

¹Dr. Rasha private clinic, specialist gynecology and obstetrics (D.G.O)

²Dr.Faiq private clinic, (D.M.R.D ,M.B.Ch.B) Radiologist

³Alwaziria private hospital (IVF department) (M.B.Ch.B) MD (ART)

***Corresponding author:** Rasha Khudair Abbas Alshammari, Dr. Rasha private clinic, specialist gynecology and obstetrics (D.G.O)

Submitted: 11 February 2023; Accepted: 15 March 2023; Published: 14 April 2023

ABSTRACT

The ectopic pregnancy is a complication in which the fertilized ovum is implanted any where other than endometrial cavity. This condition presents a substantial risk for sever maternal morbidity and mortality because of change in securing a prompt diagnosis. In general, the incidence of ectopic pregnancy is increased so that the rarest form started to be not uncommon. We report an extremely rare case of twin ectopic pregnancy, one is in a caesarean section scar and the other is in the left ovary. It has been diagnosed by trans-abdominal ultrasound and treated surgically.

Keywords: *twin ectopic gestation, caesarean section scar ectopic pregnancy, ovarian ectopic pregnancy*

INTRODUCTION

Ectopic gestation is defined as any pregnancy in which the fertilized ovum is implanted in any location other than the endometrial cavity⁽¹⁻³⁾. Ectopic cases occur in 1%–2% of all pregnancies⁽³⁻⁵⁾ and are major cause of maternal morbidity and mortality during the first trimester^(1,2,4,5). An ectopic pregnancy can occur in the fallopian tube, the broad ligament, the abdominal cavity, the cervix, the cornua of the uterus (interstitial ectopic), the ovary, and a previous caesarean scar⁽¹⁻⁶⁾. Most ectopic pregnancies are within the fallopian tube, accounting for 96%–97% of all cases^(1,2,4).

A caesarean scar ectopic pregnancy (CSEP) is rare. It occurs in about 1/1,800 to 1/2,500 of all pregnancies with caesarean section deliveries^(1,3,7-11,14).

With the increased rate of caesarean section deliveries the risk for CSEP also rose^(1,2,4,9,12,13) to 6% of all ectopic pregnancies^(3,8,9,10). Some authors considered that the risk for CSEP is not related to the number of caesarean sections a mother has had^(1,2), while others believed that women who have had multiple caesarean deliveries have a higher risk for CSEP⁽⁵⁾. The most probable cause of the abnormal implantation is that the fertilized ovum invades the myometrium through damage to the decidua basalis of the uterine wall during surgery^(1,2,5).

There are two types of CSEP: type I, in which the conceptus grows toward the uterine cavity, and type II, in which the growth is toward the serosa^(12,5,8,11). In type II, the risk is the invasion of the urinary bladder or the abdominal cavity with excessive haemorrhage and even uterine rupture^(5,6,10,13,14).

Ovarian ectopic pregnancy (OE) is an uncommon type of ectopic pregnancy. It occurs in 1/7,000 to 1/70,000 of pregnancies and about 0.5%–3.0% of all ectopic pregnancies^(15–22). The site of implantation of the conceptus is on the ovary's surface⁽¹⁶⁾. The complications of OE are similar to those of all ectopic cases, except that the ovary can accommodate the expansion of the gestational sac more than the fallopian tube^(15,16,22) even to a full term with good maternal and neonatal health⁽¹⁵⁾.

Case presentation

A 42-year-old lady, gravida 13, para 7 with 5 abortion. She has a history of three full-term vaginal deliveries, four caesarean sections, three spontaneous abortions, and two missed abortions with dilatation and curettage. She missed two periods, presenting with lower abdominal pain and brownish vaginal discharge.

On the abdominal examination, she had a mild lower abdominal tenderness. The per- vaginal examination showed a bulky uterus with cervical excitation and brownish discharges. The trans-abdominal ultrasound showed an oval-shaped gestational sac anteriorly located at the lower uterine segment outside the uterine cavity. The sac was eccentric in the location and embedded within the myometrium. The single viable fetus had a crown-rump length of 0.71 cm, equivalent to six weeks plus four days of gestation (Fig. 1).

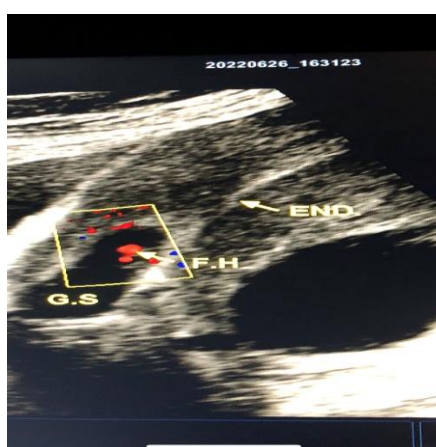


FIG 1: gestational sac with viable fetus.

The left adnexa showed a gestational sac (2 x 1.7 cm) attached to the left ovary with a fetal pole.

The fetal heart could not be detected, with crown-rump length of 0.28 cm, equivalent to five weeks plus six days of gestation. A thin-walled, unilocular left ovarian cyst (3.7 x 2.6 cm) was observed, suggesting a corpus luteum cyst (Fig. 2).

A normal-looking right ovary was observed, with no free fluid within the cul-de-sac. The diagnosis was settled as concomitant CSEP and left OE.

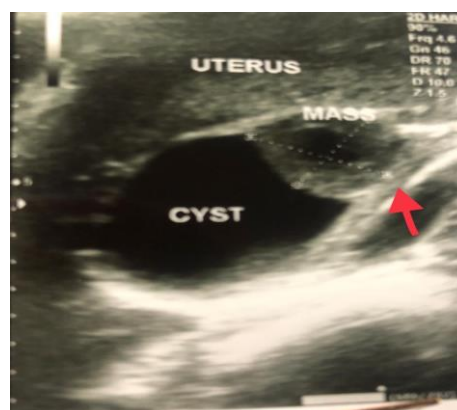


FIG 2: corpus luteum cyst.

Laparotomy was done, and the urinary bladder was dissected. A very thin-walled ectopic gestational sac (impending rupture) was seen at the previous uterine scar (Fig. 3). A gestational sac was seen at the left ovary with thin-walled cyst (Fig. 4). The CSEP was resected with left oophorectomy. The histopathological examination confirms the ectopic gestational sacs with corpus luteum cyst.

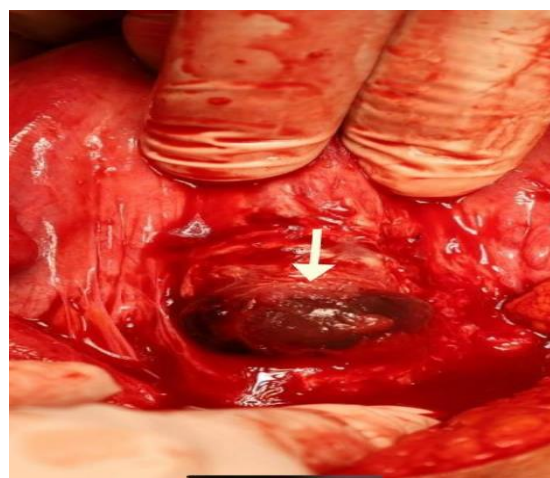


FIG 3: ectopic gestational sac on previous c.s. scar.

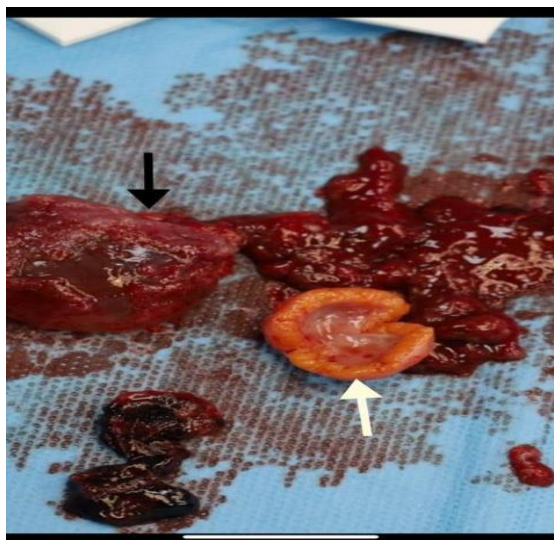


FIG 4: A gestational sac removed from ovary.

DISCUSSION

In general, the rate of ectopic gestation is increased because of the increased use of medical-induced ovulation and the increased rate of pelvic inflammatory disease, laparoscopic hysteroscopy, endometrial trauma by dilatation, and curettage^(3,4,10,12,17,22,23).

The CSEP incidence has increased in recent years because of the increasing rate of caesarean deliveries. The rate of caesarean sections was 20.7% in 1996, which increased by 32% in 2017^(2,5,9,10,12). Although the cause of abnormal ovarian ectopic pregnancy is not well known, different reasons have been proposed, such as delayed ovulation, abnormal thickening of the tunica albuginea, or a secondary implantation on the ovarian surface^(16,17,20).

In our presented case, the patient had the two rarest forms of ectopic gestation, which is extremely rare. The patient had bad obstetrical history with multiple surgical endometrial traumas.

The symptoms of CSEP and EO vary from asymptomatic, lower abdominal tenderness, and mild to moderate painless vaginal bleeding^(7,8,9,14,16,18–22), which are consistent with our case.

The ultrasound criteria for CSEP are as follows: empty uterine cavity and cervical canal, a conceptus implanted within the lower anterior uterine wall, thin or absent covering of the myometrium, a fetal pole or heart pulsation that

could or could not be detected^(2,3,5,6,24). On the other hand, the OE ultrasound findings showed an empty uterine cavity and cervical canal. A thick echogenic rim mass with a cystic centre represents a gestational sac adjacent to the ovary. Also, fetal pole and cardiac pulsation could or could not be detected^(16,17,20). A corpus luteum cyst could be seen^(16,20). These findings were observed in our case and were proved by surgical findings and a histopathological examination.

CONCLUSION

Although concomitant caesarean section scar and ovarian ectopic pregnancies is an extremely rare occurrence, however with increased incidence of endometrial trauma, pelvic inflammatory disease and increased use of ovulatory stimulation drugs, the occurrence of such an event may become more likely and warrants extra vigilance by health care providers particularly in woman with these predisposing factors.

REFERENCES

1. 2019 AlGadeeb et al. cesarean scar-unusual site of ectopic pregnancy. *Cureus* 11(10):e5970. DOI 10.7759/cureus/5970.
2. Lorena Sabonet Morente et al. cesarean scar ectopic pregnancy. *Medicina* 2021,57,362.
3. Olesa Jungkman & Julia Anderson. Important of early detection of caesarean scar ectopic pregnancy. *Journal of Diagnostic Medical Sonography* 2015, vol 31 (5) 318-321.
4. Scott J. Haight et al. My most unusual case. *Emergency Medicine*. 2014 october; 46 (10): 462-465.
5. Taryn Hoffman & Judy Lin. Cesarean scar ectopic pregnancy. Diagnosed with ultrasound. *Clin Pract Cases Emerg. Med.* 2022 Feb; 4 (1); 65-68.
6. Lauria Montgomery Irvine. Cesarean scar ectopic pregnancy. *Ectopic Pregnancy Foundation* 2022/ registered Charity No: 1122286.
7. Folasade Akhanoba et al. Cesarean Scar Ectopic Pregnancies. *Open Journal of obstetrics & gynecology*, 2017, 7, 608-615.
8. Agrawal P et al. Cesarean scar ectopic of 12 weeks. *Int J Reprod Obstet Gynecol.* 2020 Nov; 9 (11): 4773-4776.
9. Katherine Maslowski et al. Cesarean scar ectopic pregnancy. *NZMJ* 16 April, vol 134 No 1533.

10. Mustafa Koplay et al. Ectopic pregnancy in cesarean section scar. *Case Reports in Surgery*. Volume 2016, Article ID 7460687, 4 pages.
11. Majangara et al. Cesarean section scar ectopic pregnancy. *Journal of Medical case Reports* (2019)13:137.
12. R. Maymon et al. Ectopic pregnancy in cesarean section scar: the 8 year experience of one medical center. *Human Reproduction* vol 19, pp. 278-284, 2004.
13. Sra Fenerty et al. Cesarean scar ectopic pregnancy. *App Radiol*. 2017; 46 (12):20-21.
14. Deepika et al. A rare case report of cesarean scar ectopic pregnancy. *J Clin Diagn Res*. 2017 Aug. 11 (8). QD 10-QD 11.
15. Prapas Meethong & Manus Chalermssanyakorn. Full term primary pregnancy with living child & mother. *Thia Journal of obstetrics & Gynaecology*. January 2008, vol. 16, pp. 71-76.
16. Cinthya Sotelo. Ovarian ectopic pregnancy: A Clinical Analysis. *The Journal for Nurse Practitioners* 15 (2019)224-227.
17. Brige et al. Medical management of an ovarian ectopic pregnancy. *Journal of Medical case reports* (2015) 9:290
18. Maryem Bouab et al. Diagnosis & management of ectopic ovarian pregnancy. *International Journal of Surgery Case Reports* 91 (2022)106742.
19. Lajya Devi Goya. Ovarian ectopic pregnancy. *Iran J Reprod Med* vol. 12 No. 12. pp:825-830, December 2014.
20. Jillian Van Vliet Kadau. Sonographic detection of ovarian ectopic pregnancy. *Journal of Diagnostic medical Sonography*. 2016, vol.32 (5) 299-303
21. Dong Won Hwang. Ovarian pregnancy ruptured in second trimester manifesting mental changes in pregnancy. *Obstet Gynecol Sci* 2020; 63 (2):209-212.
22. Hatav Ghasemi Tehrani et al. Ovarian ectopic pregnancy. *Iran J Reprod Med* vol 12 No. 4 PP281-284, April 2014.
23. Tayup Simsek. Heterotopic triplet pregnancy (twin tubal) in natural cycle with tubal rupture. *Journal of Obstetrics & Gynaecology Resrarch* / volume 34, issue 4pt2/ p. 759-762.