



Neuromuscular Rehabilitation: Rehabilitation Improves Functional Independence and Respiratory Outcome after Multiple Laminectomy in Spinal TB: A Case Report

Abd. Sapril S^{1*}, Rita Vivera², William Suciango³

¹Resident at Physical Medicine and Rehabilitation Department, Faculty of Medicine Universitas Airlangga/Dr Soetomo General Academic Hospital

²Physiatrist at Physical Medicine and Rehabilitation Department, Faculty of Medicine Universitas Airlangga/Dr Soetomo General Academic Hospital

³Medical Student at Faculty of Medicine, Hasanuddin University/Dr Wahidin Sudirohusodo General Hospital

***Corresponding author:** Abd. Sapril S, Resident at Physical Medicine and Rehabilitation Department, Faculty of Medicine Universitas Airlangga/Dr Soetomo General Academic Hospital, Email: saprilrisna@gmail.com

Submitted: 24 February 2023; Accepted: 10 March 2023; Published: 01 April 2023

ABSTRACT

Background: Pott's disease is the most common skeletal tuberculosis. Rehabilitation should be considered to improve functional outcome in Pott's disease.

Case: A 30-year-old woman with tuberculosis of vertebra-thoracal-11 (VTh11) to vertebra-lumbal-1 (VL1) presented with bilateral legs weakness, numbness, paresthesia, and back lump. The muscle strength was decreased at the level of L2 to Sacrum-1 (S1), with bilateral sensory deficit at the level of L2. Voluntary anal contraction and deep anal pressure were positive. Thoraco-lumbal X-Ray revealed second grade collapse of corpus VTh12 and third grade wedge compression fracture at VL1 with gibbus deformity and kyphotic angle of 68°. Posterior screw fixation and multiple laminectomy then was performed, followed by rehabilitation and thoraco-lumbo-sacral-orthotic (TLSO). On discharge, functional independence measure (FIM) increased from 43 to 118, while respiratory count test enhanced from 15 to 24.

Conclusion: along with medication and surgery, rehabilitation is important to improve functional outcome in pott's disease.

Keywords: *Spinal TB, Laminectomy, Spinal Orthosis, Rehabilitation*

INTRODUCTION

Tuberculosis is still a major health problem around the world. In 2015, there are approximately 10.4 million people suffer from tuberculosis worldwide, with 1.4 million of them were died (Andajani, 2019). Pott's disease or spinal tuberculosis is the most dangerous and

common form of skeletal extrapulmonary TB (Rajasekaran et al., 2018; Reihani et al., 2022). Besides becoming a health problem with big impact in the world, tuberculosis is also become a major health problem in Indonesia, with tuberculosis of the vertebra was found to be a dominant form of bone and joints tuberculosis

compared to other site of bone tuberculosis (Tidja et al., 2020; Oktamianti et al., 2021). Antituberculosis medications and surgery remain the mainstay therapeutical approach for spinal tuberculosis (Viswanathan & Subramanian, 2022). Surgical intervention is indicated for spinal tuberculosis when debridement and spine stabilization are needed, such as in cases with kyphosis with the angle of $\geq 25^\circ$. Normally, recovery process from spinal fusion will take three to six months (Mak & Cheung, 2013; Anil, 2002). External fixation is used to support internal fixation techniques such as multiple laminectomy with corpus vertebra loosening to gives a better stabilization (Connolly & Grob, 1998; Chui et al., 2019). Rehabilitation is one of the beneficial therapeutical modality to enhance clinical outcome for patients with spinal tuberculosis, especially in functionality. Unfortunately, studies about rehabilitation in spinal tuberculosis are still limited (Nas et al., 2004). This case report is aimed to describe the role of physical medicine and rehabilitation for the treatment of patient with SCI with neurological level injury (NLI) on Lumbal-1 (L1) with Asia Impairment Score (AIS) of D caused by Tuberculous Spondylitis after multiple laminectomy procedure.

CASE REPORT

A 30 years old woman was referred by orthopedic department in February 2021 with Spondylitis TB of VTh 11-VL1 with chief complaint of weakness of her both legs since the 2 years ago, followed by numbness and tingling sensation. The patient also experienced lump sensation on her back. The patient was referred to dr. Soetomo Hospital one year ago. There had been also a history of low back pain but the pain has been disappeared. The patient was still able to walk but unable to climb upstairs. Bowel and bladder disturbances were absent. There was no history of pulmonary tuberculosis, hypertension and diabetes mellitus, but the patient's uncle had pulmonary tuberculosis in 2017. She hoped that she could do her ADL independently and participate in the social activity as before.

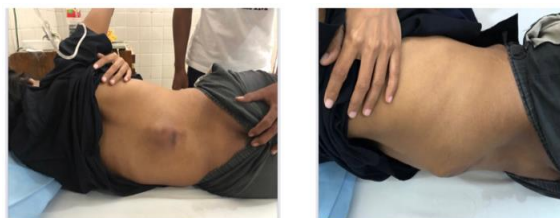

FIGURE 1: Spine deformity of the patient

On physical examination, the motoric level was found at L1, with manual muscle testing (MMT) for L2-S1 were 4 for all extremities. The Sensory level was found at L1. Hypoesthesia was detected at L2 region at both sides and also at S4-S5. Deep anal pressure (DAP) and voluntary anal contraction (VAC) were positive. Gibbus was found at VTh11-L1. Knee pees reflex (KPR) and achilles pees reflex (APR) were 3+ on both legs. The Babinski reflex was positive in both sides. Spasticity was not found. Bowel and bladder function were normal. Thoraco-lumbal X-Ray showed a second-grade collapse of corpus VTh12 and third-grade wedge compression fracture at VL 1 which formed gibbus deformity. The kyphotic angle was 68° . The functional independence measure (FIM) score was 43 and respiratory count test was 15.

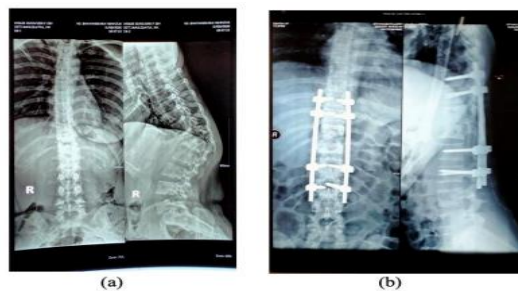


FIGURE 2: Asia Impairment Score of the patient

The patient was treated with once daily combination of rifampicin 450 mg, isoniazid 300 mg, pyrazinamide 1 gram, and ethambutol 1 gram for one year. Two weeks after admission, surgical procedure which consist of debridement, compression laminectomy, and posterior column osteotomy was performed by orthopedic surgeon. Posterior stabilization was then carried out by using pedicle screw.

In our case, physical rehabilitation was also applied before and after the surgery. The patient underwent log roll procedures, inline mobilization, breathing exercise, active range of motion (AROM) exercises, and sensory re-sensitization before operative procedure in order to prevent worsening of patient's condition. Meanwhile, the patient also received post-operative rehabilitation to help maintaining post operative condition and improving the clinical outcome, including lower extremities and core muscles strengthening, transfer training from lying to sitting and from sitting to standing, balance exercise, and gait training by using walker. Besides that, thoraco-lumbo-sacral orthotic (TLSO) with full control was given as an additional stabilization from posterior after multiple laminectomy, and from anterior and lateral after collapse of VTh12. Four months later, the FIM score was improved from 43 to 118, which followed with increased respiratory count test from 15 to 24.

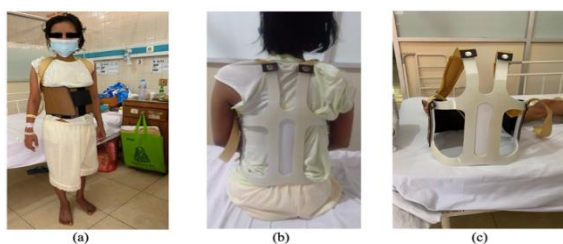


FIGURE 3: Thoraco-lumbo-sacrum orthosis (TLSO) after surgical intervention

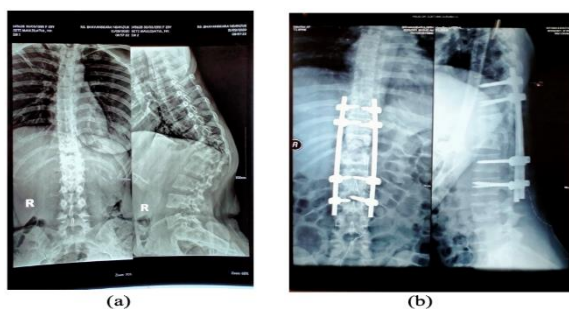


FIGURE 4: Thoraco-lumbar spine X-Ray. (a) Pre operative and (b) Post operative

Pott's disease is tubercular disease of the spine which is caused by Mycobacteria complex, mainly *M. tuberculosis*. It was firstly discovered at year 1779 by Sir Pervical Pott with clinical

presentation of kyphotic deformity and neurological deficit in European patients. Recently, this disease has been a challenge for global community due to its significant resurgence and increased occurrence of multidrug-resistant organism in the last decades. Pott's disease is usually appeared as secondary to hematogenous spread from previous pulmonary tuberculosis (Viswanathan & Subramanian, 2022).

Pott's disease presentation can be various between individuals, depends on the duration and severity of the disease, location of lesion, and presence of complications. In uncomplicated cases, the patients commonly presented with back pain, while in complicated disease, it is usually accompanied with deformity, instability, and neurological deficits. Abscess which is lack of inflammatory signs can be found in the vertebra, called as cold abscess. In complicated disease, deformity can be present, typically kyphotic deformity which can be varies from knuckle (one vertebra involvement) or gibbus (two vertebra involvement) to rounded kyphus (three vertebra involvement). Neurological deficits are usually obtained in complicated cases, presented as sensory, motoric, and autonomic disturbances. It can be originated from compression due to an abscess, inflammatory tissues, spinal instability, or mechanical traction.

Antituberculosis drugs and surgery are the main treatment modalities for Pott's disease. Spinal TB classification based on the disease presentation is the important key to determine the therapy of the disease. If the spinal TB present with uncomplicated state, it is usually treated with antituberculosis medications, but once the disease become complicated, surgical intervention should be considered. The World Health Organization (WHO) recommends six months of antitubercular therapy, consist of two months therapy with combination of isoniazid, rifampicin, pyrazinamide, ethambutol, and/or streptomycin in initiation phase, followed with 4 months continuation phase with isoniazid and rifampicin. The American Thoracic Spine Society recommends nine months therapy with the same regimens, meanwhile The Canadian Thoracic Society recommends nine months to

one year therapy with antituberculosis drugs. Surgical intervention is considered for spinal TB for several conditions, including lack of response to antituberculosis medications, recurrent disease, severe neurological disturbances, static or progressive neurological deficit despite of antitubercular drugs, presence of deformity, debilitating pain, and instability (Viswanathan & Subramanian, 2022).

Our patient presented with paraplegia accompanied with sensory deficits, second grade collapse of corpus VTh12 and third grade wedge compression fracture of VL1. Kyphotic deformity with angle of 68° and gibbus deformity was also found. Based on the clinical manifestation, the patient was classified as complicated spinal TB and indicated for surgical intervention which consists of debridement, multiple laminectomy, posterior column osteotomy, and stabilization using pedicle screw. Multiple laminectomy was performed for decompression of the site of spinal tuberculosis, which followed by pedicle screw stabilization for spine fixation to prevent further damage. The patient received combination of four antituberculosis drugs for one year according to guidelines from American Thoracic Association (Viswanathan & Subramanian, 2022).

Surgery still remains the main therapeutical approach for spinal tuberculosis, especially in complicated cases, but rehabilitation also should be undergone in order to achieve the best functional recovery according to the degree of neurological deficits. There are various types of physical rehabilitation for spinal tuberculosis, depend on the stage of the disease. In acute stage, physical rehabilitation aims to optimize bed mobilization through isometric strengthening of paraspinal and gluteal muscles which are essential for standing, balancing, and ambulation. In sub-acute stage, rehabilitation therapy focuses on active and active-assisted exercises, including sitting and standing exercises with or without assistance or aids (Yong et al., 2021). Our patient received log roll procedures, inline mobilization, active range of motion (AROM) exercises, and sensory re-sensitization as pre-operative rehabilitation to achieve optimal mobilization, prevent muscle weakness caused by the disease,

and prevent worst functioning outcome (Yong et al., 2021). Breathing exercise was also performed to improve respiratory function and oxygenation. The patient was also given post-surgical rehabilitation consisting of lower extremities and core muscles strengthening, transfer training from lying to sitting and from sitting to standing, balance exercise, and gait training by using walker. In addition, TLSO with full control was also applied to our patient. The core muscle strengthening is given to decrease the possibility of low back pain after laminectomy and posterior pedicle screw (Lee et al., 2017). Lower limb strengthening, transfer training, balance training, and gait training was aimed to improve the patient's ambulation, as well as ambulation is one of the rehabilitation concerns for spinal tuberculosis through gradual increased intensity of the training (Yong et al., 2021). Furthermore, TLSO was given as posterior stabilization after multiple laminectomy and anterolateral stabilization after collapse of VTh12 (Lee et al., 2017).

Rehabilitation plays an essential role for patient's functional recovery, including patients with spinal tuberculosis. The role of rehabilitation in spinal tuberculosis management is to achieve optimal functional recovery through adequate mobilization to prevent contractures, pressure ulcers, and muscle wasting (Yong et al., 2021). There are several clinical trials which shown the effect of physical rehabilitation in improving functional outcome in patients with spinal tuberculosis, though the number of the studies is still limited (Nas et al., 2004; Zaoui et al., 2012). A retrospective study by Zaoui et al proved that rehabilitation therapy was effective in improving measure of functional independence (MFI) in Pott's disease patients with paraplegic accompanied by neurological and bladder involvement. All the patients received antituberculosis treatment for at least 8 months and some of them undergone decompression surgery. The MFI of the patients was increased from 71 in admission to 92 in discharging (Zaoui et al., 2012). A prospective case study by Nas et al also demonstrated a significant improvement ($p < 0.001$) on motor score of the lower limb and MBI score for activities of daily living and

mobility after muscle strengthening exercises in spinal tuberculosis with back pain, paraparesis, and sensory dysfunction (Nas et al., 2004). Similar with previous studies, our patient also experienced improved FIM from 43 to 118 after several rehabilitation cares. In addition, respiratory function of our patient was also found to improved, represented by increased respiratory count test from 15 to 24. Rehabilitation has shown to be useful in improving functional outcome together with respiratory function in our case.

CONCLUSION

Pott's disease is the most common of skeletal extrapulmonary TB. A comprehensive therapeutical approach which consists of medication, surgery, and rehabilitation is necessary to stop the infection, stabilize the spine, and prevent immobilization. Rehabilitation is an important modality in spinal tuberculosis treatment as it plays an important role in supporting medical and surgery outcome, also boosting functional recovery thus improving independency and life quality of the patients.

REFERENCES

1. Andajani, S. (2019). Determinant of latent pulmonary tuberculosis incidence among health workers in community health centers in Surabaya, Indonesia. *Folia Medica Indonesiana*, 55(2), 139-146.
2. Rajasekaran S, Soundararajan D. C. R, Shetty A. P., Kanna R. M. (2018). Spinal Tuberculosis: Current Concepts. *Glob Spine J*. 8(4_suppl):96S-108S. <https://doi.org/10.1177/2192568218769053>
3. Reihani, H., Zarei, F., Soltani, A., & Saeedi-Moghadam, M. (2022). A notable improvement in spontaneous intracranial hypotension (SIH) after delivery in a pregnant woman: A case report. *Radiology Case Reports*, 17(10), 3763-3766. <https://doi.org/10.1016/j.radcr.2022.01.070>
4. Tidja, Y. E. A., Mustokoweni, S., & Saleh, T. A. (2020). Bone tuberculosis: clinical profile of 40 patients in Dr. Soetomo General Hospital Surabaya. *Jurnal Ilmiah Mahasiswa Kedokteran Universitas Airlangga*, 11(01). <https://doi.org/10.20473/juxta.v11i12020.1-5>
5. Oktamianti, P., Bachtiar, A., Sutoto, S., Trihandini, I., Prasetyo, S., Achadi, A., & Efendi, F. (2021). Tuberculosis control within Indonesia's hospital accreditation. *Journal of Public Health Research*, 10(3), jphr-2021. <https://doi.org/10.4081/jphr.2021.1979>
6. Viswanathan V. K., & Subramanian S. (2022). Pott Disease.
7. Mak, K. C., & Cheung, K. M. (2013). Surgical treatment of acute TB spondylitis: indications and outcomes. *European Spine Journal*, 22, 603-611. <https://doi.org/10.1007/s00586-012-2455-0>
8. Anil, K. J. (2002). Treatment of tuberculosis of the spine with neurologic complications. *Clinical orthopaedics and related research*, 398, 75-84. <https://doi.org/10.1097/00003086-200205000-00011>
9. Connolly, P. J., & Grob, D. (1998). Controversy: Bracing of patients after fusion for degenerative problems of the lumbar spine-Yes or no?. *Spine*, 23(12), 1426-1428. <https://doi.org/10.1097/00007632-199806150-00024>
10. Chui, K. C., Jorge, M., Yen, S. C., & Lusardi, M. M. (2019). *Orthotics and Prosthetics in Rehabilitation E-Book*. Elsevier Health Sciences. United States: Elsevier Health Science; 2019. 832 p.
11. Nas, K., Kemaloğlu, M. S., Çevik, R., Ceviz, A., Necmioğlu, S., Bükte, Y., ... & Kirbaş, G. (2004). The results of rehabilitation on motor and functional improvement of the spinal tuberculosis. *Joint Bone Spine*, 71(4), 312-316. [https://doi.org/10.1016/S1297-319X\(03\)00135-0](https://doi.org/10.1016/S1297-319X(03)00135-0)
12. Yong, L. N., Ahmedy, F., Yin, K. N., & Engkasan, J. P. (2021). Functional outcomes in spinal tuberculosis: a review of the literature. *Asian spine journal*, 15(3), 381. <https://doi.org/10.31616/ASJ.2020.0086>
13. Lee, C. S., Kang, K. C., Chung, S. S., Park, W. H., Shin, W. J., & Seo, Y. G. (2017). How does back muscle strength change after posterior lumbar interbody fusion?. *Journal of Neurosurgery: Spine*, 26(2), 163-170. <https://doi.org/10.3171/2016.7.SPINE151132>
14. Zaoui, A., Kanoun, S., Boughamoura, H., Maitigue, M. B., Bouaziz, M. A., Khachnaoui, F., & Rejeb, N. (2012). Patients with complicated Pott's disease: Management in a rehabilitation department and functional prognosis. *Annals of physical and rehabilitation medicine*, 55(3), 190-200. <http://dx.doi.org/10.1016/j.rehab.2012.02.004>