



Age Estimation with Permanent First Molar Using Nolla's Method In Indian Population

Mohamed Rifaath¹, Abirami Arthanari^{2*}

¹Department of Forensic odontology, Saveetha Dental College and Hospitals, Saveetha Institute of Medical and Technical Sciences, Saveetha University, Chennai-600 077, India

²Senior lecturer , Department of Forensic odontology, Saveetha Dental College and Hospitals Saveetha Institute of Medical and Technical Sciences, Saveetha University, Chennai-600 077, India

***Corresponding author:** Abirami Arthanari, Senior lecturer , Department of Forensic odontology, Saveetha Dental College and Hospitals, Saveetha Institute of Medical and Technical Sciences, Saveetha University, Chennai-600 077, India , Email: abiramia.sdc@saveetha.com

Submitted: 27 February 2023; Accepted: 14 March 2023; Published: 01 April 2023

ABSTRACT

Introduction: Accurate age estimation of an individual is extremely important in forensic dentistry and for various medical legal purposes. Age estimation is the process of determining a person's age group based on biometric features. **Aims and Objectives:** The aim of the study was to determine Age estimation with permanent first molar using Nolla's method. It was also to evaluate the interrelationship between chronological and dental age according to both these methods and to evaluate which technique was better.

Materials and Methods: This cross sectional study involves retrospective evaluation of the Orthopantomographs of 5-10 years old childrens who came for paediatric treatment in oral medicine and radiology department at Saveetha dental college and hospital. For every individual included in the study a panoramic radiograph was taken, with standard parameters and adequate protective measures.

Results and discussion: The study included 60 childrens. The standard deviation of male was found to be at 2.3056 and female were at 2.52003

Conclusion: We can conclude that it was found that male growth was ahead of females.

Keywords: *Nollas Method, Age estimation, Orthopantomograms*

INTRODUCTION

Dental remains provide the scientific community and investigating authorities with the most quick, reliable, and effective form of forensic identification for identifying victims of mass disasters, criminal activity such as terrorism, or natural disasters. One of the most difficult jobs for forensic scientists involved in defining the biological profile of such human remains is determining the age of the

mutilated/decomposed corpse or skeletal remains. Forensic identification includes processing long bones and teeth so as to verify an individual's age. Whereas both bones and teeth are often utilised in postmortem, teeth also can be inspected to some extent during life(1). Accurate age estimation of an individual is extremely important in forensic dentistry and for various medical legal purposes.

Age estimation is the process of determining a person's age group based on biometric features. Teeth are shown to be highly resistant to mechanical, physical, chemical, or biological degradations or taphonomic destructions, making dental age estimation approaches particularly useful in forensic anthropological examinations(2). Among all human skeletal remains, teeth have the longest post-mortem lifetime. A variety of morpho-histological, molecular, and radiographic approaches have been used to explore diverse age-dependent alterations in teeth. However, histological and molecular examinations of teeth give comparatively more precise and credible results for adult teeth, though radiological techniques are commonly used for age assessment of developing teeth of adolescents(3).

Teeth are the most indestructible component of the body and have the least turnover of natural structure, hence they are employed most reliably in age estimation. As a result, they not only survive death but also remain virtually unaltered for thousands of years afterward. The expected developmental sequence followed by the human dentition to reach complete dental development can be used to determine age(4). Because dental growth and calcification are governed more by genes than by environmental variables, approaches based on phases of tooth production as seen on radiographs appear to be more appropriate in the estimation of age than those based on skeletal development. Teeth, particularly in kids, are less vulnerable to dietary, hormonal, and pathological alterations. Radiographic study of developmental stages of the dental elements can be used to estimate age in children.(5)

The tooth with its developmental phases impart noninvasive, nondestructive attributes to assess the person's age. A number of systems have been used to estimate the dental age as stated by the extent of the developmental stages reported in radiographic examinations in permanent teeth(6). Among the approaches for estimating the age of adult teeth, Nolla's radiography method based on dental development stages is widely utilised for both teaching and research in forensic sciences. This approach uses X-ray radiographs to examine the stages of permanent dentition mineralization

to calculate the age threshold, which is separated into ten maturation stages for all teeth in both the upper and lower dental arch(7).

Nolla is a method of estimation by evaluating the Calcification of the permanent dentition. The Calcification of permanent dentition was divided into 10 stages like 1) Absence of crypt. 2) Presence of Crypt. 3) Initial Calcification. 4) 1/3rd Crown completed. 5) 2/3rd crown completed. 6) Crown almost completed. 7) Crown completed 8) 1/3rd root completed. 9) 2/3rd of Root Completed. 10) Root almost Completed – open apex. 11) Apical end of root completed for every group of teeth like incisors, canine, premolars and molars of maxillary and mandibular arches separately. The radiograph of the individual was matched with a comparative figure given by Nolla. Each tooth was recorded with a reading and a sum is formed for maxillary and mandibular teeth. Later the sum is compared with the table given by Nolla(8). Separate tables are given for boys and girls and including or excluding third molars(9).

The aim of the study is to estimate the age of the particular individual using permanent 1st molar using OPG by nolla's age estimation method

MATERIALS AND METHODS

Study design and sample collection

This cross sectional study involves retrospective evaluation of the Orthopantomographs of 5-10 years old childrens who came for paediatric treatment in oral medicine and radiology department at Saveetha dental college and hospital. Following ethical approval from the institutional review board, access to the patient data was obtained.

Inclusion criteria

Only childrens from the age group 5-9.9 years with complete case records and clear orthopantomograph were included

Exclusion criteria

Subjects with congenital anomalies, systemic diseases, fractured teeth, teeth with periapical lesions, malformed teeth. Congenitally missing

and history orthodontic treatment were excluded from the study.

Sample size

Total sample size is 60, in this we segregated male as 30 and female as 30 in numbers to avoid the bias.

TABLE 1: represents the brief sample size distribution of male and female age group

S.no	Age in years	male	female	total
1	5-5.9	5	5	10
2	6-6.9	5	5	10
3	7-7.9	5	5	10
4	8-8.9	5	5	10
5	9-9.9	5	5	10
6	10-10.9	5	5	10

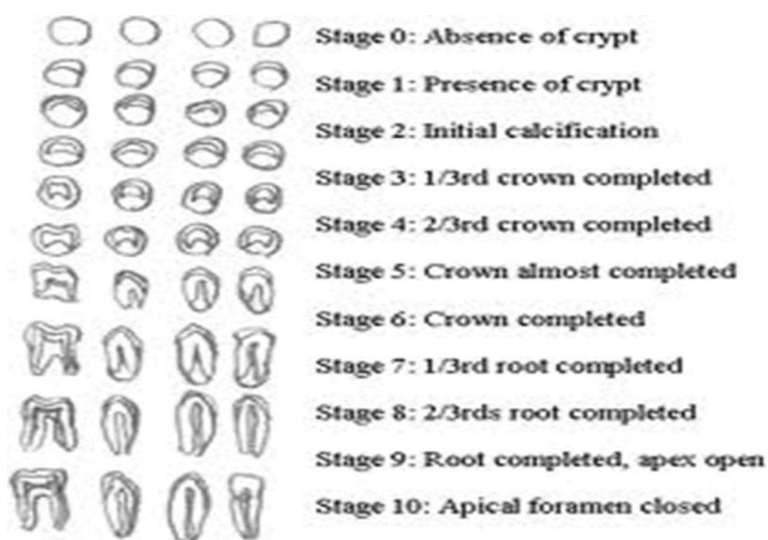


CHART 1: Nolla's Age Estimation Method Chart.

RESULTS

TABLE 2: Represent the group statistics of male and female

Group	N	Mean	Std. Deviation	Std. Error Mean
Rating Male	30	4.1667	2.30567	.42095
Female	30	3.1667	2.52003	.46009

TABLE 3: Represents Error Bar

		Levene's Test for Equality of Variances		t-test for Equality of Means						
		F	Sig.	t	df	Sig. (2-tailed)	Mean Difference	Std. Error Difference	95% Confidence Interval of the Difference	
									Lower	Upper
Rating	Equal variances assumed	.508	.479	1.604	58	.114	1.00000	.62361	-.24829	2.24829
	Equal variances not assumed			1.604	57.548	.114	1.00000	.62361	-.24850	2.24850

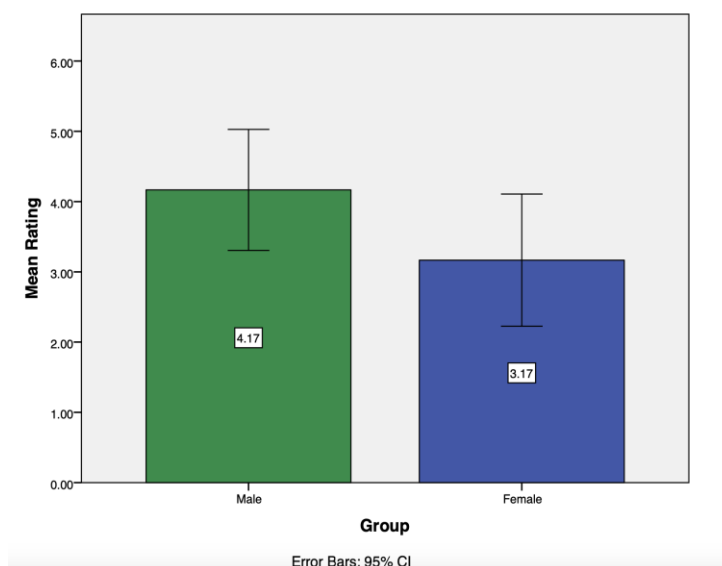


CHART 1: Represents the bar graph between mean Rating and groups

DISCUSSION

In comparison to other growth and development indicators, dental age is thought to be more relevant to chronological age. Given that tooth mineralization is largely regulated by genes and is less impacted by environmental variables than gingival emergence or eruption, dental age estimation based on tooth mineralization is claimed to be more accurate than these processes(10). The radiographic method has been determined to be the most beneficial among the numerous dental age assessment techniques since it is straightforward, affordable, non-mutilating, and non-invasive. Particularly, because they offer a single, distortion-free image of the whole teeth, panoramic radiographs are frequently chosen to evaluate dental maturity.

There are various different ways to calculate Dental age. The Nolla method of age estimation was selected because among the methods used to quantify Dental Age, the Demirjian and Nolla methods are frequently used in clinical practice and training(11).

To get as near to the chronological age as feasible is the goal of the optimal age estimation approach. In many ethnic communities, numerous age estimate techniques have been tested and reported in the literature. There have only been a few studies on the Indian people published. Thus, it was found necessary to use

Nolla's methods to estimate age in our study(10,12).

For estimating age, tooth development phases are preferable to tooth emergence because the former can be hampered by a number of conditions, including illness, tooth extraction, crowding, and ankylosis. Since calcification is a continual process, it is very difficult to determine the precise period; however, the age can be calculated utilising a radiographic analysis of this calcification process(13).

Only a few research on the Indian population were conducted utilising Nolla's age assessment method. Using hand and wrist radiographs, Nolla's approach was utilised in 2013 to determine the link between the chronological, dental, and skeletal ages of the Indian population. According to the study, the skeletal maturation of Indian women was more advanced than that of men, and the relationship between chronological age and dental and skeletal age was not always consistent. According to this study, the stages of canine calcification can also be utilised to gauge skeletal maturation. Another study that looked at the validity of Nolla's age assessment approach in the Lucknow population came to the conclusion that girls were more advanced in dental maturation than boys and that there was no consistent relationship between chronological age and dental age(14)(15,16).

CONCLUSION

This cross sectional study involves retrospective evaluation of the Orthopantomographs of 5-10 years old childrens who came for paediatric treatment in oral medicine and radiology department at Saveetha dental college and hospital and it was found that male growth was ahead than females.

ACKNOWLEDGEMENTS

Saveetha Dental College and Hospitals, Saveetha Institute of Medical and Technical Science, Saveetha University.

CONFLICT OF INTEREST

The authors declare no potential conflict of interest.

SOURCE OF FUNDING

The present study was supported by the following agencies, Saveetha Dental College and Hospitals.

REFERENCES

1. David TJ, Lewis J. Forensic Odontology: Principles and Practice. Academic Press; 2018. 338 p.
2. Masthan KMK. Textbook of Forensic Odontology. Jaypee Brothers Medical Pub; 2009. 148 p.
3. Christoloukas N, Mitsea A. The CSI effect in Forensic Odontology. A systematic review. *J Forensic Odontostomatol.* 2022 Aug 30;2(40):38–43.
4. Rcs BHB. Great Teeth for Life: The Secret to a Lifetime of Good Dental Health. iUniverse; 2010.
5. Halvorsen B. Great Teeth for Life: The Secret to a Lifetime of Good Dental Health. iUniverse; 2010. 262 p.
6. Shan W, Sun Y, Hu L, Qiu J, Huo M, Zhang Z, et al. Boosting algorithm improves the accuracy of juvenile forensic dental age estimation in southern China population. *Sci Rep.* 2022 Sep 19;12(1):15649.
7. Garizoain G, Parra RC, Escalante-Flórez KJ, Aranda CM, Luna LH, Condori LA, et al. Age-at-death estimation in adults using three forensic methodologies: A Lamendin's technique approach for Latin American context and the extension of a forensic international dental database. *J Forensic Sci.* 2021 Nov;66(6):2456–68.
8. Arthanari A, Priyadharshini R, Sinduja P. Cheiloscopy and Rugoscopy in Forensics-A Review [Internet]. Vol. 6, *International Journal of Clinicopathological Correlation.* 2022. p. 12–5. Available from: <http://dx.doi.org/10.56501/intjclinicopatholcorrel.v6i1.42>
9. G NK, Nithya KG, Bhagya LT, Prabhu D. Radiographic evaluation of permanent second molar development based on nollas stage of tooth development in 9-11-year-old male children [Internet]. Vol. 11, *International Journal of Research in Pharmaceutical Sciences.* 2020. p. 469–74. Available from: <http://dx.doi.org/10.26452/ijrps.v11ispl3.2968>
10. Folayan MO. A Global Compendium of Oral Health: Tooth Eruption and Hard Dental Tissue Anomalies. Cambridge Scholars Publishing; 2019. 553 p.
11. Hillson S. Dental Anthropology. Cambridge University Press; 1996.
12. Ranta H, Lincoln MJ, Penttila A, Leibur E. Reliability and Validity of Eight Dental Age Estimation Methods for Adults. 2003. 4 p.
13. Parekh S. Dental Age Assessment: Developing Standards for UK Subjects. 2011.
14. Yassin SM, M AlAlmai BA, Ali Huaylah SH, Althobati MK, A AlHamdi FM, Togoo RA. Accuracy of Estimating Chronological Age from Nolla's Method of Dental Age Estimation in a Population of Southern Saudi Arabian Children. *Niger J Clin Pract.* 2020 Dec;23(12):1753–8.
15. Vidhya A, Doggalli N, Patil K, Narayan K, Thiruselvakumar D, Abirami A. Virtual autopsy: An imaging technological integration in forensic odontology [Internet]. Vol. 4, *International Journal of Forensic Odontology.* 2019. p. 2. Available from: http://dx.doi.org/10.4103/ijfo.ijfo_5_19
16. Doggalli N, Arthanari A, Patil K, Shankar HPJ, Vidhya A. Bite mark: Is it still valid?? [Internet]. Vol. 4, *International Journal of Forensic Odontology.* 2019. p. 14. Available from: http://dx.doi.org/10.4103/ijfo.ijfo_4_19