



The Role of Cystoscopy for Patients with Lower Urinary Tract Symptoms (LUTS)

Ali Hadi Sabhan^{1*}

¹Department of Surgery, College of Medicine, University of Al-Qadisiyah, Iraq.

*Corresponding author: Ali Hadi Sabhan, Department of Surgery, College of Medicine, University of Al-Qadisiyah, Al-Diwaneyah, Iraq, Email: ali.sabhan@qu.edu.iq

Submitted: 15 January 2023; Accepted: 25 February 2023; Published: 22 March 2023

ABSTRACT

Background and objective: LUTS affect the quality of patient's life from different aspects including social, physical and psychological with health cost impact. Cystoscopy is minimally invasive procedure that can be done in the office for the evaluation of the lower urinary tract. This study aimed to assess the role of cystoscopy for patients with lower urinary tract symptoms (LUTS) as a diagnostic tool when other investigational modalities are normal and its suitability for prompt intervention when possible.

Methods: The study was conducted at a single urology center through the period from January 2019 to March 2020 that includes 60 eligible patient with bothersome long-term lower urinary tract symptoms (LUTS) with normal initial investigations. Cystoscopy was done to all included patients, percentages of detected relevant findings and interventional procedures are determined.

Results: 60 patients were included in this study with a mean age of 38 years (32 male and 28 female) who underwent cystoscopy, positive findings was in 31 patients (51.6%), 20 male and 11 female. Clinically significant abnormalities were found in 14 patients (23.3 %) that includes: Urethral stricture (5%), intravesical calculi (6.6%), bladder tumor (5%), prostatic enlargement (3.3%), fistula (1.7%) and foreign body (1.7%). 14 patients (23.3 %) underwent concomitant cystoscopic interventional procedures doing in same time of examination. There was no significant difference between men and women with regard to the detected findings ($P = 0.2$).

Conclusion: Cystoscopy is a valuable diagnostic modality that achieve rapid completion of diagnostic workup, and allow some surgical intervention to be done more promptly. It can be consider as integral tool in the management of patients with LUTS.

Keywords: *Cystoscopy; LUTS; BPH; TURBT; UUI*

INTRODUCTION

Lower Urinary Tract Symptoms (LUTS) are common conditions, occurs in men and women of all ages. These symptoms causing discomfort and affects self-confidence with several social implications [1].

The term LUTS was introduced in 1994 to describe the complaints of patients without

reference to their cause[2].

Traditionally, it is known as "prostatism", in men and focusing on urinary incontinence in women with other LUTS. Later, the new term proved to be appropriate when many recent surveys (population-based) have shown that bladder symptoms are not specific to sex, age or disease[3].

LUTS are divided into storage and emptying symptoms. Storage symptoms include urinary frequency, nocturia, urgency, urge incontinence, and bladder or urethral pain. Emptying symptoms are consist of hesitancy, straining, weak urine stream, a feeling of incomplete emptying, and urine retention[4].

Lower urinary tract symptoms (LUTS) are common in men, 41% of them are complaining from bothersome symptoms above 40 years age [5]. In epidemiological studies, LUTS were found in 57.1% of men and 48% of women [6].

Lower urinary tract symptoms (LUTS) involving variety of conditions that affecting aging males. LUTS includes storage, voiding, and post-micturition symptoms[7]. LUTS can be result from multiple conditions, benign prostatic hyperplasia (BPH) and or overactive bladder (OAB) are the two main causes of LUTS in male patients [8].

Lower urinary tract symptoms are common and distressing problem affecting women[9] and include incontinence (stress , urge, and mixed incontinence), over-active bladder (OAB), in addition to urinary storage and voiding problems. The symptoms are overlapping and needs to exclude probability of urinary tract infection (UTI) . LUTS are often associated with aging changes liked reduced bladder capacity or incomplete emptying of the bladder and estrogen loss [10].

LUTS affect the quality of patient's life from different aspects including social, physical and psychological with health cost impact [11].

Urethrocystoscopy can be done for men with LUTS in presence of haematuria to exclude possible urethral or bladder pathology, or before planned surgical intervention when the findings may alter the treatment strategy[12]. Different studies have made to assess the usefulness of cystoscopy in females with recurrent UTI, but the results remain inconclusive [13].

For those patients with uncomplicated lower UTI, cystoscopy and imaging studies are of low diagnostic values, further investigations are mostly unnecessary [14]. However , imaging studies and cystoscopy can be helpful for some

women with urinary tract abnormalities like urethral stricture, urolithiasis, or foreign body [15].

The continued amelioration of the endoscopic instruments over the past years has allowed an increase in their application in the number and methods [16].

Cystoscopy is a minimally invasive urologic tool to diagnose abnormalities in the lower urinary tract. It can be performed in the office for inspection of the lower urinary tract to evaluate the urethra, bladder and its urothelium in addition to the ureteral orifices. Rigid cystoscopes is suitable for female because of the short urethra that permit straight entrance from the urethral meatus and with topical application of local anesthetic make the patient comfortable and relatively painless procedure [17].

For males, discomfort is noted when rigid cystoscopy is used specially when it reaches the membranous and prostatic urethra. Pain can be minimized by asking the patients to relax their pelvic muscles and take slow deep breaths , a general anesthetic or lumbar epidural anesthetic may be given to aid in performing a cystoscopy when the rigid type must be used. In [18]. Cystoscopy can be utilized to inspect important urethral structures in men like the fossa navicularis, penile urethra and bulbar urethra and periurethral glands of Littre. Urethral strictures may be visualized, dilation or visual internal urethrotomy can performed in same time. The length of prostate/prostatic urethra and the lateral and median lobes can be assessed. The trigone, ureteral orifices, lateral walls, dome and anterior bladder neck can be visualized at time of bladder entrance [17].

Further uses of cystoscopy includes : Assessment of bladder capacity, the presence of trabeculation or diverticula, secondary changes to chronic infection or indwelling catheters and the integrity of the bladder neck and external urethral sphincter [18].

PATIENTS AND METHODS

This cross-sectional study was conducted at urology department in Al-Diwaniyah teaching hospital through the period from January 2019 to

March 2020 that includes 60 eligible patient (32 male and 28 female) with a median age of 38 year(range from 21 year to 52 years). The inclusion criteria were patients with bothersome long-term lower urinary tract symptoms (LUTS) with normal initial investigations and a willingness to participate in the study.

LUTS were defined as urinary frequency, urgency, urge incontinence, nocturia, bladder/urethral pain, hesitancy, straining to void, a weak stream, a feeling of incomplete bladder emptying, and urinary retention.

History taken and physical examination was done to all included patients followed by the essential investigations (involving urinalysis with or without urine culture, blood testing such as complete blood count and renal function test, imaging studies like abdomino-pelvic ultrasound, KUB, CT-scan or MRI).

The cystoscopy procedure was fully explained to all patients who are included in this study; and an informed consent was taken from them. The study was approved by ethical committee of College of Medicine, Al-Qadisiyah University.

Single prophylactic dose of intravenous 1 gm ceftriaxon was administered at time of patient positioning in operating table(intravenous amikacin 500mg was given as alternative to those patient with confirmed cephalosporine hypersensitivity).

Cystoscopy was performed under local anesthesia (water soluble lidocaine) or sedation and in some cases a general or spinal anesthesia may be applied.

Patient was positioned in the lithotomy cystoscopic position, the external genitalia is

cleaned and prepared by using antiseptic solution with derivatives based on Iodine or Chlorhexidine. The external urethral meatus is examined for stenosis or any abnormality including its location and the procedure started by using a semi-rigid cystoscope with a sheath size of 17 French and a 30° lens. The whole length of urethra is visualized and any abnormality was recorded like urethral stricture, or inflamed mucosa in addition to assessment of prostatic size and bladder neck, when the bladder

is entered; full evaluation of its capacity, mucosal abnormalities, presence of stone or growth or foreign body, bladder trabeculation or diverticulum, fistula and presence of outgrowing mass.

Intervention was done for those patients with urethral stricture by dilation or visual internal urethrotomy, litholepaxy done in case of presence of stone, removal of foreign body, TURBT (Transurethral resection of bladder tumor) in presence of mass, and cup bladder biopsy was taken for patients with suspicious bladder mucosal lesions.

All patients were followed up after leaving cystoscopy suite and then discharge to their home in same day with oral antibiotic and on need analgesic for 3-5 days.

In this study; we aimed to evaluate the diagnostic yield and therapeutic achievement of cystoscopy for patient with profound LUTS in both sexes who have normal other initial investigation .

The results are expressed as percentage and the statistical analysis was performed using SPSS software, Chi-square test were applied .

RESULTS

In this study 60 patients were underwent cystoscopy for bothersome long-term lower urinary tract symptoms (LUTS) with normal initial investigations, 32 male and 28 female with a median age of 38 year(range from 21 year to 52 years).

Diagnostic performance was defined as the number of patients with abnormal findings divided by the total number of patients undergoing cystoscopy for this indication.

Cystoscopy was positive (when abnormal findings are detected) in 31 patients (51.6%); 20 male and 11 female according to patient sex.

Negative cystoscopy (i.e. not add any diagnostic value) in 29 patients (48.4%) off total number; 12 male and 17 female. Percentage of patients with positive and negative findings by cystoscopy are shown in figure 1.

The findings that are detected at cystoscopy examination include: Urethral stricture in 3

patients (males), inflammation: prostatitis/ urethritis in 6 patients (5 male and one female patient with sever urethritis), one male patient with significant urethral angulation, two male patients with enlarged prostate, intravesical calculi in 4 patients (2 male and 2 female), bladder diverticulum in 3 patients (2 male and one female), bladder growth in 3 patients (one male and 2 female), one female patient found to have unrecognized small vesico-vaginal fistula, one female patient had nylon suture pass through bladder wall acting as foreign body, trabeculations in 4 patients (3 male and one female), and suspicious bladder mucosal lesions

in 3 patients involving one male and 2 female patients. Percentages and distribution of positive cystoscopic findings in both sexes for the studied patients are summarized in table 1.

Cystoscopic interventional procedures doing in same time of examination were achieved for 14 patients (23.3 %) and includes: Urethral dilatation with urethrotomy done for 3 patients, four patients underwent litholepaxy, TURBT (Transurethral resection of bladder tumor) for 3 patients, removal of stitch foreign body in one patient, and bladder biopsies were taken from 3 patients for suspicious bladder mucosal lesions. These procedures are mentioned in table 2.

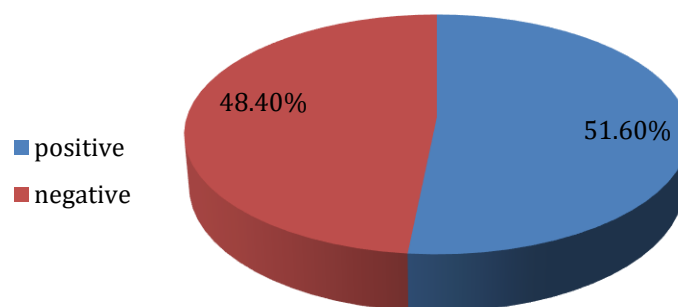


FIGURE 1: Percentage of patients with positive and negative findings by cystoscopy

TABLE 1: Percentages and distribution of positive cystoscopic findings in studied patients.

| Cystoscopic finding | Number of patients | | | Percentage |
|---------------------------------------|--------------------|--------|-------|------------|
| | Male | Female | Total | |
| Urethral stricture | 3 | - | 3 | 5 % |
| Inflammation: Prostatitis/ Urethritis | 5 | 1 | 6 | 10 % |
| Urethral angulation | 1 | - | 1 | 1.7 % |
| Prostatic enlargement | 2 | - | 2 | 3.3 % |
| Intravesical calculi | 2 | 2 | 4 | 6.6 % |
| Bladder diverticulum | 2 | 1 | 3 | 5 % |
| Bladder growth | 1 | 2 | 3 | 5 % |
| Fistula | - | 1 | 1 | 1.7 % |
| Foreign body | - | 1 | 1 | 1.7 % |
| Trabeculation | 3 | 1 | 4 | 6.6 % |
| Suspicious bladder mucosal lesions | 1 | 2 | 3 | 5 % |
| Total | 20 | 11 | 31 | 51.6% |

TABLE 2: Interventional procedures conducted at time of cystoscopy.

| Interventional procedure | Number of involved patients |
|--------------------------------------|-----------------------------|
| Urethral dilatation with urethrotomy | 3 |
| Litholepaxy | 4 |
| TURBT | 3 |
| Foreign body removal | 1 |
| Bladder biopsy | 3 |
| Total | 14 (23.3 %) |

Non-specific abnormalities included 17 cases (28.3 %) from 44 patients with positive cystoscopy includes: inflammation: prostatitis/ urethritis, urethral angulation, bladder diverticulum, trabiculations and abnormal bladder mucosal lesions. Clinically relevant abnormalities were found in the remaining 14 patients (23.3 %).

Those patients who underwent TURBT were subsequently found to have a low grade T1 transitional-cell carcinoma.

Inflammation of prostate and prostatic urethra is the most common finding detected by cystoscopy for men with lower urinary tract symptoms, females patient have no significant specific finding in this study .

There was no significant difference between men and women with regard to the detected findings (P = 0.2).

DISCUSSION

The aim of this study is to evaluate the role of cystoscopy for discovering the cause of lower urinary tract symptoms (LUTS) in men and women with normal initial investigations that had failed initial conservative management. Although most of causative urinary tract disorders could be identified by imaging modalities, some abnormalities could be diagnosed more efficiently by using cystoscopy.

In this study, among 60 patients who underwent cystoscopy, 31 (51.6 %) patients had positive findings and 14 (23.3 %) patients had received therapeutic surgical intervention at same time of examination indicating sufficient diagnostic yield and therapeutic achievement by cystoscopy. Clinically significant abnormalities were found in 14 patients (23.3 %).

In a study conducted by Kumar and colleagues in 1390 patients, cystoscopy was with positive findings in 46.14% and they found that cystoscopy altered management in 14.1% of patients. Bladder cancer was diagnosed in 6.1% of patients [15], Another study by Muhammad A. et al. on 1500 cases, found that there was detection of pathologies by cystoscopy in 32% [19]. These results that are comparable to that which we observed.

In a retrospective study by Lawrentschuk et al. that investigated the diagnostic yield of cystoscopy in 118 female patients, 8% of patients had clinically significant abnormalities [13]. In another study by Howles et al., the diagnostic performance of flexible cystoscopy in patients with lower urinary tract symptoms were examined retrospectively, Thirteen (11.5%) out of 113 patients had significant cystoscopy findings [20].This percentage is close to our results where the positive cystoscopy findings was 11% for female patients.

Lower urinary tract abnormalities can be categorized into bladder-related and urethra-related pathologies . Urethral pathologies present mostly with symptoms of outlet obstruction and are difficult to be diagnosed on ultrasonography alone. Both (bladder and urethral) pathologies can easily be diagnosed by cystoscopy alone [21]. In the present study, the inflammation of prostate and urethra (10%) in addition to urethral strictures (5%) and urethral angulation (1.7%) are a common finding detected in compare to other results.

Young M et al. investigate the most frequent findings detected by cystoscopy, vesical calculus was found in 8.8% patients and urethral stricture in 5.9% [22]. Our findings correlate with this

study which detected urethral stricture in 5% and lithiasis in 6.6% of patients.

Suspicious bladder mucosal lesions are seen as abnormal erythematous patches on bladder mucosa are detected in three patients (5%), biopsies were taken from these patches that were confirmed to be benign after histopathological examination. A study by Howles et al showed that 5% of the patients investigated (6 of 113) had erythematous bladder lesions that were appear to be benign [20].

In our study, one male patient have a significant urethral angulation between the prostatic urethra and the membranous urethra. The anatomical hypothesis behind the prostatic urethral angulation describes the prostatic urethra like a bent tube. Thus it may be a causal factor for LUTS and obstruction [23-25].

Ku et al. [24] retrospectively studied 260 patients with benign prostatic hypertrophy (BPH)/LUTS and determined that a higher prostatic urethral angle (PUA) was associated with higher maximal urethral closure pressure and higher outlet obstruction. Another study showed that PUA equal or more than 34 was associated with both storage and voiding symptoms [26].

Benign prostatic hyperplasia is important and prevalent causes of LUTS in male patients [8]. Two of our male patients (3.3%) were found to have prostatic enlargement and this low number of such cases in our study is due to that we include only patients with normal initial investigation, prostatic enlargement can be diagnosed by many imaging techniques. LUTS in those two patients may due to that the extent of obstruction is more dependent on the shape of prostate rather than size alone. the median lobe protrusion can cause obstructive effects because of the associated distortion of the funneling effect. Although benign prostatic enlargement (BPH) can consider as a cause to the occurrence of LUTS in men over 40 years of age, other factors may considered like neurological, anatomical, metabolic and inflammatory factors [27-30]. AUA guidelines recommend cystoscopy in those patients for whom the appearance of the prostate aids in the choice of surgical treatment.[31,32]

Although cystoscopy need anesthesia and can cause patient discomfort but it discoverer important findings that could be missed by other investigations like urethral stenosis, urethritis, small unrecognized foreign body or fistula or vesical growth and bladder diverticulum which are curable causes of profound LUTS [33-35].

CONCLUSION

LUTS can cause bothersome symptoms and affect life quality of patients. For those patients, even when imaging and other investigations are normal, cystoscopy findings

can be abnormal.

The use of cystoscopy, provide rapid and proper diagnostic workup, and allow some surgical intervention to be done more promptly. It can alter the management as well as support the diagnosis, Furthermore, it is well-tolerated by most of patients which make the cystoscopy a good diagnostic and therapeutic choice.

Cystoscopy should be consider as integral tool in the management of patients with LUTS specially if their initial evaluation does not reveal a convincing cause or had failed initial conservative management.

REFERENCES

1. Engstrom G, Walker-Engstrom ML, Henningsohn L, Loof L, Leppert J. Prevalence of distress and symptom severity from the lower urinary tract in men: a population-based study with the DAN-PSS questionnaire. *Family practice*. 2004 Dec;21(6):617-22.
2. Abrams P. New words for old: lower urinary tract symptoms for "prostatism". *BMJ (Clinical research ed)*. 1994 Apr 9;308 (6934):929-30.
3. Anna Lena Wennberg, Ulla Molander, Magnus Fall, Christer Edlund, Ralph Peeker and Ian Milsom. Longitudinal population-based survey of urinary incontinence, overactive bladder and other lower urinary tract symptoms in women. *Eur Urol* 2009;55(4):783-791.
4. Jerry G. Blaivas, Johnson F. Tsui . Male lower urinary tract symptoms: The role of urodynamics. *Urological Science* . 2012 ; 23 : 18-25.
5. D. De Ridder, T. Roumeguere, L. Kaufman, Urgency and other lower urinary tract symptoms in men aged \geq 40 years: a Belgian epidemiological survey using the ICIQ-MLUTS questionnaire, *Int. J. Clin. Pract.* 69 (2015)

- 358e365.
6. Oelke M, Bachmann A, Descazeaud A, Emberton M, Gravas S, Michel MC, et al. Guidelines on the management of male lower urinary tract symptoms (LUTS), including benign prostatic obstruction (BPO). In: EAU guidelines, edition presented at the 27th EAU Annual Congress, Paris 2012; 2012.
 7. Robertson C, Link CL, Onel E, Mazzetta C, Keech M, Hobbs R, et al. The impact of lower urinary tract symptoms and comorbidities on quality of life: the BACH and UREPIK studies. *BJU Int* 2007;99:347e54.
 8. P. Abrams, C. D'ANcona, D. Griffiths, et al. Lower urinary tract symptom: etiology, patient assessment and predicting outcome from therapy. In: J.D. McConnell, P. Abrams, L. Denis, S. Khoury, C.G. Roehrborn (Eds.), 6th International Consultation on New Developments, (n.d.).
 9. Takeda M, Araki I, Kamiyama M, et al. Diagnosis and treatment of voiding symptoms. *Urology* 2003; 62:11-9.
 10. Moreno E, Andreu A, Perez T, et al. Relationship between *Escherichia coli* strains causing urinary tract infection in women and the dominant faecal flora of the same hosts. *Epidemiol Infect* 2006; 134(5):1015–23.
 11. Irwin DE, Milsom I, Kopp Z, et al. Impact of overactive bladder symptoms on employment, social interactions and emotional well-being in six European countries. *BJU Int.* 2006;97:96–100.
 - I. Shoukry, J.G. Susset, M.M. Elhilali, D. Dutartre, Role of uroflowmetry in the assessment of lower urinary tract obstruction in adult males, *Br. J. Urol.* 47 (1975) 559-566.
 12. Lawrentschuk N, Ooi J, Pang A, et al. Cystoscopy in women with recurrent urinary tract infection. *Int J Urol* 2006;13: 350–353.
 13. van Haarst EP, van Andel G, Heldeweg EA. Evaluation of diagnostic workup in young women referred for recurrent urinary tract infections. *Urolog.* 2001;57:1068 72.
 14. Kumar V, Patel HR, Nathan SM, Miller RA, Lawson AH. Do we need to perform cystoscopy on all adults attending urology centres as outpatients? *Urol Int.* 2004;73(3):198–200.
 15. Kadi N, Menezes P. ABC of flexible cystoscopy for junior trainee and general practitioner. *Int J Gen Med* 2011; 4: 593-6
 16. Wein MD, PhD, FACS, Alan. "Principles of Endoscopy." Campbell-Walsh Urology tenth edition. Philadelphia, PA: Elsevier/Saunders, 2012.
 17. McAninch, Jack W. "Retrograde Instrumentation of the Urinary Tract." Smith and Tanagho's general urology editors, Jack W. McAninch, Thomas F. Lue. 18th Ed. New York: McGraw-Hill Professional, 2013.
 18. Muhammad A, Hana K, Mobasher S, Omer S. Flexible cystoscopy a valuable diagnostic tool for lower urinary tract pathology. *Journal of the Pakistan Medical Association* · March 2015.
 19. Howles S, Tempest H, Doolub G, Bryant RJ, Hamdy FC, Noble JG, et al. Flexible cystoscopy findings in patients investigated for profound lower urinary tract symptoms, recurrent urinary tract infection, and pain. *J Endourol.* 2012;26(11):1468 72.
 20. Khadra MH, Pickard RS, Charlton M, Powell PH, Neal DE. A prospective analysis of 1,930 patients with haematuria to evaluate current diagnostic practice. *J Urol* 2000; 163: 524-7.
 21. Young M, Martínez S, Del Rosario J, Anguizola C. [Bladder endoscopy (cystoscopy): indications and most frequent findings at the Metropolitan Hospital Complex of the Social Security Fund of Panama, 1997]. *Rev Med Panama* 1998; 23: 20-3.
 22. Cho KS, Kim J, Choi YD, Kim JH, Hong SJ. The overlooked cause of benign prostatic hyperplasia: prostatic urethral angulation. *Med Hypotheses* 2008;70:532e5.
 23. Ku JH, Ko DW, Cho JY, Oh SJ. Correlation between prostatic urethral angle and bladder outlet obstruction index in patients with lower urinary tract symptoms. *Urology* 2010;75: 1467e71.
 24. Park YJ, Bae KH, Jin BS, Jung HJ, Park JS. Is increased prostatic urethral angle related to lower urinary tract symptoms in males with benign prostatic hyperplasia/lower urinary tract symptoms? *Korean J Urol* 2012;53:410e3.
 25. C.R. Chapple, C.G. Roehrborn, A shifted paradigm for the further understanding, evaluation, and treatment of lower urinary tract symptoms in men :focus on the bladder, *Eur. Urol.* 49 (2006) 651-658, [j.eururo.2006.02.018](https://doi.org/10.1016/j.eururo.2006.02.018).
 26. AUA guideline on management of benign prostatic hyperplasia (2003). Chapter 1: diagnosis and treatment recommendations. *J Urol* 2003;170:530e47.
 27. ZADEH, Firoozeh Abolhasani, et al. Cytotoxicity evaluation of environmentally friendly synthesis Copper/Zinc bimetallic nanoparticles on MCF-7 cancer cells. *Rendiconti Lincei. Scienze Fisiche e Naturali*, 2022, 1-7.
 28. ROHMAH, Martina Kurnia, et al. Modulatory role of dietary curcumin and resveratrol on growth performance, serum immunity responses, mucus enzymes activity, antioxidant capacity and serum and mucus biochemicals in the common carp, *Cyprinus carpio* exposed to abamectin. *Fish & Shellfish Immunology*, 2022, 129: 221-230.
 29. ARIF, Anam, et al. The functions and molecular mechanisms of Tribbles homolog 3 (TRIB3) implicated in the pathophysiology of cancer. *International Immunopharmacology*, 2023, 114: 109581.
 30. MARGIANA, Ria, et al. Functions and

- therapeutic interventions of non-coding RNAs associated with TLR signaling pathway in atherosclerosis. *Cellular Signalling*, 2022, 100: 110471.
31. H. A. Al-Hchaimi, M. F. Alhamaidah, H. Alkhfaji, M. T. Qasim, A. H. Al-Nussairi and H. S. Abd-Alzahra, "Intraoperative Fluid Management for Major Neurosurgery: Narrative study," 2022 International Symposium on Multidisciplinary Studies and Innovative Technologies (ISMSIT), 2022, pp. 311-314, doi: 10.1109/ISMSIT56059.2022.9932659.
 32. MOHAMMED, Zainab; QASIM, Maytham T. The Relationship between Insulin Resistance and Hypertension in Patient with Hypertensive. *HIV Nursing*, 2022, 22.2: 1659–1663-1659–1663.
 33. LEI, Zimeng, et al. Detection of abemaciclib, an anti-breast cancer agent, using a new electrochemical DNA biosensor. *Frontiers in Chemistry*, 2022, 10.
 34. BASHAR, Bashar S., et al. Application of novel Fe₃O₄/Zn-metal organic framework magnetic nanostructures as an antimicrobial agent and magnetic nanocatalyst in the synthesis of heterocyclic compounds. *Frontiers in Chemistry*, 2022, 10.