



Clinical Performance of Ceramic Laminate Veneers Made with Celtra Press and IPS E. Max Press Ceramic (Randomized Controlled Clinical Trial)

Shafeq Aqlan¹, Lamia Kheiralla², Gihan El-Naggar³

¹ PhD candidate at the Department of Fixed Prosthodontics, Faculty of Dentistry, Cairo University, Egypt

¹ lecturer assistant at the Department of Fixed Prosthodontics, Faculty of Dentistry, Hodeidah University, Yemen

^{2,3} Professor at the Department of Fixed Prosthodontics, Faculty of Dentistry, Cairo University

Corresponding Author: Shafeq Aqlan ,PhD candidate at the Department of Fixed Prosthodontics, Faculty of Dentistry, Cairo University, Egypt, Lecturer assistant at the Department of Fixed Prosthodontics, Faculty of Dentistry, Hodeidah University, Yemen

Email: shafeq.hashem@dentistry.cu.edu.eg, shafeqaqlan@gmail.com,
Lamia.kheiralla@dentistry.cu.edu.eg, gihan.elnaggar@dentistry.cu.edu.eg

Submitted: 10 January 2023; Accepted: 09 February 2023; Published: 14 March 2023

ABSTRACT

Objective: To assess the clinical performance (color matching and stability, fracture, marginal adaptation, patient satisfaction, and sensitivity) of laminate veneers constructed from Celtra press ceramic and IPS e.max press ceramic with incisal wrap design (split-mouth design).

Methodology: Thirty-four ceramic laminate veneers were fabricated for maxillary anterior teeth in six patients. The veneers were randomly divided into two groups based on their material. Group I (the control group) was constructed from IPS e.max press veneers, and Group II (the intervention group) was constructed from Celtra press veneers. The follow-up sessions were performed after 24 hours of cementation (the baseline), then every three months for up to a year for each patient, using a dental probe and operator vision to assess color matching, fracture, and sensitivity in accordance with USPHS criteria. A spectrophotometer (Vita EasyShade®V) was also used to assess the color stability of the restoration. Patients' satisfaction was also evaluated using a questionnaire chart.

Results: An insignificant difference in both groups was revealed, considering color matching, color stability, fractures, marginal adaptation, and sensitivity at all follow-up intervals. While patients' satisfaction results showed a statistically significant difference in some evaluated factors, there wasn't a clinically significant difference.

Conclusion: After one year of follow-up, both Celtra press laminate veneers and IPS e.max press laminate veneers showed successful clinical performance in anterior teeth requiring conservative labial laminate veneers with incisal wrap design in terms of color matching and color stability, fracture, marginal adaptation, sensitivity, and patient satisfaction.

Keywords: color matching and stability; fracture; sensitivity; marginal adaptation; patient satisfaction; split-mouth

INTRODUCTION

Porcelain laminate veneers are cosmetic restorations that make teeth look better while causing minimal damage to the teeth. Their clinical performance depends on a number of factors, such as the case selection, the design of the preparation, the manufacturing techniques, the type of materials used, and the luting protocol [1].

PLV failure can be manifested by a variety of optical, psychological, biological, and mechanical problems, including color change, patient satisfaction, porcelain fracture, delamination, sensitivity, periodontal disease, caries, and tooth fracture. The natural appearance of ceramic restorations is mostly determined by the optical properties of ceramic materials. Several factors influence these properties, including composition, crystalline content, porosity, additives, particle size, and the angle of light incident [2]. Ceramic materials have a wide range of optical properties, including color (hue, chroma, and value), translucency, opalescence, and refractive index. Many factors can affect the color stability of dental ceramics, including extrinsic dyes, ceramic material type, thickness, the cement layer, sintering, and porosity [3]. The quantity and severity of cracks in ceramic restorations have the most significant effect on fracture strength. These cracks may form either before or after the cementing process. Ceramics typically have a considerable amount of preexisting cracking. Condensation, melting, and sintering; variations in the thermal expansion coefficient between cores and veneers; and grinding are also contributory variables. Postoperative cracks have been attributed to loading, polymerization shrinkage, and thermocycling [4]. The clinical durability of any cemented restoration, including laminate veneers, is widely established to be dependent on a variety of parameters, the most important of which is marginal accuracy. Marginal discrepancies between the prepared tooth structure and the restorations might induce oral fluid leaks beneath the restoration, resulting in cement disintegration, recurrent caries, sensitivity, and marginal discoloration [5], [6]. Post-cementation hypersensitivity is an additional cause of postoperative discomfort. When vital teeth are exposed to heat or chemical stimuli after cementation, this symptom manifests as a brief, intense pain. Typically, this form of hypersensitivity is self-healing, but it is unpleasant [7]. Besides dentinal sealing, the luting resin film thickness appears to influence the occurrence of post-cementation sensitivity [8]. The patient's satisfaction with a particular aspect of a service can be regarded as positive or negative, and the level of satisfaction can be measured by the difference between expectations and what is obtained. When performance is below expectations, dissatisfaction

occurs [9], [10]. The null hypothesis was that there would be no difference in the clinical performance (color matching and stability, fracture, patient satisfaction, marginal adaptation, and sensitivity) of laminate veneers constructed from either Celtra press ceramic or IPS e.max press ceramic with incisal wrap design.

MATERIALS AND METHODS

The Ethical Committee of the Faculty of Dentistry at Cairo University in Egypt created the guidelines for this study and the model informed consent form. A sample size was calculated based on a previous study [11], using an alpha (α) level of 5% and beta (β) level of 20%, i.e., power = 80%; the minimum estimated sample size was a total of 34 veneers (17 subjects per group) after compensation for a dropout rate of 25%. A total of six patients were included in this study (five of them received six laminate veneers for upper incisors and canines, and the last one received four laminate veneers for upper incisors), with an age range of 28 to 37 years old. All of them have multiple spacing in their upper anterior teeth, with some teeth having mild malposition. Their main complaint was that they needed to improve their smile. To avoid possible disturbing differences in cases where distinct degrees of tooth discoloration would occur between restorations of different materials, a modified split-mouth design was employed in which the central incisors received the same type of restoration and the lateral incisors also received the same type of restoration. While the canines received a different type of restoration through block randomization. The participant, operator, and statistician were blinded. The researcher did all the steps except for those that make him non-blind, such as dealing with the lab, treating the surface of the veneers, etc., which were done by a second operator.

Inclusion criteria: All participants had to be at least 18 years old and able to read and sign the informed consent document. Have no active periodontal or pulpal diseases; have good restorations on their teeth; have problems with their teeth that can be restored with laminate veneers without changing their color (such as multiple diastemas, enamel fracture, chipping, and mild malposition); have a thickness of at least 2 mm at the incisal area; be willing to come back for follow-up exams and evaluations; and have a normal bite (angle class I).

Exclusion criteria: Patients in the growth stage with partially erupted teeth, fractured teeth with more than 50% enamel loss, poor oral hygiene and motivation, pregnant women, a lack of opposing occluding dentition in the restoration area, and patients with parafunctional habits (e.g., bruxism, biting on hard objects).

Diagnostic phase:

There are many steps that have been taken to ensure the optimal selection of cases. These include an intra-oral examination, radiographic evaluation, scaling, and polishing. The color of the teeth was recorded visually using the VITA-classic shade guide system under natural daylight on days with a clear sky and confirmed under incandescent light to avoid metamerism, following all justified principles of visual shade selection steps. A spectrophotometer (Vita EasyShade®V) was also used to evaluate the color. The "averaged shade measurement" mode of color evaluation was selected, and six measurements were taken for each tooth, with the tip of the device placed at the center of the tooth at a 45/0° angle to record the tooth shade. The confirmed shade tab in the middle third of the tooth was written down in the patient's file and called a "reference shade tab," to be used later to assess the color match during follow-up intervals. Diagnostic casts were mounted on a semi-adjustable articulator (Bio-art articulator A7 plus, Brazil) to evaluate horizontal and vertical overlap (overjet and overbite) between the maxillary and mandibular incisors before the procedure in order to maintain the anterior guidance. Using a professional camera (D2000 DSLR camera, canon, Japan) equipped with a ring flash (YONGNUO Macro Flash YN-14EX,

China), extra-oral and intra-oral images were taken of every patient before the procedure.

Digital Smile Design (DSD) and digital wax-up:

All the extra oral and intraoral photos with different views and videos that were needed for digital smile design and diagnostic casts were sent to the lab, which followed the following main steps: The scanning of diagnostic casts with an extra oral scanner (SHINING 3D-EX Pro, Poland) was done. Then the lab brought the scanned file and digital photos into the 3D digital design software (Exocad View 3D-version 1.5.7270). The lab merged the 2D smile photo and the 3D scan file. Then the digital smile silhouette template was overlaid over the patient's smile image, automatically adding and editing guidelines and selecting outline shapes on the 2D image (Figure 1-a). The patient's virtual teeth were digitally reshaped to conform to the smile template. The 3D modeling allowed evaluation from various angles (Figure 29-b). After that, a 3D model and a proposed "wax-up" were tested for articulation. A digital wax-up and imaging were presented to the patient and discussed with them for any modifications.

Lastly, the STL file was sent to the 3-D printer (Creality Halot-One CL-60 Resin 3D Printer, China) to make a resin 3D model (3D printer UV curable resin, Creality, China), which then went through the cleaning and curing machine (Creality UW-02 Washing and Curing Machine, China). The cured model was then used to make a putty index with condensation silicon (Silaxil, LASCOD, Italy) that would be used later for mock-up application (Figures 2 a, b).

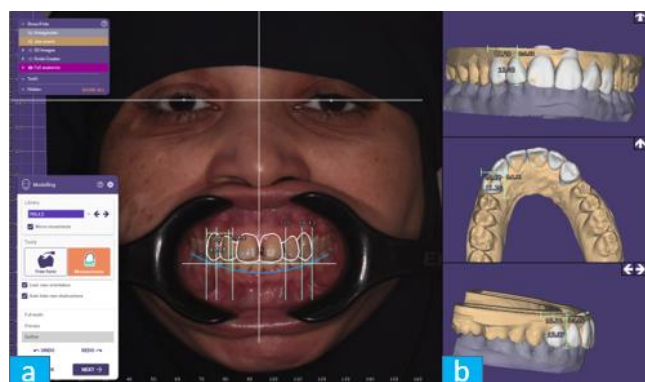


Figure 1: (a) Digital smile silhouette template, (b) 3-D evaluation from various angles

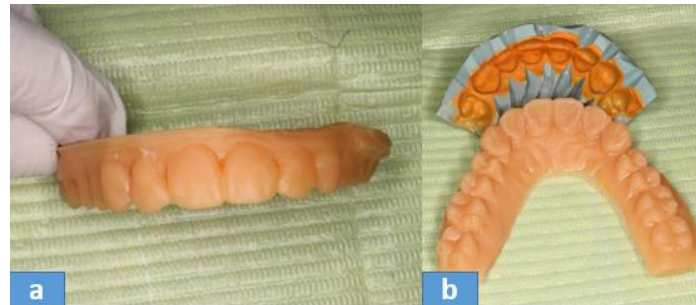


Figure 2: (a) 3-D printed model, frontal view; (b) lingual view with silicon index

Teeth preparation phase

The silicon index received from the lab and fabricated over the 3-D printed model was used for mock-up construction using bisacrylate composite resin (CharmTemp Crown®, Dentkist, Korea). The mockup was then evaluated, discussed with patients, and sometime later modified based on functional and aesthetic requirements. Using the putty condensation silicone over the modified mock-up, another two indices were obtained for each patient. The first index was vertically cut at the midpoint of the central, lateral, and canine teeth. The second index was horizontally cut into three levels (cervical, middle, and incisal) to assess the amount of preparation in the incisal area and labial surfaces. The Komet ceramic veneer system (REF: 4151, Komet, Germany) was used for all steps of preparation and finishing. The labial reduction was 0.5 mm at the cervical third and 0.8 mm at the middle to ensure even preparation thickness. The preparation was done on two different planes, following the contour of the labial surface. Vertical orientation grooves were done on the incisal edge of the tooth, ensuring that they did not penetrate more than the diameter of the stone visually. The tapered diamond stone with a round end was placed parallel to the incisal edge to remove the projection between grooves, resulting in a 1.5-mm incisal preparation. Then 1-1.5 mm of incisal overlap with a palatal chamfer of 0.5 mm was done, which was placed away from the contact. A chamfer finish line of 0.5 mm in diameter was used to terminate the cervical margin supragingivally (Figure 3). Immediate dentin sealing (IDS) was applied in the area of exposed dentin, which was determined clinically to some extent as the enamel appears dry while the dentin has a shiny appearance due to intrinsic humidity. Acid etching was applied for 15 seconds, then

rinsed with water before applying the bond (All-bond universal, BISCO, USA) with a small brush, followed by 30 seconds of light curing.

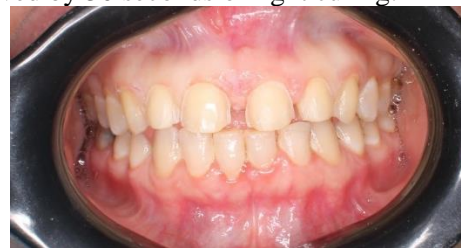

Figure 3: teeth immediately after preparation

Impression and Provisionalization

To manage soft tissue around the prepared teeth, a retraction cord (Ultra pak cord, Ultradent, USA) was used, and the final impression was taken in stock trays with addition silicon (Panasil, Kettenbach, Germany). A two-step impression technique was used. The silicon index that was taken from the mock-up was used for provisional restoration construction. All prepared teeth were spot-etched on the buccal surface in the middle, followed by water rinsing. On the lingual surface of each provisional restoration opposing the etched area, a dimple was created, and temporary cementation was performed by applying flowable composite (Nova Compo, NOVA, Turkey) after bond application and then light curing for 30 seconds.

PMMA Restoration Fabrication for Try in

Burnable and machinable CAD/CAM PMMA discs (98.5mm x 25mm) (PMMA discs, Ymahachi Dental, JAPAN) were used to create the waxing-up step. The resulting PMMA veneers served as both a try-in and a mold for the fabrication of final ceramic veneers. Each cast was scanned using an extra oral scanner (SHINING 3D-EX Pro, Poland) to produce three-dimensional (3D) images of the models, which were stored on the computer's hard

disc. Defining the preparation margins of each tooth was performed automatically. Then, after defining the insertion axis, the cement space was set to 80 μm for each restoration, and it was omitted at the margins of the preparation in order to ensure perfect adaptation of the restoration. Then the restorations were designed and adjusted to the proper shape, size, and dimensions (Figure 4). The PMMA veneers were initially tried one by one in order to check marginal fit and then placed all together to see their overall integration with each other, with the lips, and finally with the face. Checking alignment and contour was also done. Then a discussion was had with the patient to see if there was any correction desired regarding his aesthetic and functional needs. All notes were then sent to the lab.

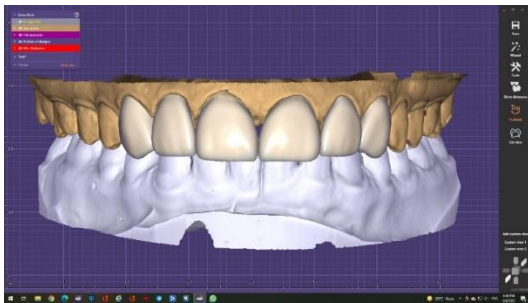


Figure 4: Designing and adjustment of the restorations

Final restoration fabrication

The technician used white wax to make the suggested modifications (if any) to the PMMA try-in veneers. The correction may include margins, embrasures, thickness, and others. The spruing and investing of PMMA veneers were done according to manufacturer instructions. Both materials were pressed in a specialized furnace in

accordance with the manufacturers' recommendations (IPS Empress EP 600 hot press furnace, Ivoclar-Vivadent, Germany). Then, the steps suggested by the manufacturer for divesting and glazing were used on both materials. The final laminate veneers were initially tried one by one in order to check marginal fit and then placed all together to see their overall integration with each other, with the lips, and finally with the face.

Cementation of final restorations

Before surface treatment and cementation, each laminate was placed in a digital ultrasonic cleaner for about 180 seconds with ethyl alcohol at a concentration of 90% to remove debris. The inner surfaces of the veneer restorations were etched using 9.5 % hydrofluoric acid gel (Porcelain Etchant 9.5%, BISCO, USA) according to the manufacturer's instructions: 20 seconds for IPS e-max Press veneers and 30 seconds for Celtra Press veneers. The veneers were air dried after being cleaned with water. The bonding surface of the veneers was then treated with a single application of the ceramic primer (Ceramic Primer, BISCO, USA) and allowed to react for 1 minute before being air dried. The enamel was etched for 30 seconds with a 37% phosphoric acid etchant. After being cleaned and dried, the enamel appeared frosty. The tooth surface was coated with two layers of adhesive (All-bond universal, BISCO, USA). Light-cured resin cement (Choice 2-bisco, Bisco, USA) was used to bond the veneers in place. The veneers were then completely light polymerized with an energy density of 480 mW/cm for at least 40 seconds on each aspect of the tooth. Preoperative and postoperative photographs are shown in Figure 5.

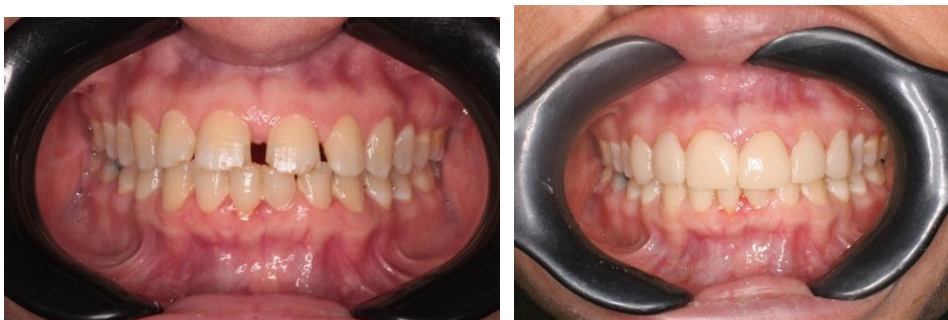

Figure 5: Preoperative and postoperative frontal views

Follow up phase

Follow-up sessions were held 24 hours after the cementation (the baseline) and then every three months for a year. The operator, who is the primary researcher, performed the assessment. An assessment was done for each patient to evaluate color matching clinically as a primary outcome using modified USPHS criteria (Table 1) by comparing the restoration in the middle third to the "reference shade tab" under natural day light and confirmed under incandescent light. The color stability of restorations was also evaluated instrumentally by using the Vita Easy Shad® V spectrophotometer to support the results of the visual evaluation of color. The "averaged shade measurement" mode of color evaluation was

selected, and six measurements were taken for each tooth, with the tip of the device placed at the center of the tooth at a 45/0° angle, and the L, a, and b values were documented at the base line and then every three months for a year. The color change (ΔE) was calculated by comparing follow-up interval values to the base line values. Using modified USPHS criteria, a sharp new dental probe and the operator's vision were used to look for signs of cracks, fractures, marginal adaptation, and sensitivity. This was done with the help of a hand-held 5X magnifying lens with eight LED lights for lighting. Patient satisfaction was evaluated using a questionnaire (Table 2).

Table 1: List of modified United States Public Health Service criteria used for the clinical evaluations of the restorations.

	Outcome name	Measuring device	Measuring Unit
Primary 1ry outcome	Color matching	(USPHS)	0 Excellent color match 2 good color match 3 Slightly mismatching 3 Obvious mismatches 4 Gross mismatch/aesthetically displeasing color, shade and/or translucence.
Secondary outcomes	Fracture	(USPHS)	0 no fracture 1 minor cracks line over the restoration 2 minor chipping of the restoration (1/4) 3 moderate chipping of the restoration (1/2) 4 sever chipping of the restoration 5 complete fracture
	Marginal adaptation	(USPHS)	0 smooth margin 1 enamel exposed 2 base or dentin exposed 3 debonding from one end 4 debonding from both ends
	sensitivity	(USPHS)	0 no sensitivity 1 slight sensitivity 2 moderate sensitivity 3 sever sensitivity

Table 2: Patient Satisfaction Questionnaire

No	Questions	No	Questions
Q1	Are you satisfied with the size of the new laminate?	Q6	Do you like your laminate's alignment?
Q2	Are you satisfied with your laminate color?	Q7	Do you like your general appearance?
Q3	Have you noticed any color change in your laminate until now?	Q8	Do you feel that the laminate is in harmony with the adjacent teeth?
Q4	Do you feel that your laminate looks	Q9	Have you experienced gingival or periodontal

	natural?		inflammation around the laminate after its insertion?
Q5	Have you suffered from any kind of pain or problem during laminate use?	Q10	Has the laminate stability affected through last time?

RESULTS

Frequencies and percentages were used to present qualitative data. To compare the two groups, the chi-square test was performed. The Shapiro-Wilk and Kolmogorov-Smirnov normality tests were used to check the normality of quantitative data, and it was found that all of the data were parametric (P -value > 0.05). The data were shown as the mean and standard deviation. An independent t-test was used to compare the two groups. Using a repetitive one-way ANOVA and

the Tukey's Post Hoc test for multiple comparisons, different intervals were compared. The data was analyzed using IBM SPSS Statistics for Windows, Version 20.

Results of the color match

The comparison between groups I and II revealed an absolute insignificant difference at a p value of 1.00, as all participants revealed "good match scores" (100%) in both groups at all intervals, as presented in Figure 6.

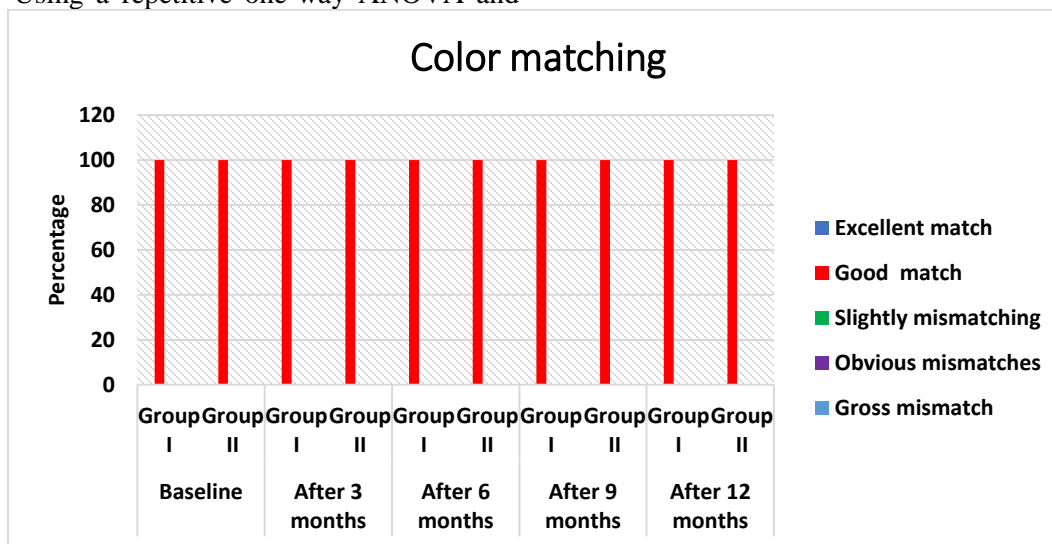


Figure 6: Bar chart representing results of the color match score in both groups (I and II) at different follow-up intervals and the comparison between them.

Results of the color change (ΔE)

The comparison between groups I and II revealed an insignificant difference between them as $P > 0.05$ in all intervals, as presented in Table 3 and Figure 7.

Table (3): Results of the color change (ΔE) of laminate veneers at the follow-up intervals

Follow-up intervals	Group I IPS e.max press ceramic veneer		Group II Celtra press ceramic veneer		P value
	M	SD	M	SD	
After 3 months	2.11	0.43	2.10	0.43	0.96
After 6 months	2.18	0.65	2.36	0.43	0.34
After 9 months	2.35	0.65	2.22	0.53	0.52
After 12 months	2.45	0.58	2.45	0.51	1.000
Overall	2.29	0.47	2.27	0.58	0.95

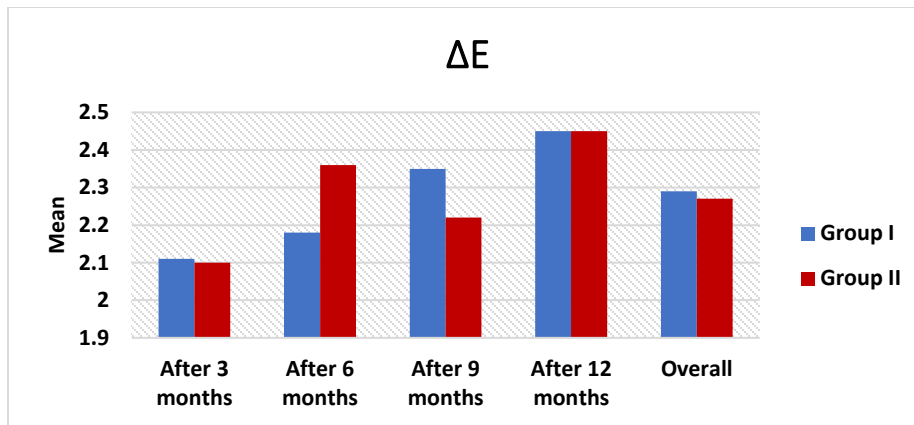


Figure 7: Bar chart representing results of the color change (ΔE) in both groups (I and II) at different follow-up intervals and the comparison between them.

Results of the fracture

The comparison between groups I and II revealed an absolute insignificant difference at a p value of

1.00, and all participants revealed a "0 score" (no fracture) (100%) in both groups at all follow-up intervals, as presented in Figure 8.

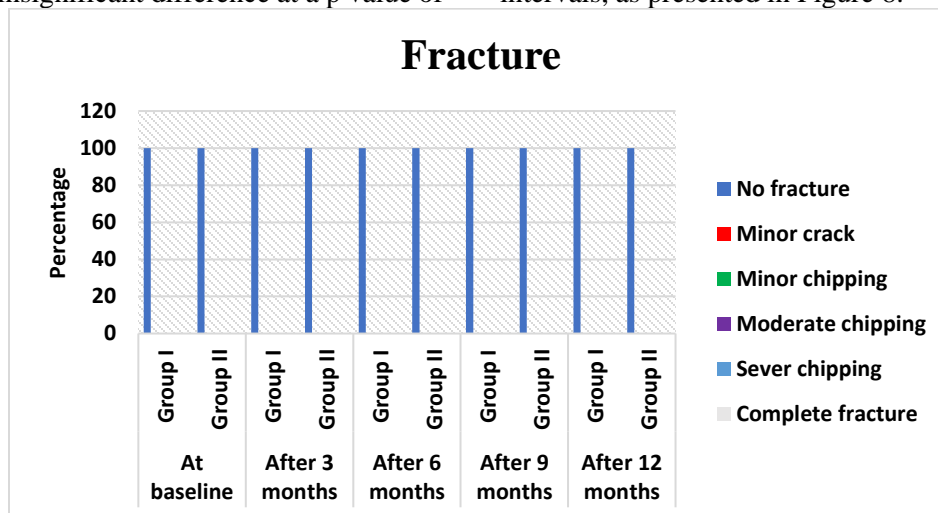


Figure 8: Bar chart representing results of the fracture score in both groups (I and II) at different follow-up intervals and the comparison between them.

Results of the marginal adaptation

The comparison between both Groups I and II revealed an absolutely insignificant difference at a

p value of 1.00, as all participants revealed a "0 score" (smooth margin) of 100% in both groups at all intervals, as presented in Figure 9.

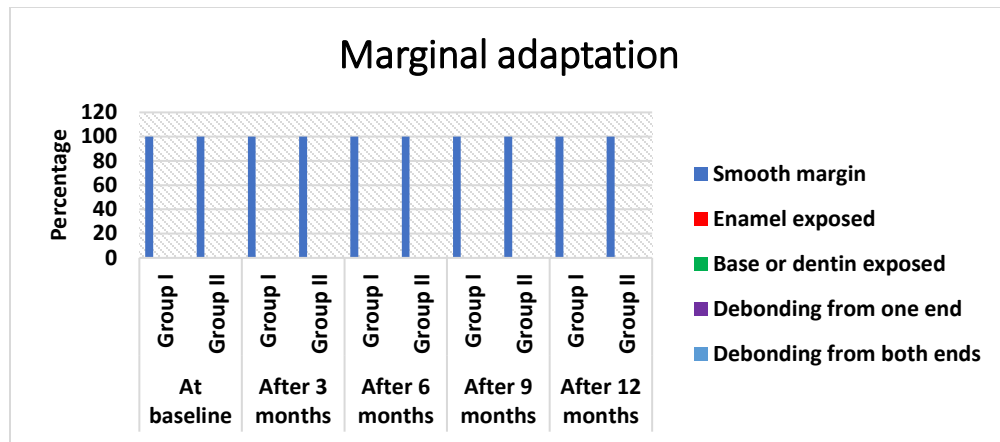


Figure 9: Bar chart representing results of the marginal adaptation score in both groups (I and II) at different follow-up intervals and the comparison between them.

Results of the patient's satisfaction

A comparison between both groups was performed at different intervals for all questions and revealed that: At baseline, there was a significant difference in Q1 (group I was higher than group II), Q4 and Q8, and overall (group I was lower than group II). After 3 months, there was a significant difference in Q1, Q2, and Q4 (group I was lower than group II), and Q6, and Q7 (group I was higher than group II). After 6 months, there was a significant difference in Q2 and Q4 (group I was lower than group II) and Q6 and Q7 (group I was higher than

group II). After 9 months, there was a significant difference in Q1, Q2, and Q8 (group I was lower than group II) and Q7 (group I was higher than group II). After 12 months, there was a significant difference in Q1, Q2, and Q4 (group I was lower than group II) and Q7 (group I was higher than group II). Overall, there was a significant difference at the base line (group I was lower than group II), while there was an insignificant difference between all other intervals as presented in Figure 10.

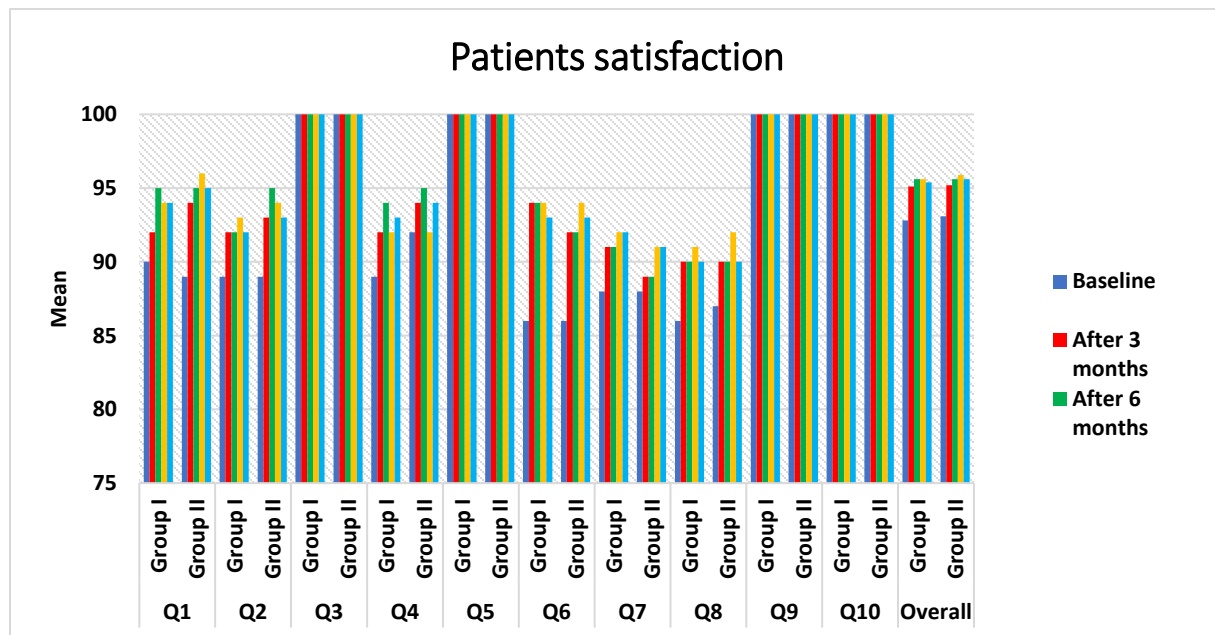


Figure 10: Bar chart representing results of the patient's satisfaction in both groups (I and II) at different follow-up intervals and the comparison between them.

Results of the sensitivity

The comparison between groups I and II revealed an insignificant difference ($P > 0.05$), as all participants' restorations revealed a "0 score" (no sensitivity) and a "1 score" (slight sensitivity) at

baseline, while all participants revealed no sensitivity at all other intervals, as presented in Figure 11.

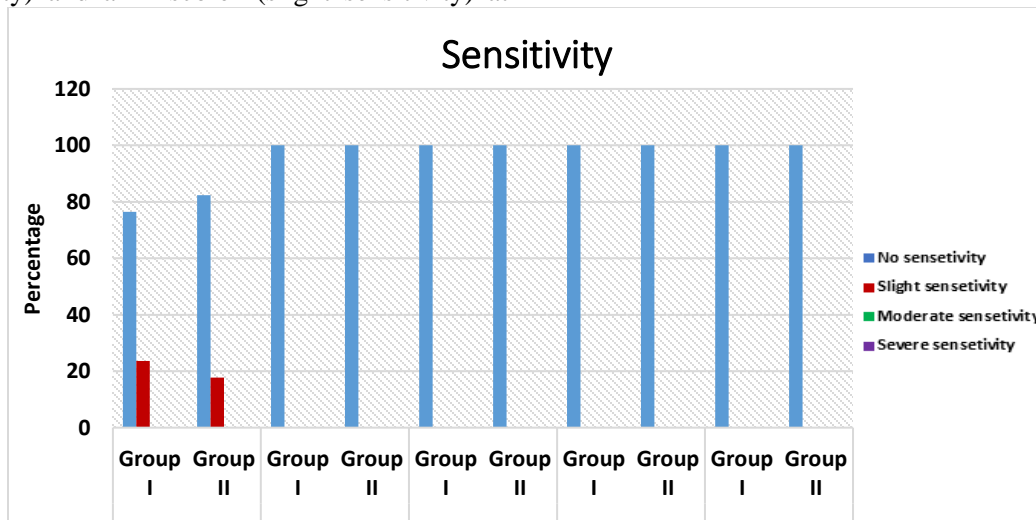


Figure 11: Bar chart representing results of the sensitivity in both groups (I and II) at different follow-up intervals and the comparison between them

DISCUSSION

In the current study, we chose an in vivo study design because in vivo studies have been said to be the best way to figure out the criteria for approved restorations. A randomized controlled trial with a split-mouth design is better than a whole-mouth design because it reduces the amount of variation between subjects. This makes the study more powerful. On the other hand, blinding was suggested in the trial to prevent performance and detection biases [12][13].

In some clinical circumstances, such as multiple spacing, mild malposition, and fracture or chipping of anterior teeth, it is recommended to use ceramic laminate veneers with adequate strength and excellent optical properties. According to the manufacturer, the newly introduced Celtra Press ceramic, which is a zirconia-reinforced lithium silicate, possesses enhanced strength and optical properties and could be used as a substitute for lithium disilicate ceramic (IPS e.max press) in the fabrication of ceramic laminate veneers with an incisal wrap design (stress-bearing area and aesthetic clinical situation). It was reported that the middle third of the labial surface of the tooth was the best area for representing tooth color and yielded the most reliable color measurements [14].

A **digital smile design** was performed on each patient to aid in the creation and projection of the new smile design by simulating and previsualizing the outcome of the recommended treatment. It also involves the patient in the process of designing their own smile. This allows the smile to be tailored to the individual's needs and wants, improving the patient's morpho-psychological traits [15].

Bisco Choice 2 was used for veneer cementation to their correspondingly prepared teeth because it is a light-cure resin cement with high efficiency light curing and excellent color stability, as well as high wear resistance, low film thickness, and high bond strength to the tooth and restoration [16].

In the present study, **color matching** was the primary outcome because it is thought to be the most important factor from the patient's aesthetic point of view. It is also the first factor that determines the level of satisfaction with porcelain veneers [17].

The color matching of IPS e.max press veneers and Celtra press veneers was done by comparing them to the corresponding "reference shade tab" at different follow-up intervals using modified USPHS criteria. As in some clinical situations in which all anterior teeth are required to be restored by laminate veneer restorations and the patient

needs to maintain the original color of the teeth, the color matching evaluation between cemented veneer restorations and basic tooth color can be done by comparing them to a selected reference shade guide tab [18], [19], or by using standardized photographs [20],[21]. The "**reference shade tab**" was used in the present study for visual color matching evaluation, according to **Mf et al. (2021)** [22], who reported that the visual approach is more accurate for shade evaluation than the digital camera and smart phone camera approaches.

In the present study, **the color stability** of veneer restorations constructed from both tested materials was also evaluated using a Vita EasyShade®V spectrophotometer (ΔE change) to support the results of the visual assessment. As recommended by many authors, when possible, both instrumental and visual color matching methods should be utilized since they complement one another and can lead to predictable results. Color stability is one of the requirements for long-lasting aesthetics in dental restorations. Due to aging and staining, dental materials may demonstrate color shifting following intraoral placement [23]. Moreover, the type of resin cement and their mode of polymerization play a major role in the color stability of the ceramic veneer restoration [24], [25].

In the present study, **the fracture** of laminate veneer restorations was evaluated as a secondary outcome, as it appears to be the most prevalent complication of porcelain laminate veneers, followed by debonding, both of which occur more frequently within the first year after veneer cementation [1].

The **marginal adaptation** was visually inspected with a dental mirror and a new Sharpe dental probe with the help of a handheld magnifying lens (5X) using modified USPHS criteria. According to **Hayashi et al. (2005)** [26], who found that the dental explorers' tip diameter significantly affected the ability to detect marginal gaps. **Boeckler et al. (2005)** [27], also reported that the objective measurement of marginal gaps and overextended margins coincided significantly with their subjective assessment by dentists and technicians.

The general public is becoming more conscious of their overall appearance. According to reports, dental aesthetics has a significant impact on patients' satisfaction and general acceptance of

their overall appearance [28]. The current study used the questioner to assess patient satisfaction with the tested veneers in both groups while taking into account a number of parameters that describe the aesthetic and biological characteristics that patients will evaluate during follow-up intervals.

In the present study, **post-cementation sensitivity** was also evaluated using modified USPHS criteria. Because after tooth preparation and cementation, there have been various suggested sources for abutment sensitivity, Aggressive tooth preparation, insufficient temporary restorations, the removal of the protective smear layer, in-vivo luting agent degradation at the restoration margins, and hydraulic pressure on the dentinal tubules induced by cementation are some of them, and although this kind of hypersensitivity usually heals by itself, it is uncomfortable [29].

In the present study, the "good score" of color matching (not the excellent one) was recorded for all veneers of both groups during all the follow-up intervals, and this could be partly related to the fact that natural teeth are difficult to mimic in terms of shade because they are multilayered, semi-translucent, curved, fluorescent, and opalescent [30]. On the other hand, there are numerous clinical variables (material composition, translucency, and thickness; and the color of the prepared tooth, the shade, and thickness of the cement) and laboratory factors (ceramic condensation technique, temperature, number of ceramic firing cycles, and glaze cycle) that affect how all-ceramic restorations look in the patient's mouth [31], [32], [33].

Yet, **the results of color matching** in the present study were comparable with some other studies.

Gresnigt et al. (2013) [11] reported that the majority of the tested laminate veneers constructed by IPS Empress glass ceramic (16/23) had a "good score" regarding color matching. **Abou-Steit et al. (2019)** [34] pointed out that Vita Suprinity and IPS e.max CAD full coverage restorations revealed good clinical acceptance in terms of color matching. These results were in disagreement with **Bekhiet et al. (2021)** [35], who reported that IPS e.max press and Celtra press materials, when used for full coverage restorations, resulted in excellent shade matching results.

The results of color stability revealed an insignificant difference between both tested

groups, with the $\Delta E = 2.29$ for IPS e.max press veneers and $\Delta E = 2.27$ for Celtra press veneers. Which was considered to be within the clinically acceptable range [36], [37]. This could be attributed to the type of ceramic and type of resin cement used in the present study (light-cured choice 2, BISCO) and the inherent properties of materials. The color stability results in this study were comparable to those in other studies. **Marchionatti et al. (2017)** [38], reported that the median ΔE was 2.31 for IPS e.max press veneers after 24 months. **Elkomy et al. (2019)** [39] also found that the e-max CAD veneers revealed a high survival rate in terms of the stability of the color after one year.

The results of fracture evaluation showed a "0 score" as no fracture was recorded for all tested veneers in both groups during all the follow-up intervals. This could be due to the mechanical properties of both tested materials, since their flexure strengths were about the same (400 MPa for IPS e.max press and 500 MPa for Celtra press), as well as to the right case selection in terms of the thickness of the teeth in the incisal area, the type of occlusion, and the proper design of the preparation. The results of the present study on **fracture** were in agreement with **Gresnigt et al. (2013)** [11], which reported a "0 score" (no fracture) for all tested IPS Empress veneers with incisal overlap design during a three-year follow-up period. These results were also comparable with some other studies. **M. ElGendi et al. (2019)** [40] reported that no fracture occurred for tested ceramic laminate veneers fabricated from lithium disilicate (IPS e.max CAD) during a one-year follow-up period, and **Saeed et al. (2021)** [41] found that no fracture occurred for tested ceramic laminate veneers fabricated from IPS e.max press during a one-year follow-up period. Also, **El-Mesallamy et al. (2021)** [42] observed that the IPS Empress CAD, glazed Celtra Duo, and Vita Suprinity laminate veneers demonstrated superior clinical performance in terms of fracture resistance.

The results of marginal adaptation testing recorded a "0 score" (smooth margin) for all tested veneers in both groups during all the follow-up intervals. This could be attributed to the standardized steps followed by the researcher, such as finish line smoothing, confirmation of the path of insertion at the try-in step, the preservation of a peripheral

enamel layer around all margins, and the use of white wax to correct PMMA veneer defects.

This result was in agreement with **Gresnigt et al. (2013)** [43], which reported that all tested IPS Empress veneers with incisal overlap design (23 veneers) had a "0 score" (smooth margin) at the base line and 20 veneers of them still had a "0 score" (smooth margin) after three years' follow-up. And **Yuce et al. (2019)** [44], who reported that all tested IPS e.max press veneers (31 veneers) had a "0 score" during all follow-up intervals (for one year). The results were also comparable with those of **M ElGendi et al. (2019)** [40], who reported that all tested ceramic laminate veneers fabricated from lithium disilicate (IPS e.max CAD) had smooth margins during a one-year follow-up period, and **El-Banna et al. (2021)** [45] observed that the polished Celtra laminate veneers and the IPS Empress Cad laminate veneers both showed successful clinical performance in terms of marginal adaptation. as all tested veneers had a "0 score" (smooth margin) during all the one-year follow-up intervals.

Many authors [46], [47], [48] reported that the heat press technique had better results in terms of marginal adaptation, while others, **Yuce et al. (2019)** [44], and **Dolev et al. (2019)** [6] found that there was no significant difference in marginal adaptation between the heat press and CAD/CAM techniques.

Concerning patient satisfaction, there were statistically significant improvements between the baseline and subsequent follow-up periods in many of the evaluated factors, such as alignment, harmony, and overall in the IPS e.max press veneers group and size, alignment, harmony, and overall in the Celtra press veneers group. However, this was not considered clinically significant because all of the evaluated factors were rated as "very satisfied," with scores ranging from 90 to 100 percent by the patients. This result could be attributed to the selected cases in the current study because all of them had multiple spacing and the final restorations already resulted in changes in their size, shape, alignment, and others; patients were faced with new appearances at baseline, but adaptation to them was presented in subsequent follow-up intervals. This result can be applied clinically when facing such cases. Consider the gradual adaptation to the new restoration and

discuss it with patients before beginning the treatment.

When comparing the two groups, the **patient satisfaction** assessment showed statistically significant differences (but not clinically significant differences) in some of the evaluated factors. Overall results revealed that there were statistically significant differences (but no clinically significant differences) at the base line, while there was an insignificant difference between all other intervals. IPS e.max press veneers had a 95.4% satisfaction level, while Celtra press veneers had a 95.6% satisfaction level at the end of the evaluation period. These results could be attributed to the involvement of patients in shade selection, virtual DSD demonstrations, and mock-up modification according to patient aesthetic and functional needs. The results of our study were very similar to those found by other researchers [34], [40], [42], and [49].

In the present study, the results of **post-cementation sensitivity** revealed that both tested groups had a "1 score" (slight sensitivity) in 17% of the IPS e.max veneers group and 23% of the Celtra press veneers group at the baseline that disappeared after two weeks, and all tested veneers in both groups revealed a "0 score" (no sensitivity) in the remaining follow-up intervals. These results could be attributed in part to the selected design of preparation, which allows exposure of dentin in some areas, and the acid etching process, and in part to the contraction of the luting resin cement after polymerization.

These results are in agreement with **Gresnigt et al. (2013)** [43], who reported that 6 teeth receiving veneers out of 46 veneered teeth had a "1 score" (slight sensitivity) at the baseline and then a "0 score" (no sensitivity) in the remaining follow-up intervals. In addition, **Aslan et al. (2019)** [50], observed that 35 of the 413 evaluated laminate veneers displayed postoperative sensitivity following cementation, but these symptoms disappeared within 3 weeks. The results were in disagreement with **El-Banna et al. (2021)** [45] who found that both IPS Empress Cad and Polished Celtra Duo laminate veneers revealed "0 score" (no sensitivity) during all the one-year follow-up intervals.

All the tested variables for both groups revealed nearly the same results. This could be attributed to

the following factors: both materials belong to the same ceramic class (synthetic glass ceramic); both have high flexural strength; both have the same color coding of the ingots (vita classic A-D 16 tabs); proper case selection; benefits from different techniques for manufacturing ceramic veneers (3D printing, CAD/CAM, and conventional); and standardization of all laminate veneer restoration fabrication procedures using evidence-based methods.

CONCLUSIONS

Within the limitations of the present study, the following conclusion could be drawn: After one year of follow-up, both Celtra press laminate veneers and IPS e.max press laminate veneers showed successful clinical performance in anterior teeth requiring conservative labial laminate veneers with incisal wrap design in terms of color matching and color stability, fracture, sensitivity, and patient satisfaction.

REFERENCES

1. A. Alenezi, M. Alsweed, S. Alsidrani, and B. R. Chrcanovic, "Long-term survival and complication rates of porcelain laminate veneers in clinical studies: A systematic review," *J. Clin. Med.*, vol. 10, no. 5, pp. 1–14, 2021, doi: 10.3390/jcm10051074.
2. L. Porojan, R. D. Vasiliu, M. I. Birdeanu, and S. D. Porojan, "Surface characterization and optical properties of reinforced dental glass-ceramics related to artificial aging," *Molecules*, vol. 25, no. 15, 2020, doi: 10.3390/molecules25153407.
3. R. L. Sakaguchi and J. M. Powers, *Craig's Restorative Dental Materials Thirteenth Edition*. 2012.
4. A. S. Alayad, "Ceramic Fracture in Bilayered All-ceramic Indirect Restoration: A Review of the Literature," *J. Adv. Oral Res.*, vol. 10, no. 1, pp. 5–12, 2019, doi: 10.1177/2320206819831560.
5. A. G. Türk, M. Sabuncu, S. Ünal, B. Önal, and M. Ulusoy, "Comparison of the marginal adaptation of direct and indirect composite inlay restorations with optical coherence tomography," *J. Appl. Oral Sci.*, vol. 24, no. 4, pp. 383–390, 2016, doi: 10.1590/1678-775720160012.
6. E. Dolev, Y. Bitterman, and A. Meirowitz, "Comparison of marginal fit between CAD-CAM and hot-press lithium disilicate crowns," *J. Prosthet. Dent.*, vol. 121, no. 1, pp. 124–128, 2019, doi: 10.1016/j.prosdent.2018.03.035.
7. C. Van Den Breemer, M. Gresnigt, M. Özcan, W. Kerdijk, and M. Cune, "Prospective randomized

- clinical trial on the survival of lithium disilicate posterior partial crowns bonded using immediate or delayed dentin sealing: Short-term results on tooth sensitivity and patient satisfaction,” *Oper. Dent.*, vol. 44, no. 5, pp. E212–E222, 2019, doi: 10.2341/18-047-C.
8. A. Qanungo, M. A. Aras, V. Chitre, A. Mysore, B. Amin, and S. R. Daswani, “Immediate dentin sealing for indirect bonded restorations,” *J. Prosthodont. Res.*, vol. 60, no. 4, pp. 240–249, 2016, doi: 10.1016/j.jpor.2016.04.001.
 9. R. L. Balkaran, T. Osoba, and R. Rafeek, “A cross-sectional study of patients’ satisfaction with dental care facilities: A survey of adult treatment at the University of the West Indies, School of Dentistry,” *West Indian Med. J.*, vol. 63, no. 5, pp. 490–498, 2014, doi: 10.7727/wimj.2013.197.
 10. M. A. Aldosari, M. A. Tavares, A. T. G. Matta-Machado, and M. H. N. G. Abreu, “Factors associated with patients’ satisfaction in Brazilian dental primary health care,” *PLoS One*, vol. 12, no. 11, pp. 1–13, 2017, doi: 10.1371/journal.pone.0187993.
 11. M. M. Gresnigt, W. Kalk, and M. Ozcan, “Randomized clinical trial of indirect resin composite and ceramic veneers: up to 3-year follow-up,” *J. Adhes. Dent.*, vol. 15, no. 2, pp. 181–90, 2013, doi: 10.3290/j.jad.a28883.
 12. P. S. Fleming, C. D. Lynch, and N. Pandis, “Randomized controlled trials in dentistry: Common pitfalls and how to avoid them,” *J. Dent.*, vol. 42, no. 8, pp. 908–914, 2014, doi: 10.1016/j.jdent.2014.06.004.
 13. H. Zhu, S. Zhang, and C. Ahn, “Sample size considerations for split-mouth design,” *Stat. Methods Med. Res.*, vol. 26, no. 6, pp. 2543–2551, 2017, doi: 10.1177/0962280215601137.
 14. C. Igiel, M. Weyhrauch, S. Wentaschek, H. Scheller, and K. M. Lehmann, “Dental color matching: A comparison between visual and instrumental methods,” *Dent. Mater. J.*, vol. 35, no. 1, pp. 63–69, 2016, doi: 10.4012/dmj.2015-006.
 15. Z. Jafri, N. Ahmad, M. Sawai, N. Sultan, and A. Bhardwaj, “Digital Smile Design-An innovative tool in aesthetic dentistry,” *J. Oral Biol. Craniofacial Res.*, vol. 10, no. 2, pp. 194–198, 2020, doi: 10.1016/j.jobcr.2020.04.010.
 16. M. Hoorizad, S. Valizadeh, H. Heshmat, S. F. Tabatabaei, and T. Shakeri, “Influence of resin cement on color stability of ceramic veneers: in vitro study,” *Biomater. Investig. Dent.*, vol. 8, no. 1, pp. 11–17, 2021, doi: 10.1080/26415275.2020.1855077.
 17. N. Anwar, “Factors In uencing Patients’ Satisfaction with Anterior Teeth Restorations in Ha’il City, Kingdom of Saudi Arabia,” pp. 394–400, 2018.
 18. D. M. Barnes, L. W. Blank, J. C. Gingell, and M. A. Latta, “Clinical Evaluation of Castable Ceramic Veneers,” *J. Esthet. Restor. Dent.*, vol. 4, pp. 21–26, 1992, doi: 10.1111/j.1708-8240.1992.tb00713.x.
 19. P. W. Kihn and D. M. Barnes, “The clinical longevity of porcelain veneers: A 48-month clinical evaluation,” *J. Am. Dent. Assoc.*, vol. 129, no. 6, pp. 747–752, 1998, doi: 10.14219/jada.archive.1998.0317.
 20. M. Peumans, B. Van Meerbeek, P. Lambrechts, and G. Vanherle, “The 5-year clinical performance of direct composite additions to correct tooth form and position. I. Esthetic qualities,” *Clin. Oral Investig.*, vol. 1, no. 1, pp. 12–18, 1997, doi: 10.1007/s007840050003.
 21. B. Korkut and C. Türkmen, “Longevity of direct diastema closure and recontouring restorations with resin composites in maxillary anterior teeth: A 4-year clinical evaluation,” *J. Esthet. Restor. Dent.*, vol. 33, no. 4, pp. 590–604, 2021, doi: 10.1111/jerd.12697.
 22. N. Mf, N. Z. Nr, S. B. A. Sba, M. S. Mn, I. Mf, and Y. Ma, “A Comparison of Tooth Shade Selection between use of Visual Approach, Digital Cameras and Smartphone Cameras,” *J. Int. Dent. Med. Res.*, vol. 14, no. 1, pp. 99–104, 2021.
 23. E. Palla, E. Kontonasaki, and N. Kantiranis, “Color stability of lithium disilicate ceramics after aging and immersion in common beverages,” *J. Prosthet. Dent.*, pp. 1–11, doi: 10.1016/j.prosdent.2017.04.031.
 24. J. F. Pissaia, B. K. de Almeida Guanaes, C. C. de Almeida Kintopp, G. M. Correr, L. F. da Cunha, and C. C. Gonzaga, “Color stability of ceramic veneers as a function of resin cement curing mode and shade: 3-year follow-up,” *PLoS One*, vol. 14, no. 7, pp. 1–9, 2019, doi: 10.1371/journal.pone.0219183.
 25. B. P. Gugelmin, L. C. M. Miguel, F. B. Filho, L. F. da Cunha, G. M. Correr, and C. C. Gonzaga, “Colorstability of ceramic veneers luted with resin cements and pre-heated composites: 12 months follow-up,” *Braz. Dent. J.*, vol. 31, no. 1, pp. 69–77, 2020, doi: 10.1590/0103-6440202002842.
 26. M. Hayashi, N. H. F. Wilson, S. Ebisu, and D. C. Watts, “Influence of explorer tip diameter in identifying restoration margin discrepancies,” *J. Dent.*, vol. 33, no. 8, pp. 669–674, 2005, doi: 10.1016/j.jdent.2005.01.006.
 27. A. F. Boeckler, A. Stadler, and J. M. Setz, “The significance of marginal gap and overextension

- measurement in the evaluation of the fit of complete crowns," *J. Contemp. Dent. Pract.*, vol. 6, no. 4, pp. 26–37, 2005, doi: 10.5005/jcdp-6-4-26.
28. F. Alzegaibi, A. Jammah, F. Alghanim, K. Albawardi, and L. Alkadi, "The relationship between patient's participation in shade selection and their satisfaction with their dental prostheses," *Clin. Exp. Dent. Res.*, vol. 8, no. 1, pp. 270–274, 2022, doi: 10.1002/cre2.508.
29. C. R. G. Van Den Breemer, M. M. M. Gresnigt, and M. S. Cune, "Cementation of Glass-Ceramic Posterior Restorations: A Systematic Review," *Biomed Res. Int.*, vol. 2015, 2015, doi: 10.1155/2015/148954.
30. J. F. Fondriest, "The Optical Characteristics of Natural Teeth," *Insid. Esthet.*, vol. 8, no. 11, pp. 2–5, 2012, [Online]. Available: www.dentalaegis.com/id.
31. A. Czigola, E. Abram, Z. I. Kovacs, K. Marton, P. Hermann, and J. Borbely, "Effects of substrate, ceramic thickness, translucency, and cement shade on the color of CAD/CAM lithium-disilicate crowns," *J. Esthet. Restor. Dent.*, vol. 31, no. 5, pp. 457–464, 2019, doi: 10.1111/jerd.12470.
32. F. Nejatidanesh, K. Azadbakht, O. Savabi, M. Sharifi, and M. Shirani, "Effect of repeated firing on the translucency of CAD-CAM monolithic glass-ceramics," *J. Prosthet. Dent.*, vol. 123, no. 3, pp. 530.e1-530.e6, 2020, doi: 10.1016/j.prosdent.2019.10.028.
33. M. Mohamed and M. Gomaa, "Effect of surface finishing protocols on color and translucency of zirconia reinforced lithium silicate glass-ceramic after thermo-mechanical aging and different staining solutions," *Egypt. Dent. J.*, vol. 66, no. 4, pp. 2491–2502, 2020, doi: 10.21608/edj.2020.34025.1162.
34. S. Abou-Steit, J. ElGuindy, and A. Zaki, "Evaluation of patient satisfaction and shade matching of vita suprinity versus lithium disilicate (E-max) ceramic crowns in the esthetic zone: A randomized controlled clinical trial [version 1; peer review: Awaiting peer review]," *F1000Research*, vol. 8, pp. 1–14, 2019, doi: 10.12688/F1000RESEARCH.18337.1.
35. M. Bekhiet, maha taymour, and M. zamzam, "CLINICAL EVALUATION AND PATIENT SATISFACTION OF SHADE MATCHING BETWEEN NATURAL TEETH AND MONOLITHIC ALL-CERAMIC CROWNS FABRICATED FROM TWO MATERIALS (Randomized Controlled Clinical Trial)," *Egypt. Dent. J.*, vol. 67, no. 3, pp. 2231–2238, 2021, doi: 10.21608/edj.2021.62512.1495.
36. R. D. Paravina *et al.*, "Color difference thresholds in dentistry," *J. Esthet. Restor. Dent.*, vol. 27, no. S1, pp. S1–S9, 2015, doi: 10.1111/jerd.12149.
37. R. D. Paravina, M. M. Pérez, and R. Ghinea, "Acceptability and perceptibility thresholds in dentistry: A comprehensive review of clinical and research applications," *J. Esthet. Restor. Dent.*, vol. 31, no. 2, pp. 103–112, 2019, doi: 10.1111/jerd.12465.
38. A. M. E. Marchionatti, V. F. Wandscher, M. M. May, M. A. Bottino, and L. G. May, "Color stability of ceramic laminate veneers cemented with light-polymerizing and dual-polymerizing luting agent: A split-mouth randomized clinical trial," *J. Prosthet. Dent.*, vol. 118, no. 5, pp. 604–610, 2017, doi: 10.1016/j.prosdent.2016.11.013.
39. M. Elkomy, J. El-guindy, and M. Taymour, "Color stability of emax CAD laminate Veneers cemented with light cure versus dual cure amine free adhesive resin cement (Randomized Controlled Clinical Trial)," *Egypt. Dent. J.*, vol. 65, no. 2, pp. 1469–1475, 2019, doi: 10.21608/edj.2019.72571.
40. M. M ElGendi, K. Rabie, and A. A Zaki, "One-year clinical evaluation of e.max CAD and LavaTM ultimate laminate veneers with butt joint preparation (Randomized controlled clinical trial)," *Med. Res. Innov.*, vol. 3, no. 2, pp. 1–6, 2019, doi: 10.15761/mri.1000160.
41. Z. Saeed, A. L. Sayed, M. Al, O. S. El, and D. El Mahallawi, "Clinical Evaluation of Fracture and Color Changes of All Ceramic Laminate Veneers Prepared With Modified Gull Wing versus Conventional Technique (Randomized Controlled Clinical Trial)," vol. 25, no. 6, pp. 16230–16249, 2021.
42. O. M. W. El-Mesallamy, H. I. M. El-Banna, M. L. Zamzam, J. F. El-Guindy, and A. S. Idris, "Patient satisfaction and clinical evaluation of IPS empress CAD versus ZLS ceramic laminate veneers: A randomized controlled clinical trial," *World J. Dent.*, vol. 12, no. 3, pp. 183–188, 2021, doi: 10.5005/jp-journals-10015-1813.
43. M. M. Gresnigt, W. Kalk, and M. Ozcan, "Randomized clinical trial of indirect resin composite and ceramic veneers: up to 3-year follow-up," *J. Adhes. Dent.*, vol. 15, no. 2, pp. 181–90, 2013, doi: 10.3290/j.jad.a28883.
44. M. Yuce, M. Ulusoy, and A. G. Turk, "Comparison of Marginal and Internal Adaptation of Heat-Pressed and CAD/CAM Porcelain Laminate Veneers and a 2-Year Follow-Up," *J. Prosthodont.*, vol. 28, no. 5, pp. 504–510, 2019, doi: 10.1111/jopr.12669.
45. H. I. M. El-Banna, M. L. Zamzam, J. F. El-Guindy, and A. S. Idris, "One-year clinical

- evaluation of IPS empres CAD versus polished celtra duo ceramic laminate veneers (Randomized controlled clinical trial),” *Brazilian Dent. Sci.*, vol. 24, no. 3, 2021, doi: 10.14295/bds.2021.v24i3.2595.
46. M. N. Aboushelib, W. A. Elmahy, and M. H. Ghazy, “Internal adaptation, marginal accuracy and microleakage of a pressable versus a machinable ceramic laminate veneers,” *J. Dent.*, vol. 40, no. 8, pp. 670–677, 2012, doi: 10.1016/j.jdent.2012.04.019.
47. B. Azar, S. Eckert, J. Kunkela, T. Ingr, and R. Mounajjed, “The marginal fit of lithium disilicate crowns: Press vs. CAD/CAM,” *Braz. Oral Res.*, vol. 32, pp. 1–7, 2018, doi: 10.1590/1807-3107/2018.vol32.0001.
48. Z. N. Al-Dwairi, R. M. Alkhatatbeh, N. Z. Baba, and C. J. Goodacre, “A comparison of the marginal and internal fit of porcelain laminate veneers fabricated by pressing and CAD-CAM milling and cemented with 2 different resin cements,” *J. Prosthet. Dent.*, vol. 121, no. 3, pp. 470–476, 2019, doi: 10.1016/j.prosdent.2018.04.008.
49. I. Soares-Rusu *et al.*, “Clinical Evaluation of Lithium Disilicate Veneers Manufactured by CAD/CAM Compared with Heat-pressed Methods: Randomized Controlled Clinical Trial,” *Oper. Dent.*, vol. 46, pp. 4–14, Mar. 2021, doi: 10.2341/19-233-C.
50. Y. U. Aslan, A. Uludamar, and Y. Özkan, “Clinical performance of pressable glass-ceramic veneers after 5, 10, 15, and 20 years: A retrospective case series study,” *J. Esthet. Restor. Dent.*, vol. 31, no. 5, pp. 415–422, 2019, doi: 10.1111/jerd.12496.
51. Faisal, H. T. ., Abid, M. K. ., & Abed, A. . (2022). Study Of Some Biochemical Parameters in Dose During Pregnancy in Goats. *Journal Of Advanced Zoology*, 43(1), 01–06. <https://doi.org/10.17762/jaz.v43i1.109>
52. Gulati, H. ., & Rana, S. . (2022). Habitat Preference and Current Threats to The Sarus Cranes Grus Antigone (Aves: Gruiformes: Gruidae) In Important Bird Areas of Haryana, India: Implications for Determining Effective Conservation Actions. *Journal Of Advanced Zoology*, 43(1), 07–16. Retrieved from <http://jazindia.com/index.php/jaz/article/view/110>
53. Mokhtar, A. R. R. A. S. . (2022). Development Of Saponin Based Wettable Powder Formulation from Phaleria macrocarpa To Control Pomacea maculate. *Journal Of Advanced Zoology*, 43(1), 17–31. Retrieved from <http://jazindia.com/index.php/jaz/article/view/111>