



Doxycycline Sclerotherapy For Lymphatic Malformations Under Doppler Ultrasound Guide

Sumayah Qahtan Midhat^{1*}, Balsam S. Abdul-Hameed², Amer Murad Jebur³

^{1,2,3}Maxillofacial department, Al-Imamain Al-Kadhmain medical city, Baghdad, Iraq

Corresponding author: Dr. Sumayah Qahtan Midhat, Baghdad /Iraq , somaqahtan8@gmail.com ,

Submitted: 20 January 2023; Accepted: 19 February 2023; Published: 04 March 2023

ABSTRACT

Background: Lymphatic malformations are uncommon hamartomatous congenital malformations of lymphatic system that can manage by different percutaneous scleroting agents.

Aim of study: This prospective study is to assess the effectiveness of doxycycline in all types of lymphatic malformations in terms of dose calculation and number of sessions and to evaluate risks versus benefits.

Patients and method: one year period,(7) patients with simple Lymphatic malformations at the age (1-23) years were treated using doxycycline (10mg/ml) as percutaneous intralesional scleroting agent guided by Doppler Ultra -sound, Magnetic resonance imaging was obtained in follow ups 6 weeks postoperatively .

Results: there were (4) patients with macrocystic Lymphatic malformations (57.1%), (1) patient with microcystic Lymphatic malformations (14.3%) ,and (2) patients with combined Lymphatic malformations (28.6%) , there was complete resolution in(6) patients (85.7%) including all types of Lymphatic malformations and residual lesion of (1) patient (14.3%) of combined type. All macrocystic type required only one session and the combined type required more sessions than other types, follow up range was (2-7) months after complete resolution.

Conclusions: doxycycline is an effective, inexpensive, available scleroting agent that can achieve excellent result in all types of Lymphatic malformations with large doses even in small children with minor and manageable side effects.

Keywords: Lymphatic malformations, Sclerotherapy , Doxycycline ,Doppler ultrasound guide.

INTRODUCTION

In the past four decades, great progress had been made for the understanding of tumors and tumor like proliferations of vascular origin and in 1982, Mulliken and Glowacki had made a biological classification of vascular anomalies; into: vascular tumors and vascular malformation. [1] Then this classification was adopted by the ISSVA in1996 and 2018 .[2]

Lymphatic malformations are congenital slow flow type vascular malformations due to early errors of lymphatic morphogenesis of embryonic life .³ Different management modalities had emerged, but in the last 30 years , intralesional sclerotherapy had become a favorable approach by many due to low risk ,complications and less invasive ,if it is compared with surgery . [4]

Doxycycline is a broad spectrum antibiotic and a scleroting agents that has been shown to be effective for benign lymphoepithelial cysts and lymphoceles treatment with minimal side effect, for this reason, doxycycline, as a scleroting ,agent should be evaluated . [5]

PATIENT AND METHOD

The patients: (7) patients ,(4) females (3) males, age (1-23) years..

The study criteria: Inclusion criteria: LMs confirmed diagnosis by (imaging ,preoperative histopathological examination (FNA), all age groups .

Exclusion criteria: combined vascular malformation.

Methods: All guardians signed the written consent for treatment plan.

Imaging study: initially to ensure a simple slow flow type malformation then MRI, for confirmation and classification.

Fine needle aspiration: for confirmation (all the patients preoperatively).

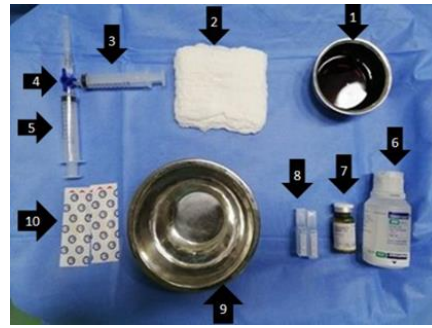Operative procedure: patients either were endotracheal intubated orally or were sedated (medazolam 0.02 mg/kg and fentanyl 1micro-gram/kg). Antibiotic, analgesic, corticosteroids were given intra -operatively.

1) Preparation of the patient and equipments :

A) Supine position, lateral position was needed for only one patient due to posterior position of the LM in the neck. B) Sterile prep and draping were carried out in the same conventional manner. C) Surgical trolley was prepared as shown in figure (1). 4) Portable Doppler US machine with straight transduce , were cleaned and disinfected in a conventional manner and placed at the right side of the patients.

2) Preparation of the sclerotic agent injection :

scleroting injection is the product of (100 mg) doxycycline vial mixed with 3 ml of (iohexol/omnipaque 350 mg) as contrast medium to outline the cysts s wall and septa). and 7ml distal water ,figure (1),the volume of injection was calculated in a 1:1 ratio of the aspirated lymphatic fluid and the dose of doxycycline injected per session ranged from 100mg to 1000mg and was determined by the capacity of the LMs, with the maximum dose of 1000mg or 20mg/kg.



Figure(1) surgical trolley :1-(povidone iodine) ,2- gauze,3- 10 ml syringe (aspiration) ,4-three way stopcock cannula ,5- 10 ml syringe for doxycycline injection ,6-iohexol 350 mg contrast medium ,7-doxycycline vial 100mg ,8-distal water ,9-container for the aspirated fluid ,10- strip bandage plaster.

3) The interventional procedure:

The radiologist started to identify each cyst which appeared anechoic figure(2)- a, c or hyper echoic if it is hemorrhagic or contain debris by using a straight transducer as a guide. 2) Once the radiologist identified the largest cyst, a three way stopcock cannula figure (1) was inserted by using 21 gauge needle head into the intended cyst while the US screen guided the depth of penetration. Figure(3)-a . 3) Then the 1st 10 ml syringe was used to aspirate the lymphatic fluid and recorded its volume .figure (3)-b. 4) Then the 2nd 10 ml syringe was used to inject the scleroting mixture, hyper echoic appearance on the screen started to increase in size inside the cyst walls until it became fill and distended, figure(3)-b,d. 5) The same procedure was repeated for all the cysts in the LM . 6) For microcystic type, a little or no lymphatic fluid could be obtained, so it required only a small volume and dose of doxycycline to appear hyper echoic and distended on the screen. 7) Finally, all the recorded dosages and volumes were added together to reach the total injection dose per volume of that session and was recorded on the case sheet. 8) The area of injection was disinfected and strip bandage plaster was applied.

Doxycycline Sclerotherapy For Lymphatic Malformations Under Doppler Ultrasound Guide

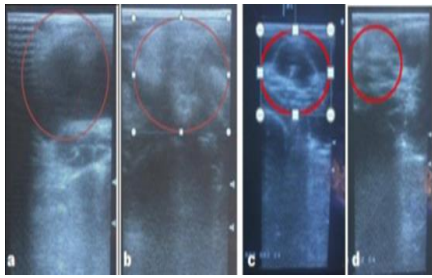
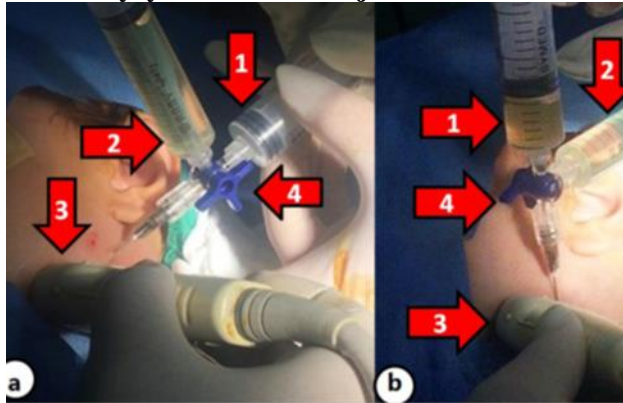


Figure (2) (a) big, and (c) smaller, anechoic cystic LM,(b)and (d) they became hyper echoic after doxycycline mixture injection .



figure(3),(a)the insertion of three way stopcock cannula under the Doppler US guide,(b)the aspiration of lymphatic fluid and injection of doxycycline, 1- aspirated lymphatic fluid , 2- syringe doxycycline mixture) ,3- straight transducer for guidance 4- three way stopcock cannula.

4) Postoperative Care:

A) Meperidine (pethidine) ampoule 50mg (0.5-2mg/kg) was used once immediately after recovery. B) Ceftriaxone vial (50mg/kg/d q12h). C) Acetaminophen (15mg/Kg/d q6h) .D) dexamethasone ampoule (0.02-0.03 mg /kg/ d q12h) only for the 1st day. H) oxygen saturation ,edema evaluation, neurological signs monitoring .J) Patients stayed in the hospital for 1 day

(overnight) except for two patients who discharged at the same day of operation .

5) postoperative follow up :

A. schedule one week follow up postoperatively: clinical examination of lesion size, edema , healing of the injection sites, and exclude any signs or symptoms of infection.

B. schedule 6th week follow up postoperatively: I) clinically: Healing of percutaneous injection sites evaluation by inspection and Palpation then documentation by photographs.

II) imaging: color Doppler , MRI . If there was a complete resolution, we scheduled a new 6 weeks follow up appointment and repeat the imaging (US, MRI). If there was a residual or recurrent malformation, a new operation scheduled as soon as possible.

C. post resolution follows up: clinically and imaging (US or MRI or both).

RESULTS

Descriptive statistical analysis of the type:

There were (4) patients with macrocystic LMs (57.1%), (1) patient with microcystic LMs (14.3%) ,and (2) patients with combined LMs (28.6%) .

Descriptive statistical analysis of the number of sessions:

The total no. of sessions was (14) the mean no. of sessions is (2.0) for all the patients , (range 1-5),(SD=1.5) :one session for(4) patients, two sessions for(1) patient, three sessions for(1) patient and five sessions for (1) patient .

3)Dose assessment:

Dose evaluation was calculated for each patient depending on: 1. Amount of aspirated lymphatic fluid (macrocytic) or the weight of the patient. 2. The distension of the lesion on US monitor post injection. Table (1).

Table 1. total doses of all the patients

PATIENTS	WT/KG	LMs SIZE (MRI)	NO.S	Doxycycline solution dose
NO.1	101	In.s. 11*10mm & 10*6mm f.u.s 7*4 mm and 2*1 mm	2	1 st s. (100mg)/10ml 2 nd s. (300 mg) /30ml
NO.2	20	21*18 mm	1	(330 mg)/33ml
NO.3	14.5	50*20 mm & 20*15	1	450mg/45ml
NO.4	13	70*26 mm	1	400mg/40ml
NO.5	12	54*14 mm	1	550mg/55ml

NO.6	63	In.s.55* 12 mm 1 st f.u.s. 34*13mm & 22*22mm 2 nd f.u.s 12*7mm & 23*8 mm 3 rd f.u.s. 24*6mm 4 th f.us. 5*5,5*3,4*3 mm	5	1 st s. 100mg/10ml 2 nd s. 230mg/23 ml 3 rd s. 200mg/20 ml 4 th s. 100 mg /10ml 5 th s. 75 mg /7.5 ml
NO.7	15	In.s. 63*28 mm 1 st f.us.65*40 mm 2 nd f.u.s. 25*9 mm 3 rd f.u.s. 16*10 mm & 12*10 mm	3	1 st s. 75mg/7.5ml 2 nd s. 340mg/34ml 3 rd s. 210 mg/21ml

(NO.=number), (WT=weight),(MRI=magnetic resonance imaging),(in.S.=initial size),(f.u.s.=follow up size) , (S.=session)

4)Descriptive statistical analysis of LMS response to doxycycline sclerotherapy:

Excellent response of (6) patients ,They manifest complete resolution of their LMs (85.7%) , only one patient (14.3%) manifest residual LMs but(six times smaller than original size) , see figures(4,5,6,) complete resolution was achieved in all three types .

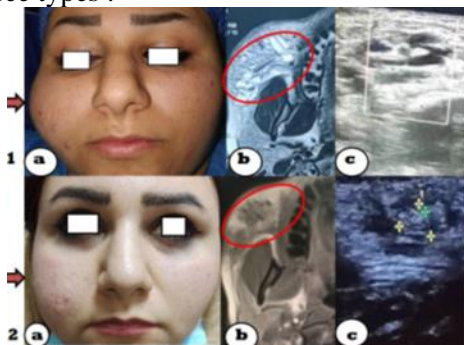


Figure (4) patient no. 1 in table (2),1(a-b-C) preoperative clinical , MRI & US images showed multiple microcystic spaces. 2(a-B-C) final postoperative clinical , MRI &US of granulation tissue.

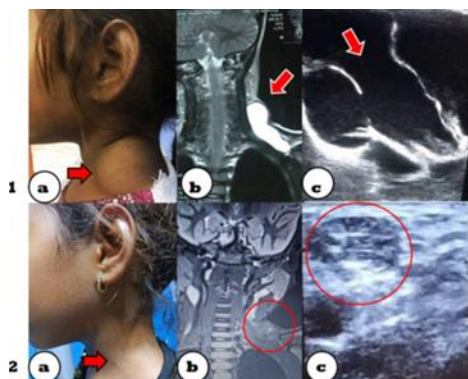


Figure (5) patient no.5 in table(2),1(a-b-c)preoperative clinical , MRI & US showed macrocystic spaces posterior to the carotid sheath , 2(a-b-c) final postoperative clinical , MRI & US showed picture of complete resolution .

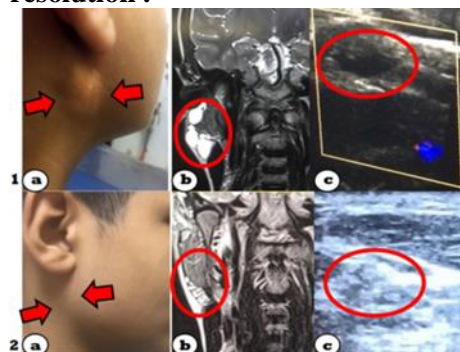

figure (6)patient no.6 in table (2), 1(a-b-c) clinical ,MRI& US image of combined LMs superficial to lower part of right parotid gland ,2(a-b-c) final postoperative clinical ,MRI& US showed area of complete resolution.

5)Descriptive statistical analysis of postoperative complications:

All the patients suffered from temporary severe pain and postoperative edema after every session (100%) ,infection and eschar of cutaneous puncture sites were only in one patient (14.3%) . All information of this study is summarized in Table (2).

Doxycycline Sclerotherapy For Lymphatic Malformations Under Doppler Ultrasound Guide

Table 2. all patients characteristics of the study and their results, complications and post resolution follow up

7 patients	Gender	Age (yrs)	Site (LMs)	TYPES (LMs)	Intial Size (MRI)	NO.S. &Dose of doxycycline solution	Final size	complications	Post resolution follow up
NO.1	f	23	RT. cheek	Microcystic	11*10 mm & 10*6mm +other multiple smaller cysts	Two sessions 1st s. 100mg/10ml 2nd s. 300 mg /30ml	Complete resolution	Post edema & pain op.	7 months
NO.2	f	7	Thoracic inlet LT. Para midline	Macrocystic	21*18 mm	One s. 330mg/33ml	Complete resolution	Post edema& pain op.	3months
NO.3	m	1	Neck LT. PT.	Macrocystic	50*20 mm & 20*15 mm	One s. 450mg/45ml	Complete resolution	Post edema& pain op.	2months
NO.4	m	1	Neck LT. PT.	Macrocystic	70 *26 mm	One s. 400mg/40ml	Complete resolution	Post edema& pain op.	2months
NO.5	f	6	Neck LT. PT.	Macrocystic	54*14 mm	One s. 550mg/55ml	Complete resolution	Post edema& pain op.	3months
NO.6	m	13	Neck RT. AT. & PT.	Combined	Largest 55*12mm +multiple small cysts < 1 cm	five sessions 1st s. 100mg/10ml 2nd s. 230mg/23 ml 3rd s. 200mg/20 ml 4th s. 100 mg/10ml 5th s. 75mg/7.5ml	Complete resolution	Post edema& pain op.	2months
NO.7	f	3	Neck RT. AT. & PT.	Combined	Largest 63*28mm +multiple small cysts < 1 cm	Three sessions 1st s. 75mg/7.5ml 2nd s. 340mg/34ml 3rd s. 210mg/21ml	Residual two cysts 16*10 mm 12*10 (covid 19 patient) s.were terminated	Post edema, Pain, infection & scar op.

(NO.=number),(yrs=years), (LMs= lymphatic malformations) , (RT= right), (LI.=left), (s.=session), (PT=posterior triangle), (AT= anterior triangle), (MRI=magnetic resonance imaging).

DISCUSSION

1) The type of LMs of the patients:

There were (4) patients with macrocystic LMs (57.1%), (1) patient with microcystic LMs (14.3%) ,and (2) patients with combined LMs (28.6%)

,which goes with Jeremy D Prager et al 2019 and Jason L Acevedo et al 2019 about the predominance of the microcystic type above the mylohyoid muscle and the macrocystic type below the mylohyoid muscle . [6, 7]

2) Doxycycline dose assessment of the patients:

Burrows et al. 2008 used a study dose of 10mg/ml doxycycline injected per session ranged from 100 mg to 1000 mg and was determined by the capacity of the LM, with a maximum dose of 1000 mg or 20 mg/kg and the doxycycline solution was prepared by mixing 100 mg doxycycline powder with 5 ml distilled water and 5 ml Contrast medium (100mg/10 ml).[8] ,Rashi et al. 2019 used the same previous doses with a ratio of 1:1 of (aspirated lymphatic fluid :doxycycline solution).[9] ,in this study a similar protocol was used in dose calculations, and 100 mg to 1000 mg was the main range guide for dose per session since 20mg/kg was not always amenable in children with small weight and big macrocystic or combined LMs. Only one small difference in this study from these previous studies concerning the preparation of doxycycline solution; the contrast medium was 3ml instead of the previous 5ml, because it was observed that this smaller volume provided the same effect of outlining the walls and septa of the LMs .In this study dose evaluation was calculated for each patient depending on the amount of aspirated lymphatic fluid (macrocystic and macrocystic part of combined type) or the weight of the patient if 20mg/kg dose rule was used, furthermore the distension of the lesion on US monitor (capacity) post injection was a vital indicator because it seemed to result into a faster and better outcome , in fact sometimes bigger volume of doxycycline(bigger than the aspirated lymphatic fluid) could be injected to make the LMs fully distended on US monitor which was possible due to inter communication of the cysts septa within the LMs (without exceeding the maximum dose of 1000 mg) .

3) Number of sessions of the patients:

The total no. of sessions were (14) sessions for (7) patients , with a mean of 2 sessions for each patient ,(SD=1.5), (range 1- 5)which coincided with shaye et al. 2020 in which (10) patients underwent total (21) sclerotherapy sessions with a mean of 2.1 sessions per patient ,(SD=1.3), (range 1–5). [10] ,Shergill et al.2012 had a total (146)sessions for(50) child , a mean of (2.9) sessions . [11] ,which is

higher than this sample. In this study the number of sessions in 3 patients increased probably due to the following variables :i. only in the first session of patients no. 1,6,7(table (2)), the volume of injection was half of the aspirated lymphatic fluid following the study of Arvind Shergill et al.2012 . [11,12], then on 2019 a new study of Rashi et al. ,that suggested that better result had been obtained when the injection volume was equal to the aspirated lymphatic fluid .[9], by doing this, each cyst became distended with the scleroting agent , for that in this study a ratio of 1:1 of (aspirated lymphatic fluid :doxycycline solution) was maintained in macrocystic type and macrocystic part of combined type for the rest of all sessions of all patients in this study . ii. the type of the LMs had a great effect upon the number of sessions ,in this sample all macrocystic types required only one session to reach complete resolution in spite of their bigger sizes as compared with other types ,which coincided with Shiels et al. 2009 who reported (93%) of macrocyst patients required 1 treatment session. [13], Ju Yeon Lee et al.2019 study in which (8) of (15) macrocystic LMs achieved complete resolution in average of (1.5) session. [14], which is higher in no. of sessions than this sample, on other hand the combined type in this sample seemed to require multiple sessions to achieve complete resolution which coincide with shaye et al. 2020 who reported (5) sessions for patient with combined type to reach complete resolution . [10] , in this sample only one patient for microcystic type , required 2 sessions which coincided with Shiels et al. 2009 study in which the range number of sessions for microcysts was (1 - 4) .[13]

4)Follow up of the patients:

Rashi et al.2019 suggested 3 weeks follow up postoperatively.[9], Thomas et al. 2016 suggested 4-6 weeks follow up postoperatively.[8] , Joseph Reis 2020 , Shergill et al.2012 suggested 6 weeks follow up postoperatively.[15,11],burrows et al 2008, suggested 6-8 weeks follow up postoperatively.[8] , in this study , two follow ups periods were obtained, the first(only clinical) was one week postoperatively and the second was 6 weeks postoperatively . Covid 19 pandemic severely affect the result in terms of the real time needed to collect a bigger sample and in term of follow up attendance (both in between sessions and post resolution follow up) , in patient

no.5(table (2)) her 6 weeks follow up was postponed she couldn't attend until 2 months postoperatively , MRI showed residual(5*4) mm lesion at the previous injection site with nearby granulation tissue ,2nd operation was not feasible , 4 months and half later ,the patient attended a visit and new MRI obtained showing a complete resolution, that might suggest longer follow ups and less number of sessions .In this study the mean of post resolution follow up period was (2-7) months which coincide with 6 months of Thomas et al 2016 to ensure complete resolution and to exclude recurrence.[16]. Burrows et al. 2008 reported no recurrence over a longer post resolution follow up period (at least 1 year).[8], Rashi et al. 2019 follow up was until complete remission only .[9]

5)Response to doxycycline sclerotherapy of the: Excellent response of (6) patients, They manifest complete resolution of their LMs (85.7%) ,figure(4,5,6), only (1) patient manifest residual but smaller lesions (14.3%).In this study the macrocystic type(4 patients) had an excellent response of 100% complete resolution which coincide with Thomas et al. 2016, Ju Yeon Lee et al.2019, Rashi et al. 2019, Kavitha Ranganathan and Steven J. Kasten(2020) , all suggested that macrocystic LMs have an excellent response to doxycycline .[9 ,17] ; improvement for combined LMs.[16,14], However in this study, the (2) patients with combined type ,(1) showed complete resolution after 5 sessions (which coincide with shaye et al.(2020). [10] , and the other combined type patient in this study got infected with the covid 19 virus , the treatment was terminated for this particular patient, although a complete resolution was highly expected because the residual lesion was 6 times less than the initial size ,so in this study not only improvement for the combined type(as mentioned in previous studies) , but probably a complete resolution could be expected requiring more sessions to reach the same result of macrocystic type . One patient for microcystic type in this sample, she had a complete resolution after 2 sessions which was not coincide with Burrows et al. 2008 ,Shergill et al.2012 who mentioned that the microcystic type had the lowest response to doxycycline sclerotherapy. [8, 11] ; probably because of our small sample, but Burrows stated that doxycycline seems to be more effective in treating microcystic type than OK-432.8 , Shiels

et al 2009 reported complete resolution (100%) of (179) cyst in(17) patients of microcystic type treated with doxycycline sclerotherapy.[18,13], Ju Yeon Lee et al.2019 suggested that microcystic lymphangiomas may respond very well to doxycycline. [14], which supported the result of this study .Regarding agents, doxycycline had the highest cure rate (62.4%) compared with all other agents, that was the result study of De Maria, L et al. 2020 in a meta-analysis from 2000 to 2018 for evaluating the safety and efficacy of percutaneous sclerotherapy of head, face, and neck .[19]

6) Postoperative complications of patients:

In this study all the patients suffered from temporary severe pain and post injection edema after every session (100%), all reports of the literature including Burrows 2008et al. ,shergill et al.2012 ,De Maria, L et al. (2020) mentioned the most common two post injection complications of doxycycline ,which were (edema and pain) .[8, 11, 20] , in this study , edema was moderate , temporary and resolved within few days ; the pain even it was sever but it only lasted 3-4 hrs. postoperatively , Shergill et al.2012 suggested the use of morphine .[11] , in this study postoperative pain was managed with meperidine ampoule 50mg (0.5-2mg/kg) immediately after recovery which provided an instant relieve of pain in addition to Acetaminophen (15mg/Kg/d q6h) was used in intravenous vial form intraoperatively and postoperatively . Rashi et al.2019 mentioned infection in(13%) and fever(39%)as a problem in varying proportion of cases throughout the follow up period .[9],that coincide with infection ratio in this study which was (14.3%) ; encountered in one patient two months postoperatively ,probably because she was from a poor socioeconomic community so good nutrition and hygiene was spectacle ,then she was treated immediately by intravenous wide spectrum antibiotic (ceftriaxone vial (50mg/kg/d q12h) for 10 days , fever was never encountered in this study . Ju Yeon Lee et al.2019 encountered a skin necrosis only in (1) of (21) patients and considered as a rare complication , the necrosis was recovered by wound management .[14] ,Thomas et al. reported superficial skin ulceration and then eschar in (1) of (32) patients .[8],in this sample no skin necrosis was encountered ,only a small eschar(14.3%) corresponding to previous injection site , It is worth mentioning that the eschar was developed in

same patient who underwent infection so the scar might probably a sequel of infection . No major complication was encountered (horner syndrome) in this study and no dental stain was reported ,both Shergill et al.2012, and Burrows et al.2008 encountered a horner syndrome in (1) patient of (50) and of (41) respectively after injection into the cervical lymphangioma which was gradually improved.[18] ,and both declared that no dental stain was encountered in their follow up period .[8,11], 4 years follow up in Shergill study.[7], No methemoglobinemia in this study ,Katherine Coughlin et al.2019 encountered a methemoglobinemia in 1 week old infant born with cervical lymphangioma after sclerotherapy with doxycycline who developed low oxygen saturations being found on pulse oximetry and elevated methemoglobin level.[21]

CONCLUSIONS

i. complete resolution can be achieved for all types of LMs even the microcystic type which was commonly known to be resistant to sclerotherapy, the difference was in the rapidity of response; the macrocystic type was the fastest to respond and the combined type was the slowest in response. ii. In nonextensive LMs, 1:1 ratio of (aspirated lymphatic fluid: doxycycline solution) or slightly more volume of doxycycline can be injected until the cavity on US be filled that would result in better response (than 1:1/2 ratio) without exceeding the maximum dose of 1000 mg. iii. Doxycycline sclerotherapy was effective, both complications and side effects were minor and manageable, and large doses could be given with trivial risk of toxicity. iv. MRI and US were vital imaging modalities in both diagnosis and follow ups stages of this study. V. Doppler US was crucial modality for interventional guidance to ensure full injection of all part of LMs and prevent systemic escape of sclerotizing agent and prevent injury to adjacent anatomic structures. vi. General anesthesia was necessary, and couldn't be avoidable especially in children due to sever post-operative pain.

Acknowledgment: of technical help for DR.YAARUB I. KHATTAB consultant pathologist,the team of anesthesiologists : DR. SUMAYA ALWAN SALMAN, DR . MOHAMMED HADI JEBUR, DR. AHMED

IBRAHIM, DR. THAMIR ARUBEI consultant Otorhinolaryngology surgeon , DR .SALAH SALMAN MAHMOOD consultant pediatric surgeon ,Special thanks to PROFESSOR SAWSAN SATI ABBAS ,Consultant Pediatric Hemato Oncologist. Dr. Sumayah Qahtan Midhat B.D.S, C.A.B.M.S. (OMFS). , Dr. Balsam S. Abdul-Hameed B.D.S, F.I.C.M.S., H. D. L., Dr. Amer Murad Jebur M.B.CH.B., C.A.B.M.S. (RAD).

REFERENCES

1. Clough, J. G. (2006). Classification of vascular anomalies. *Journal of Foot and Ankle Surgery*, 45(6), 443–444. <https://doi.org/10.1053/j.jfas.2006.11.001> .
2. Dasgupta, R., & Fishman, S. J. (2014). ISSVA classification.Seminars in Pediatric Surgery, 23(4), 158–161.<https://doi.org/10.1053/j.sempedsurg.2014.06.016> .
3. Ramashankar, Prabhakar, C., Kumar, N., & Giraddi, G. (2014). Lymphatic malformations: A dilemma in diagnosis and management. *Contemporary Clinical Dentistry*, 5, 119–122. <https://doi.org/10.4103/0976-237X.128689> .
4. Gilony D, Schwartz M, Shpitzer T, Feinmesser R, Kornreich L,Raveh E,(2012), Treatment of lymphatic malformations: a more conservative approach. *J Pediatr Surg*. 2012 Oct; 47(10):1837-42.doi: 10.1016/j.jpedsurg.2012.06.005. PMID: 23084194 .
5. Cordes, B. M., Seidel, F. G., Sulek, M., Giannoni, C. M., & Friedman, E. M. (2007). Doxycycline sclerotherapy as the primary treatment for head and neck lymphatic malformations.*Otolaryngology - Head and Neck Surgery*, 137(6), 962–964. <https://doi.org/10.1016/j.otohns.2007.08.013> ISBN: 978-0-323-41496-8.
6. Jeremy D Prager, MD, (2019), *Skin Tumors, Vascular Lesions, Face and Neck* , emedicine.medscape.com, updated :may22 ,2019 .
7. Jason L Acevedo, MD, (2019), *Lymphatic Malformation (Cystic Hygroma)*, emedicine.medscape . com, updated :Jan 28 ,2019 .
8. Burrows, P. E., Mitri, R. K., Alomari, A., Padua, H. M., Lord,D. J., Sylvia, M. B., Fishman, S. J., & Mulliken, J. B. (2008).Percutaneous sclerotherapy of lymphatic malformations with doxycycline. *Lymphatic Research and Biology*, 6(3–4), 209–216. <https://doi.org/10.1089/lrb.2008.1004> .
9. R., Basu, K. S., Ganguly, S. S., Saha, K., & Ahmad, S.(2019). Outcome and clinical efficacy of bleomycin and doxycycline percutaneous

- sclerotherapy for treatment of paediatric lymphatic malformations in a limited resource setting. *International Journal of Contemporary Pediatrics*, 6(4), 1652. <https://doi.org/10.18203/2349-3291.ijcp20192771> .
10. Shaye, D. A., Burks, C. A., Gadkaree, S. K., Ncogoza, I., Tuyishimire, G., Nyabyenda, V., & Gassore, A. (2020). Selfcompounded Doxycycline Sclerotherapy for the Treatment of Lymphatic Malformations in Low-Resource Settings. *World Journal of Surgery*, 432 . <https://doi.org/10.1007/s00268-020-05667-z> .
 11. Shergill, A., John, P., & Amaral, J. G. (2012). Doxycycline sclerotherapy in children with lymphatic malformations: Outcomes, complications and clinical efficacy. *Pediatric Radiology*, 42(9),1080–1088. <https://doi.org/10.1007/s00247-012-2406-2> .
 12. Jamal N, Ahmed S, Millter T. Bent J, Brook A, Parikh S, Ankola A (2012): Coxycycline sclerotherapy for pediatric head and neck macrocystic lymphatic malformations: a case series and reivew of the literature. *Int. J Pediatri Otorhinolaryngol*. 2012 Aug;76(8):1127-31 .
 13. Shiels, W. E., Kang, D. R., Murakami, J. W., Hogan, M. J., & Wiet, G. J. (2009). Percutaneous treatment of lymphatic malformations. *Otolaryngology - Head and Neck Surgery*, 141(2), 219–224. <https://doi.org/10.1016/j.otohns.2009.04.001> .
 14. Lee, J. Y., Namgoong, J.-M., Kim, S. C., & Kim, D. Y. (2019). Early Experience of Doxycycline Sclerotherapy for Lymphatic Malformations. *Advances in Pediatric Surgery*, 25(2), 44. <https://doi.org/10.13029/aps.2019.25.2.44> .
 15. Greene, A. K., Perlyn, C. A., & Alomari, A. I. (2011). Management of lymphatic malformations. *Clinics in Plastic Surgery*, 38(1), 75–82. <https://doi.org/10.1016/j.cps.2010.08.006> .
Successful Medical Treatment for Head and Neck Lymphatic Malformations. *Case Reports in Otolaryngology*, 2019, 1–3. <https://doi.org/10.1155/2019/2076798> .
 16. Thomas, D. M., Wieck, M. M., Grant, C. N., Dossa, A., Nowicki, D., Stanley, P., Zeinati, C., Howell, L. K., & Anselmo, D. M. (2016). Doxycycline Sclerotherapy Is Superior in the Treatment of Pediatric Lymphatic Malformations. *Journal of Vascular and Interventional Radiology*, 27(12), 1846–1856. <https://doi.org/10.1016/j.jvir.2016.08.012> .
 17. Kavitha Ranganathan and Steven J. Kasten,(2020) , vascularanomalies, .Grabb and Smith Plastic Surgery, 8th Ed .(Vol.3),ch.27 (2020). Health Kluwer, [2020]Identifiers: LCCN2019015649 | ISBN 9781496388247 .
 18. Susanne Wiegand, MD, Behfar Eivazi, MD, Annette P.Zimmermann, MD,Andreas M. Sesterhenn, MD, PhD, JochenA. Werner, MD, PhD,(2010), sclerotherapy of lymphangiomas of the head and neck, Accepted 4 June 2010Published online 24August 2010 in Wiley Online Library (wileyonlinelibrary.com). DOI:10.1002/hed.21552 .
 19. De Maria, L., De Sanctis, P., Balakrishnan, K., Tollefson, M.,& Brinjikji, W. (2020). Sclerotherapy for lymphatic malformations of head and neck: Systematic review and meta-analysis. *Journalof Vascular Surgery: Venous and Lymphatic Disorders*, 8(1), 154–164. <https://doi.org/10.1016/j.jvsv.2019.09.007> .
 20. De Maria, L., De Sanctis, P., Tollefson, M., Mardini, S.,Garrity, J. A., Morris, P. P., Bendel, E., & Brinjikji, W. (2020). Sclerotherapy for low-flow vascular malformations of the orbitaland periorcular regions: Systematic review and meta-analysis. *Survey of Ophthalmology*, 65(1), 41–47 . <https://doi.org/10.1016/j.survophthal.2019.08.003> .
 21. Coughlin, K., Flibotte, J., Cahill, A. M., Osterhoudt, K.,Hedrick, H., & Vrecenak, J. (2019). Methemoglobinemia in aninfant after sclerotherapy with high-dose doxycycline. *Pediatrics*,143(2). <https://doi.org/10.1542/peds.2018-1642> .
 22. Biswas, S. ., Bhagyasree, V. ., & Rathod, V. N. . (2022). A CHECKLIST OF BIRDS AND DIVERSITY OF AVIAN FAUNA IN MUDASARLOVA RESERVOIR OF VISAKHAPATNAM, INDIA . *Journal Of Advanced Zoology*, 42(02), 165–175. <https://doi.org/10.17762/jaz.v42i02.51>
 23. Faisal, H. T. ., Abid, M. K. ., & Abed, A. . (2022). Study Of Some Biochemical Parameters in Dose During Pregnancy in Goats. *Journal Of Advanced Zoology*, 43(1), 01–06. <https://doi.org/10.17762/jaz.v43i1.109>
 24. Wankhade, L. N. . (2022). STUDY ON BUTTERFLY FAUNA OF KARANJA (GHADGE) TAHSIL OF DISTRICT WARDHA (MAHARASHTRA). *Journal Of Advanced Zoology*, 42(02), 186–193. <https://doi.org/10.17762/jaz.v42i02.53>