



Hepato-protective effects of Montelukast against methotrexate-induced hepatotoxicity in rat model

Bayader Abdulhadi Abdul Kadhim¹, Fadhaa Abdulameer Ghafil², Sahar A. Majeed³, Heider Qassam⁴, Najah R. Hadi^{5*}

¹Al-Najaf health directorate, Najaf, Iraq

^{2,3} Department of pharmacology and therapeutics, Faculty of medicine, University of Kufa, Najaf, Iraq

⁴Department of pharmacology and therapeutics, Faculty of medicine, Kufa university, Iraq

⁵Department of Pharmacology & Therapeutics, Faculty of Medicine, University of Kufa, Kufa, Iraq

*Corresponding author: Najah R. Hadi, Department of Pharmacology & Therapeutics, Faculty of Medicine, University of Kufa, Kufa, Iraq, E-mail: drnajahhadi@yahoo.com

Submitted: 14 November 2022; Accepted: 13 December 2022; Published: 15 January 2023

ABSTRACT

Aim: Assessment of the possible Hepato-protective effects of Montelukast against hepatotoxicity induced by MTX in rat model.

Materials and methods: A 24 Albino Wister rats were included in this study, they were randomly divided into 4 groups each of 6. Group 1: control group (administered 0.9% N/S 1ml/kg/d ip) for 5 days. Group 2: MTX group (received MTX in a dose of 20mg/kg/day ip) as a single dose at day 1 and observed till day 5 of the experiment. Group 3: Montelukast group (received MTX in a dose of 20mg/kg/d ip as a single dose then Montelukast 10 mg /kg/ d ip for 5days). Group 4: vehicle group received 1ml/kg ip for each rat (10%DMSO + 40%PEG300 + 5% Tween400 + 45% Normalsalin) vehicle solution for 5 days. At day 5 all animals were sacrificed, serum was aspirated for the assessment of ALT, AST, ALP, TSB levels by colorimetric assay. Liver was removed and divided into 2 parts for histopathological examination and for assessment of tissue TNF-alpha, caspase-3, MDA, total antioxidant capacity, and TLR4 levels by ELISA method.

Results: Mean serum levels of ALT, AST, ALP and TSB as well as tissue MDA, TNF α , TILR4, Caspse3 were significantly increased in MTX group compared with the control and vehicle groups together with significant reduction in total antioxidant capacity and obvious histological damage. Whereas meanwhile treatment of rats with Montelukast together with MTX resulted in significant reduction in mean serum levels of ALT, AST, ALP and TSB as well as tissue MDA, TNF α , TILR4, Caspse3 together with significant increment in total antioxidant capacity and near normal restoration of hepatic tissue architecture.

Conclusion: Montelukast has Hepatoprotective effect against MTX induced hepatotoxicity by its antioxidant, anti-inflammatory, and anti- apoptotic properties.

Keywords: *Methotrexate (MTX), Montelukast, Hepatotoxicity, rat*

INTRODUCTION

Methotrexate is the first-line therapy for the treatment of variable malignant diseases and connective tissue disorders such as psoriasis, juvenile idiopathic arthritis, rheumatoid arthritis (RA), vacuities, multiple sclerosis, and systemic lupus erythematosus, as well as in virally induced arthritis. Methotrexate, a folic acid antagonist binds a specific carrier molecules on the cell, when enters the cell it changes into the methotrexate-polyglutamate molecule, which inhibits the enzyme dihydrofolate reductase, that turns dihydrofolate into tetrahydrofolate (the active form of folic acid) [1]. Tetra-hydrofolate deficiency will prevent the synthesis of nuclear proteins like DNA and RNA [2]. Glucarpidase detoxifies extracellular MTX and eliminates it, preventing its buildup. The hepatotoxicity of MTX, a significant and well-known adverse reaction that complicates its therapeutic use, frequently makes it difficult to utilize the drug [3]. MTX causes hepatotoxicity through a number of pathways, including inflammation, oxidative stress, and apoptosis. Induced by Methotrexate Hepatotoxicity by way of its cellular impact [4] Methotrexate is transported out of the cell through the ATP-binding cassette (ABC) family of transporters as a polyglutamate that inhibits the DHFR enzyme after entering the cell connected to the folate transporter. The production of pyrimidine and purine is decreased by methotrexate of methionine from homocysteine as an indirect effects. Oxidative stress, lipid peroxidation and reactive oxygen radicals all are implicated in hepatic toxicity together with homocysteine overload, hepatic tissue infiltration with fat, and release of proinflammatory cytokines with consequent liver fibrosis [5]. Inflammation is also implicated in the mechanism of Methotrexate induced hepatotoxicity, pro-inflammatory signaling pathways and cytokines produced by MTX-PG include tumor necrosis factor, nuclear factor kappa B, and IL-1 and IL-12[9] as well as increase the level of IL6 [6]. Apoptosis also has been involved in the mechanism of Methotrexate induced hepatotoxicity, Caspase-3 is activated by both intrinsic and extrinsic pathways. Both paths cause the intracellular enzymes such as proteases and endonucleases, which are involved of cell disintegration, to become active. The extrinsic pathway necessitates activation of a death

receptor, such as the Fas receptor, which causes the creation of a signaling complex that causes death with FADD and procaspase-8 or -10 [7]. Montelukast is a selective and orally active leukotriene receptor antagonist that inhibits the cysteinyl leukotriene CysLT 1 receptor. Montelukast is successfully counteracts the cytotoxic and inflammatory effects of cysteinyl leukotrienes (CysLTs). It has antiinflammatory and antioxidant characteristics with a variety of secondary anti-inflammatory effects. Cysteinyl leukotrienes (CysLTs) mostly produced by mast cells, eosinophil, and basophils. Liver, airways, and other organs have CysLT receptors. Many disease conditions such as experimental colitis, burn and sepsis-induced multiorgan damage, and renal ischemia reperfusion injury have all been found to be improved by CysLT1 antagonists [8]. Montelukast works by preventing neutrophil infiltration, maintaining a good level of antioxidants, and reducing the production of inflammatory mediator [9]. In the treatment of intestinal ischemia-reperfusion injury, Montelukast reportedly protects against heart harm and has an antioxidant effect [10]. Montelukast binds and blocks the cysteinyl leukotriene receptor for leukotrienes D4 and E4 with great affinity. Leukotriene Involved in the inflammatory process that may result in the signs and symptoms of asthma and allergic rhinitis [11-12]. It has been demonstrated that Montelukast increases antioxidant mechanisms, decreases lipid peroxidation, and oxidative stress indicators. Montelukast has been shown to increase antioxidant mechanisms, decrease lipid peroxidation, and diminish oxidative stress markers. Administration of Montelukast may decrease the liver damage caused by MTX due to its anti-inflammatory and antioxidant properties [13-14] Montelukast reduces the liver damage caused by MTX and decreases the damage to hepatocytes caused by LTD4 production. Montelukast significantly reduces liver damage, according to new studies, by lowering JNK 1 and NFB levels, p65 expression, and blocking pro-inflammatory cytokines (TNF- and IL-6) TLR4 contributes negatively to a variety of hepatic insults brought on by various causes. Pro-inflammatory cytokine cascades are triggered by TLR activation, and they play a role in the pathogenesis and clinical outcome of severe liver damage.

Innate immune cells and liver parenchymal cells express and activate TLRs, which are sensors of microbial and endogenous danger signals. TLR4 signaling pathway plays an important role in the progression of liver inflammation and fibrosis, by triggering the expression of pro-inflammatory cytokines through activation of I κ B kinase (IKK), which activates the transcription factor (NF- κ B) which is normally kept inactive in the cytosol complexes with the inhibitory protein I κ B α [15-20]. In this study we will investigate the potential Hepatoprotective effects of Montelukast against MTX induced hepatotoxicity since it have a favorable pleotropic properties and we will investigate its possible ameliorating effect on TLR4 expression since there is no previous study investigated the effect of MNK on hepatic tissue TLR4.

MATERIALS AND METHODS

Animals

A total of 24 adult Wister Albino rats with age of 7-8 weeks, weighting 150-250 g were obtained from Animal house at the Kufa University. The study protocol was approved by the central bioethical Committee of Kufa University. Animals were settled in the animal house of university of Kufa in a temperature-controlled (22 + -2 C) with alternating 12hr light: 12hr dark cycles, animals had free access to water and chow diet until the start of the experiments.

Design of study

After two weeks of acclimatization, the rats were randomized into 4 groups (n = 6) as following Control group 1: Rats received 0.9% sodium-chloride (1ml/kg/day, via IP route) for 5 days. MTX treated group 2: Rats received MTX (20mg/kg/day, via IP route) for 5 days

Mont-treated group 3: Rats received MTX (20ml/kg/day, via IP route) + Montelukast (received Montelukast sol (10 mg/kg/day, ip) for 5 days

Vehicle group 4: 1ml/kg from the stock suspension was administrated ip for each rat (10% DMSO + 40% PEG300 + 5% Tween400 + 45% Normalsalin) for 5 days [22-23]. At day 5 blood samples were obtained for assessment of Serum ALT, AST, ALP, TSB levels by colorimetric assay. Tissue MDA level, Tissue

TNF α level, Tissue Caspas3 level, Tissue TLR4 level, and tissue TAC level all were calculated by ELISA method together with histopathological examination of liver tissue sections.

Procedures

Blood Sample preparation

At day 5 Ketamine 100mg/kg and xylazine 10mg/kg were given IP according to the weight of rats [24-25]. Following this, blood samples were drawn directly from the left ventricle of the heart via a cardiac puncture. Blood samples were then placed in tubes containing clot activator gel and allowed to coagulate at 37C before being centrifuged at 3000 rpm for 10 minutes to extract the serum [21]. The subsequent serum collected is used to determine the levels of total serum bilirubin (TSB), alkaline phosphatase (ALP), aspartate aminotransferase (AST), and alanine aminotransferase (ALT).

Hepatic Tissue Preparation For Elisa Measuring Of Tlr4, Tnfa, Mda, Caspse3, And Tac Activities

Liver was rinsed with sodium chloride solution 0.9% to remove the clots and then placed in a deep freezer at -80 degrees Celsius. Following that, a liver segment was removed and homogenized using a high-intensity ultrasonic liquid processor in phosphate buffered saline that is 1:10 W/V and contains 1% Triton X-100 and 1% protease inhibitor cocktail. According to the manufacturer of the Elisa kits, the homogenates were centrifuged at 3000 rpm for 20 minutes at 4 centigrade, and the supernatant was used to determine the levels of measuring of TLR4, Caspase3, MDA, TAO and TNF- α (Bioassay Technology Laboratory) [22-23]

Preparation of Hepatic tissue samples for histopathology

Liver tissue were kept in 10% formalin and fixed. Then the samples were immersed in ethanol for two hours for each concentration (70, 80, 90, and 100%). The samples were then cleaned using xylene (an organic solvent) and prepared for examination. The samples were then cleaned using xylene (an organic solvent) which was used to remove the alcohol from the samples so that they could soak in paraffin wax (an embedding agent).

Histological sections from all groups were analyzed, and the histopathology test was performed in X100 to semi-quantify the difference in liver damage [24-25].

Score of the percentage of tissue damage as follows:

- Score 0: No damage, normal architecture
- Score 1 (mild): Less than 25% damage
- Score 2 (moderate): 25-50% damage
- Score 3 (severe): 50-75% damage
- Score 4 (highly severe): 75-100% damage.

Statistical Analysis

Data were analyzed using SPSS programmer version 20. Statistical analysis of the experimental results was conducted according to graph pad prism where one way (ANOVA) were used to assess the significance of differences between groups. The data were expressed as mean ± standard errors (SE) and P value < 0.05 was considered statistically significant.

RESULTS

Effect of Methotrexate, Montelukast on Toll like Receptor (TLR4)

In this study, we observed that the amount of TLR4 in hepatic tissue was substantially higher in the Methotrexate group $p \leq 0.01$ than in the control and vehicle groups, while in MK treated group there was significant reduction in TLR4 level, figure (1).

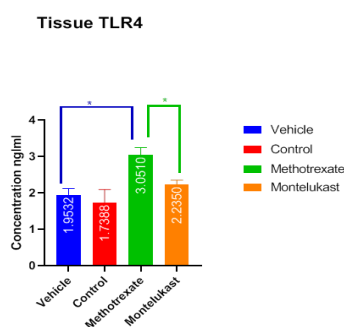


FIGURE 1: Mean tissue level of TLR4 (ng/l) of the four groups (number of rats in each group is 6)

Values of ≤ 0.05 were considered statistically significant

*Significant
** Significant

Effect of Methotrexate, Montelukast on inflammatory parameter (TNF - α)

In this study, we observed that the amount of TNF- α in hepatic tissue was significantly higher in the Methotrexate group $p \leq 0.01$ than in the control and vehicle groups whereas in Montelukast group TNF level was significantly reduced, figure (2)

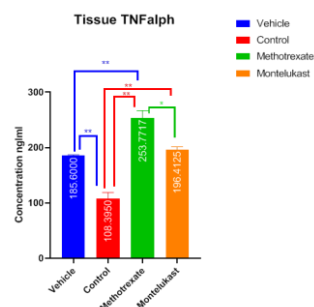


FIGURE 2: Mean tissue level of (TNF - α) (ng/l) of the four groups Values of ≤ 0.05 were considered statistically significant

*Significant
** Significant

The oxidative stress in hepatic tissue (MDA and TAC)

Effect of Methotrexate, Montelukast on oxidative stress MDA

In this study, we observed that the amount of MDA in hepatic tissue was substantially higher in the Methotrexate group $p \leq 0.01$ than in the control and vehicle groups, whereas in Montelukast group the MDA level was significantly decreased, figure (3)

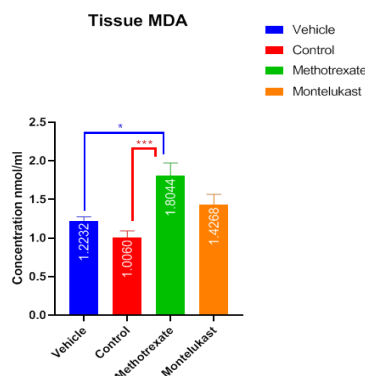


FIGURE 3: Mean tissue level of MDA (ng/l) of the four groups Values of ≤ 0.05 were considered statistically significant

*Significant
** Significant

Effect of Methotrexate, Montelukast total antioxidant capacity (TAC)

In this study, we observed that the amount of TAC in hepatic tissue was substantially lower in the Methotrexate group $p \leq 0.01$ than in the control and vehicle groups while in Montelukast group TAC level was significantly higher than in MTX intoxicated group, figure (4)

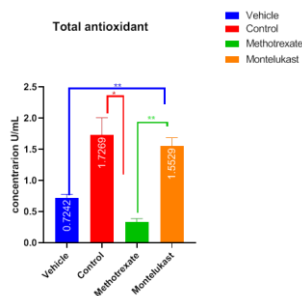


FIGURE 4: Mean tissue level of TAC (U/L) of the four Values of ≤ 0.05 were considered statistically significant

*Significant
** Significant

Effect of Methotrexate, Montelukast on the apoptotic parameter caspase-3

The amount of casp-3 in hepatic tissue was substantially higher in the Methotrexate group ($p \leq 0.01$) than in the control and vehicle groups, whereas in Montelukast group it was significantly reduced, figure (5)

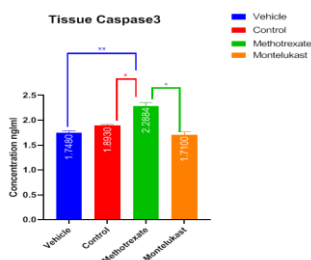


FIGURE 5: Mean tissue level of CASP-3 (ng/l) of the four groups Values of ≤ 0.05 were considered statistically significant

*Significant
** Significant

Effect of methotrexate, Montelukast on liver biochemical markers (ALT, AST, ALP, TSB)

In this study, we observed that the amount of serum (ALT, AST, ALP, TSB) levels were significantly higher in the Methotrexate group ($p \leq 0.01$) than in the control and vehicle, in Montelukast group their levels were significantly decreased, figures (6-9)

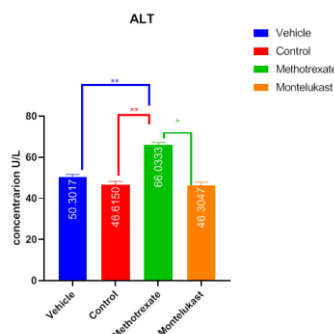


FIGURE 6: Mean serum level of ALT (U/l) of the four groups

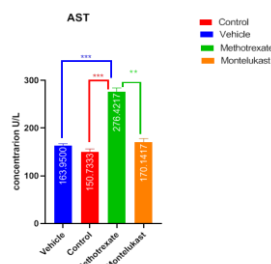


FIGURE 7: Mean serum level of AST (U/l) of the four group

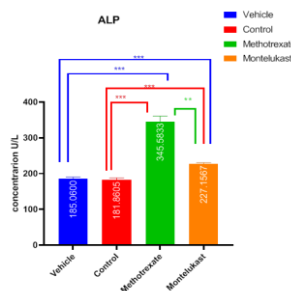


FIGURE 8: Mean serum level of ALP (U/l) of the four groups

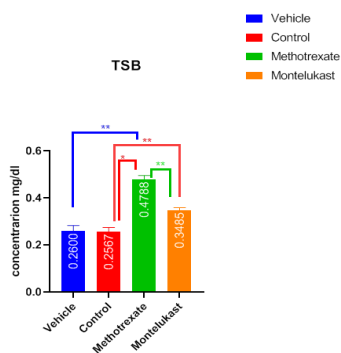


FIGURE 9: Mean serum level of (U/l) of the four groups Values of ≤ 0.05 were considered statistically significant

*Significant
**Significant

Effect of Methotrexate, Montelukast on hepatic histopathology

The histology of the hepatic tissue in control group showed normal morphological appearance according to histological results. Rat liver tissue in the Methotrexate treated group displayed significant histological abnormalities that included hepatic cellular necrosis, invasion of mononuclear cells, hepatic abnormalities including sinusoidal enlargement, mononuclear cell infiltration, and an increase in the number of kupffer cells. In the Montelukast -treated group reduced Focal mononuclear cell infiltration, sinusoid enlargement with inflammatory cell presence, together with an increase in hepatocyte mitotic activity were all observed. There was significant improvement in the histopathology to degree that preserving hepatocyte histoarchitecture in Montelukast treated groups near normal, figures (10-15).

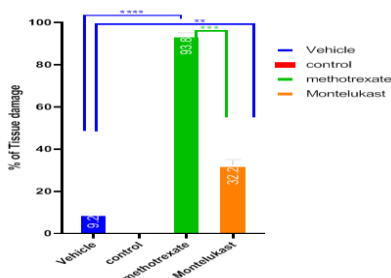


FIGURE 10: Percentage of tissue damage in each group Values of ≤ 0.05 were considered statistically significant

*Significant
**Significant

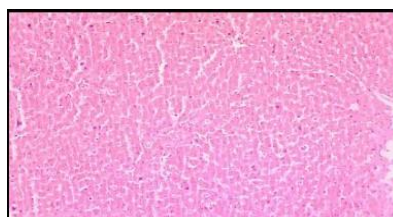


FIGURE 11: Control group the histological section in the liver of rat in control group shows normal histological texture the tissue is stained by H&E stain and captured using light microscope at 10X magnifier scale

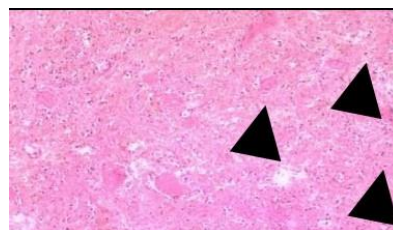


FIGURE 12: MTX group

The histopathological section in the liver shows clear damage in the hepatocytes (liquefactive necrosis, Black arrows). The tissue is stained by H&E stain and the section is captured using light microscope at 10X magnifier scale

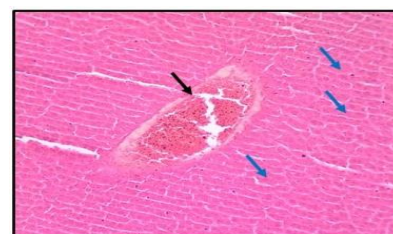


FIGURE 13: MTX group

The histopathological section in the liver shows clear blood vessels congestion (Black arrow) and hypertrophy of hepatocytes (Blue arrows)

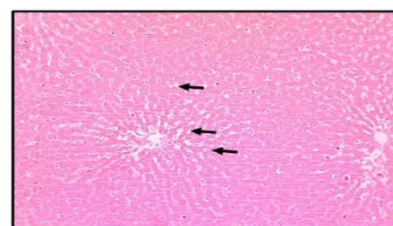


FIGURE 14: Montelukast group

The histological section in the liver shows mild fatty changes fat droplet infiltration, Black arrows with reduction in vascular congestion and inflammatory cell infiltration. The tissue is stained by H&E stain and the section is captured using light microscope at 10X magnifier scale.

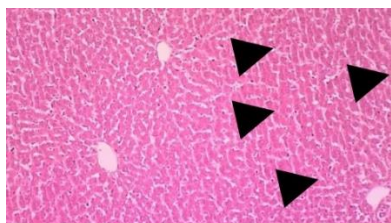


FIGURE 15: DMSO vehicle group

The histopathological section in the liver shows mild fatty changes (fat droplet infiltration, Black arrows) with inflammatory cell infiltration

DISCUSSION

Methotrexate (MTX) is a common anti-metabolite medication used in chemotherapy and disturbed immunity disorders as an immunosuppressant agent. Hepatotoxicity is a major recognizable adverse reaction of MTX that hinders its wide clinical use, it ranges from mild hepatitis and cholestasis to rapid onset liver failure and cirrhosis [26]. In order to minimize this major side effect of MTX and in order to be administered safely, adjuvant substances carrying Hepatoprotective potentials must be found. Many researches demonstrates the powerful anti-inflammatory, anti-oxidant, and anti-apoptotic properties of Montelukast in vitro and in vivo studies in addition to that the drug is available, with low cost and relatively nontoxic, all these features rendering it a good choice in managing and protecting against hepatic toxicity.

Effect of MTX, Montelukast on TLR4 level in hepatic tissue

In our investigation, TLR4 levels in liver tissue were significantly higher in the Methotrexate-treated group. MTX may cause inflammation by activating the TLR4 NF-B signaling system and increasing the production of inflammatory mediators in a variety of organs. Our findings are consistent with previous studies [32, 33], who reported that MTX induced an inflammatory response in cardiac and hepatic tissues via up-regulation of TLR4 and NF-Kappa B as well as additional activation of the Nucleotide-binding

domain receptor family (inflammasome). Montelukast is an anti-inflammatory drug widely used as a leukotriene inhibitor and proved to have anti-inflammatory properties, in our results Montelukast significantly reduced the TLR4 hepatic tissue level in MTX intoxicated rats. The evidence of Montelukast in reduction of TLR4 level recently found by a researcher [27] who stated that Montelukast reduce TLR4-NFkB, and MyD88 expression in animal model of asthma. There is no other study about the effect of MK on TLR4 expression

Effect of Methotrexate, & Montelukast on inflammatory parameter (TNFa)

Treatment of rats with MTX In our study TNF Alfa was significantly increased in MTX intoxicated rats which is evidenced by [35-37] who all showed that MTX induced hepatotoxicity is accompanied by increment in TNF-Alpha level. MK showed significant reduction in the level of TNF in hepatic tissue which was also documented by many other studies [28-29] who found that Montelukast treatment reduced TNF level in hepatic tissue during ischemia reperfusion injury and Endotoxaemia respectively [30] who found that Montelukast reduced TNF level in gut tissue by its anti-inflammatory effects.

Effect of Methotrexate & Montelukast on oxidative stress MDA and total antioxidant capacity (TAC)

While the TAC was significantly decreased in the MTX group, this is consistent with [31-32] who found that treatment of rats with MTX resulted in a significant reduction in TAC [33]. Hepatic tissue toxicity in the MTX intoxicated group showed increased MDA tissue level, which is attributed to increased oxidative stress due to the drug effect, while the TAC was significantly higher in comparison to the MTX In our study Montelukast treatment to MTX group showed increment in antioxidant characteristics associated with MK.-mediated protection against MTX-induced hepatic damage [34-35]. TAC level increased significantly in Montelukast + MTX treated group, when compared to MTX group, due to significant reduction in lipid peroxidation, suppression of ROS production and preservation of the antioxidant status of the liver tissue as indicated by reduction in MDA level and elevation of TAC level.

Effect of Methotrexate & Montelukast on apoptotic (Caspase3)

Similar findings were made by [36], who discovered that administering MTX to rats caused an increase in caspase3 level, hence accelerating the process of apoptosis. Treatment with MTX resulted in a significant rise in the incidence of the apoptotic marker caspases 3. In the same way meanwhile treatment of rats with Montelukast led in beneficent reduction in the level of caspases 3 since Montelukast has antiapoptotic properties as documented by [37] where Montelukast reduced caspases 3 in an IRI mouse model as well as decreased caspase3 level in experimental model of Parkinson disease where treatment with MK declined the expression of caspases-3 which resulted in neuronal tissue preservation.

Effect of MTX & Montelukast on liver function test

Effect of MTX on liver function test

In the present study, MTX treatment for 5 day has been shown to induce liver dysfunction, which was distinguished by a significantly increased serum level of liver enzymes ALT, AST, ALP and TSB in contrast to the monitoring collective. Since these enzymes are found in the cytosol and released into the blood after liver damage, this spike is attributed to damaged liver cells. This outcomes was in agreement with the results reported by [38-39]. The elevation in Liver enzyme since they are located in the cytoplasm and released into the bloodstream following cellular damages signaling the development of hepatotoxicity, level has been linked to the damage to the structural integrity of the liver

The Effect of Montelukast on liver function test (ALT, AST, ALP and TSB)

In the current study, Montelukast treatment for 5 day caused a significant reduction in the parameters of liver function test (ALT, AST, ALP and TSB) compared with MTX group. This result agreed with the result of the previous studies [40] who showed that treatment of rats with caused reduction in these enzyme after MTX over dose. Proof for the protective action of Montelukast the reduction of these antihepatotoxic impact would be responsible for

marker enzymes returning to close to normal values of Montelukast. It binds to receptors present on the cell membranes, inhibiting the binding of toxins in these sites, reducing drug-induced hepatocellular damage thus reduce the levels of (ALT,AST,ALP and TSB) in the liver. This outcomes was reported by [41-42] who was demonstrated that the membrane structure and integrity of the liver cells were preserved in Montelukast treated group which would otherwise have been destroyed by MTX Hepatic tissue in the control group had a normal morphological appearance according to histology. Significant histological abnormalities in the rats' livers of the MTX group included hepatocellular damage evidenced by hydropic degeneration, congestion of the central vein, dilatation of the sinusoid, inflammation, bile duct injury, and necrosis, which is consistent with [43] who discovered the same histopathological alterations that are in line with the numerous earlier studies of MTX-induced hepatotoxicity in rat models, in which the Methotrexate group displayed significant histological abnormalities, including hepatic cellular necrosis and an invasion of mononuclear cells, along with sinusoidal enlargement, mononuclear cell infiltration, and an increase in the number of kupffer cells of kupffer cells. In MK treated group, there was Reduction in the inflammatory cell infiltration, vascular

Effect of MTX and Montelukast on liver histology

Montelukast congestion, and vaculation, in addition to increased hepatocyte mitotic activity, with in central venous congestion and active kupffer cell infiltration to degree that preserving near normal hepatocyte histoarchitecture which was agreed with [43] who documented that MK has a protective level in the hepatic tissue and can reduce the extent and severity of hepatic injury induced by various pathological insults.

CONCLUSIONS

Montelukast has a Hepatoprotective effects against MTX induced hepatotoxicity via its antioxidants, antiinflammatory, and antiapoptotic properties with an ameliorating effect on the level of hepatic tissue TLR4.

REFERENCES

- Mikhaylov D, Hashim PW, Nektalova T, Goldenberg G. Systemic Psoriasis Therapies and Comorbid Disease in Patients with Psoriasis: A Review of Potential Risks and Benefits. *The Journal of clinical and aesthetic dermatology*. 2019; 12(6): 46-54.
- Tukukino C, Wallerstedt SM. Drug information centre queries and responses about drug interactions over 10 years-A descriptive analysis. *Basic & clinical pharmacology & toxicology*. 2019; 126(1): 65–74.
- Howard SC, McCormick J, Pui CH, Buddington RK, Harvey RD. Preventing and managing toxicities of high-dose methotrexate. *The oncologist*. 2016; 21(12): 1471-1482.
- van de Meeberg MM, Seinen ML, Fidder HH, Lin M, Oldenburg B, de Boer NK, et al. Subcutaneous administration, higher age and lower renal function are associated with erythrocyte methotrexate accumulation in Crohn's disease: a cross-sectional study. *BMC gastroenterology*. 2022; 22(1): 365.
- Desouza C, Parulkar A, Lumpkin D, Akers D, Fonseca VA. Acute and prolonged effects of sildenafil on brachial artery flow-mediated dilatation in type 2 diabetes. *Diabetes care*. 2002; 25(8): 1336-1339.
- Pandit A, Sachdeva T, Bafna P. Drug-induced hepatotoxicity: a review. *Journal of Applied Pharmaceutical Science*. 2012; 233-243
- Abo-Haded HM, Elkablawy MA, Al-Johani Z, Al-Ahmadi O, El-Agamy DS. Hepatoprotective effect of Sitagliptin against methotrexate induced liver toxicity. *PLoS one*. 2017; 12(3): e0174295.
- Abdel-Daim MM, Kilany OE, Khalifa HA, Ahmed AA. Allicin ameliorates doxorubicin-induced cardiotoxicity in rats via suppression of oxidative stress, inflammation and apoptosis. *Cancer chemotherapy and pharmacology*. 2017; 80: 745-753.
- Du K, Ramachandran A, McGill MR, Mansouri A, Asselah T, Farhood A, et al. Induction of mitochondrial biogenesis protects against acetaminophen hepatotoxicity. *Food and Chemical Toxicology*. 2017; 108: 339-350.
- Negre-Salvayre A, Auge N, Ayala V, Basaga H, Boada J, Brenke R, et al. Pathological aspects of lipid peroxidation. *Free radical research*. 2010; 44(10): 1125-1171
- Khodir AE, Ghoneim HA, Rahim MA, Suddek GM. Montelukast attenuates lipopolysaccharide-induced cardiac injury in rats. *Human & experimental toxicology*. 2016; 35(4): 388-397
- Lee TH, Oh JY, Hong SP, Lee JM, Roh SM, Kim SH, Park HB. ZIF-8 particle size effects on reverse osmosis performance of polyamide thin-film Nano composite membranes: Importance of particle deposition. *Journal of membrane science*. 2019; 570, 23-33.
- Kishawy HA, Hegab H, Umer U, Mohany A. Application of acoustic emissions in machining processes: analysis and critical review. *The International Journal of Advanced Manufacturing Technology*. 2018; 98: 1391-1407.
- Bäck M, Powell WS, Dahlén SE, Drazen JM, Evans JF, Serhan CN, et al. Update on leukotriene, lipoxin and oxoecosanoid receptors: IUPHAR Review 7. *British journal of pharmacology*. 2014; 171(15): 3551-3574
- Castro-Rodriguez JA, Rodriguez-Martinez CE, Ducharme FM. Daily inhaled corticosteroids or Montelukast for preschoolers with asthma or recurrent wheezing: A systematic review. *Pediatric pulmonology*. 2018; 53(12), 1670-1677.
- El-Kashef DH, Abdelrahman RS. Montelukast ameliorates Concanavalin A-induced autoimmune hepatitis in mice via inhibiting TNF- α /JNK signaling pathway. *Toxicology and Applied Pharmacology*. 2020; 393: 114931
- Kuzmich AS, Khomenko TM, Fedorov SN, Makarieva TN, Shubina LK, et al. Cytotoxic and cancer preventive activity of benzotrithioles and benzotrithioles oxides, synthetic analogues of varacins. *Medicinal Chemistry Research*. 2017; 26: 397-404.
- Lockhart E, Hawker GA, Ivers NM, O'Brien T, Mukerji G, Pariser P, et al. Engaging primary care physicians in care coordination for patients with complex medical conditions. *Canadian Family Physician*. 2019; 65(4): e155-e162.
- Emara M, ElSawy H, Bauch G. A spatiotemporal model for peak AoI in uplink IoT networks: Time versus event-triggered traffic. *IEEE internet of things journal*. 2020; 7(8): 6762-6777.
- Abdelaziz RM, Abdelazem AZ, Hashem KS, Attia YA. Protective effects of hesperidin against MTX-induced hepatotoxicity in male albino rats. *Naunyn-Schmiedeberg's Archives of Pharmacology*. 2020; 393: 1405-1417.
- Dogan G, Taskin B. Hydrolytic enzymes producing bacterial endophytes of some poaceae plants. *Polish journal of microbiology*. 2021; 70(3): 297-304.
- Kim OS, Cho YJ, Lee K, Yoon SH, Kim M, Na H, et al. Introducing EzTaxon-e: a prokaryotic 16S rRNA gene sequence database with phylotypes that represent uncultured species. *International journal of systematic and evolutionary microbiology*. 2012; 62(Pt_3): 716-721
- Emmanuel R, Karuppiyah C, Chen SM, Palanisamy S, Padmavathy S, Prakash P. Green synthesis of gold nanoparticles for trace level detection of a hazardous pollutant (nitrobenzene) causing Methemoglobinaemia. *Journal of hazardous materials*. 2014; 279, 117-124

24. Semler MW, Self WH, Wanderer JP, Ehrenfeld JM, Wang L, Byrne DW, et al. Balanced crystalloids versus saline in critically ill adults. *New England Journal of Medicine*. 2018; 378(9): 829-839.
25. Emar M, ElSawy H, Bauch G. A spatiotemporal model for peak AoI in uplink IoT networks: Time versus event-triggered traffic. *IEEE internet of things journal*. 2020; 7(8): 6762-6777.
26. Roghani M, Kalantari H, Khodayar MJ, Khorsandi L, Kalantar M, Goudarzi M, et al. Alleviation of liver dysfunction, oxidative stress and inflammation underlies the protective effect of ferulic acid in methotrexate-induced hepatotoxicity. *Drug design, development and therapy*. 2020; 1933-1941.
27. Abdelaziz RM, Abdelazem AZ, Hashem KS, Attia YA. Protective effects of hesperidin against MTX-induced hepatotoxicity in male albino rats. *Naunyn-Schmiedeberg's Archives of Pharmacology*. 2020; 393: 1405-1417.
28. Dogan G, Taskin B. Hydrolytic enzymes producing bacterial endophytes of some poaceae plants. *Polish journal of microbiology*. 2021; 70(3): 297-304.
29. Sahindokuyucu-Kocasari F, Akyol Y, Ozmen O, Erdemli-Kose SB, Garli S. Apigenin alleviates methotrexate-induced liver and kidney injury in mice. *Human & Experimental Toxicology*. 2021; 40(10): 1721-1731.
30. Jafaripour L, Naserzadeh R, Alizamani E, Mashhadi SMJ, Moghadam E, Nouryazdan N, et al. Effects of rosmarinic acid on methotrexate-induced nephrotoxicity and hepatotoxicity in Wistar rats. *Indian journal of nephrology*. 2021; 31(3): 218.
31. Oliveira PJ, Gonçalves L, Monteiro P, Providencia LA, Moreno AJ. Are the antioxidant properties of carvedilol important for the protection of cardiac mitochondria? *Current vascular pharmacology*. 2005; 3(2): 147-158.
32. Özkan E, Yardimci S, Dulundu E, Topaloğlu Ü, Şehirli Ö, Ercan F, et al. Protective potential of Montelukast against hepatic ischemia/reperfusion injury in rats. *Journal of Surgical Research*. 2010; 159(1): 588-594.
33. El-Baz AM, Shata A, Hassan HM, El-Sokkary MM, Khodir AE. The therapeutic role of Lactobacillus and Montelukast in combination with metformin in diabetes mellitus complications through modulation of gut microbiota and suppression of oxidative stress. *International Immunopharmacology*. 2021; 96: 107757
34. Jafaripour L, Naserzadeh R, Alizamani E, Mashhadi SMJ, Moghadam ER, Nouryazdan N, Ahmadvand H. Effects of rosmarinic acid on methotrexate-induced nephrotoxicity and hepatotoxicity in Wistar rats. *Indian journal of nephrology*. 2021; 31(3): 218.
35. Oliveira PJ, Seica R, Coxito PM, Rolo AP, Palmira CM, Santos MS, Moreno AJ. Enhanced permeability transition explains the reduced calcium uptake in cardiac mitochondria from streptozotocin-induced diabetic rats. *FEBS letters*. 2003; 554(3): 511-514.
36. Mohammadalipour A, Karimi J, Solgi G, Hashemnia M, Sheikh N, et al. Dasatinib prevent hepatic fibrosis induced by carbon tetrachloride (CCl4) via anti-inflammatory and antioxidant mechanism. *Immunopharmacology and immunotoxicology*. 2017; 39(1): 19-27.
37. Mazali FC, Johnson RJ, Mazzali M. Use of uric acid-lowering agents limits experimental cyclosporine nephropathy. *Nephron Experimental nephrology*. 2012; 120(1): e12-e19.
38. Torre SD, Benedusi V, Fontana R, Maggi A. Energy metabolism and fertility-a balance preserved for female health. *Nature Reviews Endocrinology*. 2014; 10(1): 13-23.
39. Althunibat OY, Abukhalil MH, Aladaileh SH, Qaralleh H, Al-Amarat W, Alfwuaires MA, et al. Formononetin Ameliorates Renal Dysfunction, Oxidative Stress, Inflammation, and Apoptosis and Upregulates Nrf2/HO-1 Signaling in a Rat Model of Gentamicin-Induced Nephrotoxicity. *Frontiers in Pharmacology*, 2022; 13.
40. Al-khawalde AAMA, Abukhalil MH, Jghef MM, Alfwuaires MA, Alaryani FS, et al. Punicalagin Protects against the Development of Methotrexate-Induced Hepatotoxicity in Mice via Activating Nrf2 Signaling and Decreasing Oxidative Stress, Inflammation, and Cell Death. *International Journal of Molecular Sciences*. 2022; 23(20): 12334.
41. Peng J, Chen F, Liu Y, Zhang F, Cao L, You Q, Yang D, Chang Z, et al. A light-driven dual-Nano transformer with deep tumor penetration for efficient chemo-immunotherapy. *Theranostics*. 2022 Jan 24; 12(4):1756-1768, doi: 10.7150/thno.68756.
42. Cheema HI, Haselow D, Dranoff JA. Review of existing evidence demonstrates that methotrexate does not cause liver fibrosis. *Journal of Investigative Medicine*. 2022; 70(7): 1452-1460.
43. Khalaf MM, Hassanein EH, Shalkami AGS, Hemeida RA, Mohamed WR. Diallyl disulfide attenuates methotrexate-induced hepatic oxidative injury, inflammation and apoptosis and enhances its anti-tumor activity. *Current Molecular Pharmacology*. 2022; 15(1): 213-226.
44. Di Martino JS, Nobre AR, Mondal C, Taha I, Farias EF, Fertig EJ, A tumor-derived type III collagen-rich ECM niche regulates tumor cell dormancy. *Nature cancer*. 2022; 3(1): 90-107.